

Index Copernicus ID 5385

ISSN No. 0972-396X



KDJ

Kerala Dental Journal

Vol 41 | No. 4
October 2018

Quarterly Publication of Indian Dental Association, Kerala State Branch

kdj.idakerala.com



SIS Index ID 833



Nanotechnology in
orthodontics

Is cbct a transcendant approach
in surgical treatment planning
of an impacted supernumerary
maxillary parapremolar?:
A case report.

Comparative evaluation
of antimicrobial efficacy of
Chitosan, sodium hypochlorite
and MTAD against Enterococcus
faecalis—an in-vitro study

Evaluation of sealing ability of
two sealers using mtad as a final
irrigant: An invitro study

Occlusal Concepts In
Implants- A Review

Critical - size defect
models in periodontal
regeneration

Sclerotherapy with polidocanol
A conservative way for treating
vascular malformation
- A Case Report

Association News

editorkdj2018@gmail.com

www.idakerala.com



EDITOR

Dr Anjana G

ASST. EDITOR

**Dr Sangeeth K Cherian
Dr Joseph Edward**

BUSINESS MANAGER

Dr V I Paul

EDITORIAL CONSULTANTS

**Dr K Nandakumar
Dr Santhosh Sreedhar
Dr K George Varghese
Dr Chandrashekhara Nair
Dr C V Pradeep
Dr P G Francis
Dr Oommen Aju Jacob
Dr Thomas Manjooran
Dr Sobha Kuriakose
Dr N O Varghese**

EX-OFFICIO MEMBERS

**Dr Ciju Paulose
Dr Suresh Kumar G
Dr Sabu Kurien
Dr Abhilash G S**

EDITORIAL BOARD

**Dr Dibyendu Mazumdar
Dr Ashok Dhoble
Dr M K Mangalam
Dr Jolly Mary Varghese
Dr Sheela Sreedhar
Dr Retnakumari
Dr E Anuradha Sunil
Dr Gilsa K Vasunni
Dr Anitha Balan
Dr Ajay Haridas
Dr V T Beena
Dr Shobhana C R
Dr Manjunath Rai
Dr Shaju Chemmanam
Dr Anupam Kumar T V
Dr Harish Kumar V V
Dr Vibha Shetty
Dr George P John
Dr Kavitha Kulkarni
Dr Jose Paul
Dr Vinod Kumar R B
Dr Radhakrishnan
Dr Civy V Pulayath**

EDITORIAL OFFICE

Amritha Multi-specialty and
Pediatric Dental Clinic
Opposite Akshaya Hospital,
Kaloor Kadavanthra Road
Kadavanthra, Kochi- 682 020
Kerala
Phone: 9447115816
e-mail: editorkdj2018@gmail.com
web: www.idakerala.com

**OFFICE BEARERS OF
IDA KERALA STATE**

PRESIDENT

Dr Ciju A Paulose

IMM. PAST PRESIDENT

Dr Sabu Kurien

PRESIDENT ELECT

Dr Abhilash G S

VICE PRESIDENTS

**Dr Sangeeth K Cherian
Dr Vinod Mathew
Dr Sreekanth Sethumadhavan**

HON. SECRETARY

Dr Suresh Kumar G

JOINT SECRETARY

Dr Binoy Stanly

ASST. SECRETARY

Dr. Krishna Kumar K S

TREASURER

Dr. Santhoshkumar P.U.

EDITOR

Dr Anjana G

CDE CHAIRMAN

Dr. Anil Thunoli

CDH CHAIRMAN

Dr Joby John Parappuram



Robotic Dentistry: How Real?

Being minimally Invasive has been the in thing for quite some especially when it comes to surgical management of diseases. More and more surgeons are choosing to perform surgery with the help of robotic tools to achieve this. The procedures may vary, but the process of robotic surgery typically involves the following. During the robotic surgery the surgeon is seated in a special consol. A small 3D camera and dime-sized surgical instruments are placed inside the patient through tiny incisions. The camera gives the surgeon a magnified 360 degree view of the operative field. Using the consoles hand and foot controls, the surgeon remotely moves robotic arms attached to surgical instruments. The second surgeon is positioned at the operating table to confirm the correct placement of the surgical instruments. The very small incisions created by robotic surgery drastically reduce patients' time in the hospital and their risk of infections. The use of high-definition 3D cameras allows surgeons close-up views of areas they aren't able to see during open surgery. Fully articulating robotic arms mimic the movement of hands, allowing surgeons to have greater dexterity and control than is possible with conventional laparoscopic instruments.

In Dentistry the first used robots were patient robots (SIMROID) mimicking patients for dental therapy training. Then robots were developed for specific treatment procedures. Micro endodontic robot can provide safe, accurate, and reliable root canal treatment for patients, preventing problems with conventional techniques like inadequate access or overzealous tooth removal. Nanorobots constructed with nanoscale (1 nm equals one millionth of 1 mm) or molecular components, can be of use in possible treatment options of local anesthesia, dentition renaturalization, cure of hypersensitivity, complete orthodontic realignment, covalently bonded diamondized enamel, and continuous oral health maintenance using mechanical dentifrobots etc. They could also be used to destroy caries causing bacteria or to repair discolorations or demineralisations, using computers to direct these tiny workers in their task. A surgical robot system for maxillofacial surgery has been developed, where the surgeon interactively programs the robot during the surgery after which the robot performs the preprogrammed tasks. Robotic technique is being used for milling of bone surfaces, drilling of holes, deep saw osteotomy cuts, selection of osteosynthesis plates, bending and intraoperative positioning in defined position, and orthognathic surgery planning. Yomi (FDA Cleared) is robotically assisted dental surgical system for implant placement. It is used to plan a procedure based on patients' CT scan. Recently, it has been reported in South China morning post that a robot dentist has installed two dental implants on a female patient.



Contents

Contents

Editorial	182
President's Message	183
Secretary's Report	184
Nanotechnology in orthodontics	185
* Feba Varghese, **Roopesh R., ***Soorya R.A.	
Is CBCT a transcendant approach in surgical treatment planning of an impacted supernumerary maxillary parapremolar?: A case report.	189
Josie Kurian Paul, Angel Mary Elias, Sujith Jones, Parvathy Jayagopal	
Comparative evaluation of antimicrobial efficacy of Chitosan, sodium hypochlorite and MTAD against Enterococcus faecalis—an in-vitro study	192
Anu George Vettithanam, Aswathy L Surendran, Rajesh Pillai, N O Varghese, Afzal A, Samyukta Nair	
Evaluation of sealing ability of two sealers using mtad as a final irrigant: An invitro study	198
Sandeep Chandran, Mahesh M, Rajesh Pillai, N O Varghese, Afzal A., Abe Antony	
Occlusal Concepts In Implants- A Review	202
Jithin GN, Amalorpavam, T Sreelal, Aparna Mohan, Giri Chandramohan, Allen Jim Hines	
Critical - size defect models in periodontal regeneration	206
Thomas George, Nebu George Thomas, Saumya John, Prameetha George Ittycheria, Neethu Mercy James	
Sclerotherapy with polidocanol A conservative way for treating vascular malformation - A Case Report	212
Sujith Johnes, Shaju George, Ranjith Kalliath, Parvathi Jayagopalan	
Association News	215



Dr. Anjana G.

Clinical Research: A career option for young Dental Graduates

Clinical Research (CR) is one scenario where India is making remarkable development and growth. Though India has been involved in CR for the past many years it is now on its way to becoming a major focus for it. This industry is already witnessing high demand for qualified professionals. There is a massive need for clinical research professionals in this fast-growing field. CR makes an interesting career option with a great scope for professional growth.

To build a career in clinical research, basic education in this field is necessary and a good hands on is the need. For the aspiring dental graduates, following are the roles you can play in Clinical Research fields: The Principal Investigator or a Co-investigator, Medical Advisor, Drug Developer, Regulatory Affairs Manager or Clinical Research Physician. There is also scope for bio-statistician who will be assigned to perform statistical programming, design, and analysis for clinical trial projects. Another career option is Clinical Research Manager who supervise design and writing of protocols, case report forms and informed consent forms for clinical trials. There are other posts too such as Clinical Research Coordinator, Business Development Manager, Clinical Research Investigator, Clinical Data Manager etc.

In the current scenario, where the young graduates face a lack of opportunity in clinical practice, CR would be something worth a change from the conventional route as CR Courses are being offered by many reputed institutes and organizations in India and the possibilities of a progressing career in CR is dynamic.

Dr Anjana G
Editor, KDJ

Message from the President

My dearest readers,

As we connect once again through these pages I feel as though I'm addressing old friends. This message in the Kerala Dental Journal Vol. 41, number 4 will be a bittersweet one for me as it is my last time writing to you as your President.

I am immensely proud of the standard presented and maintained by the KDJ and I honestly believe that it has always been a model journal in terms of creativity, content and design. In this ever changing world the KDJ has provided a means to learn about and inculcate key aspects of our profession to help us establish ourselves and thrive as an organisation embodying professional excellence. It is my sincerest wish is that KDJ will always remain the the beacon that it has been for dental professionals.

As an association, we began this year on a strong footing and it is wonderful to see that our fervour and enthusiasm has not abated one whit over the last twelve months. The space allotted for this message would not suffice to enumerate our accomplishments over the course of this year.

These accomplishments are the result of daily efforts to live out the IDA mission. Particularly in the light of recent devastation we were able to see how much of an impact our efforts could make today. We have had a real taste of what real teamwork can do. But as I reflect on these accomplishments, I wonder if these are our milestones in 2018, what will our triumphs be in the future?

I say with confidence that, yes, our efforts will go down in the annals of time. The bar has been raised my friends and the only way from here is up. And the one thing that will help us reach greater heights is our strong sense of community and brotherhood.

Before I sign off I would like to recognise the countless hours put in behind the scenes by our Hon. Secretary, Dr. Suresh Kumar G., to ensure smooth functioning of our association through all its ups and downs.

Most of all, my sincere gratitude to efforts of the Editor, Dr. Anjana G. and her team for ensuring that each issue surpassed the previous one in quality and content. Kudos to you!

Finally, I would like to urge all of you to always be our support, for your whole hearted support is what forms the backbone of our success. May the coming year bring us success beyond our wildest dreams. Wish you all the very best!

Thanking you

JAI IDA!

Dr. Ciju A Paulose
President, IDA Kerala State



Dr. Ciju A Paulose

Message from the Secretary



Dr. Suresh Kumar G

Dear IDA members

Season's greetings

As this IDA year is closing in I feel we have had a fruitful year though we still have a lot of challenges like the impending C E Bill to tackle. With your whole hearted support and belief in IDA I am sure we will be able to tackle all that with the benefit of IDA members as the prime objective. Please keep supporting all the IDA ventures as you have done in the past. Looking forward to meeting each one of you at Milan.

Thank you

Jai IDA

Dr. Suresh Kumar G.
Secretary, IDA Kerala State

Nanotechnology in orthodontics

* Feba Varghese, **Roopesh R., ***Soorya R.A.

Abstract

Nanotechnology, considered as a vital technology of the era have reformed multiple disciplines of science, technology, medicine, and space exploration. Any intentionally produced particle that has a characteristic dimension from 1 to 100 nm and has properties that are not shared

by nanoparticles with same chemical composition are termed nanoparticles. This article presents an insight into the application of nanotechnology in the field of Orthodontics with special emphasis on future developments.

Keywords: Nanotechnology, Nanoparticles, Orthodontics

KDJ 2018 | Vol. 41 | No. 4 | Pg 185-188

► Introduction

Revolutionary changes over the world in the 21st century have shown its influential results in the field of material science also. Nanotechnology is considered as a vital technology of the era based on its economic and scientific potential¹. The exclusive and exciting concept lies in the creation of materials, devices, and systems at the nanoscale level. Over the past decade, development in the field of nanotechnology have reformed multiple disciplines of science, technology, medicine, and space exploration.

The American physicist and Nobel Laureate Richard Feynman has been credited for the concept and origin of nanotechnology². This was made possible by Eric Drexler in the mid 1980s when he emphasized the potential of molecular nanotechnology^{3, 4}. The production of nanoparticles utilises three approaches, namely Bottom up approach, Top down approach and Functional approach⁵.

Nanoparticles

An engineered nanoparticle may be defined as any intentionally produced particle that has a characteristic dimension from 1 to 100 nm and has properties that are not shared by nanoparticles with same chemical composition⁶. Nanoparticles are generally classified based on their dimension, morphology, composition, uniformity, and agglomeration.

The various types of nanoparticles are Nanopores, Nanotubes, Quantum dots, Nanoshells, Dendrimers, Liposomes, Nanorods, Fullerenes, Nano spheres, Nanowires, Nanobelts, Nanorings and Nanocapsules⁷.

Nanotechnology in dentistry

Nanotechnology offers promising scope in prevention of oral diseases and providing a better dental treatment. Nanodentistry is the science and technology of conserving oral health through the use of nanomaterials including tissue engineering and nanorobotics. The budding treatment opportunities include local anesthesia, permanent hypersensitivity cure, nanorobotic dentifrice, treatment of oral cancer etc⁸. The utilisation of nanoscale dental materials and its fabrication have expanded the scope of employing biomaterials with improved properties in dentistry.

► Nanotechnology in Orthodontics

1. Nanocoatings of arch wires and brackets

Friction is a major restraint during orthodontic treatment using sliding mechanics. The acceleration of desired tooth movement is achieved by curtailing the frictional forces between the wire and brackets. The surface roughness and surface free energy of the brackets play a noteworthy role in causing friction and plaque (biofilm) formation. In current years, nanoparticles have been used as a component of dry lubricants which are

*Post Graduate Student, **Professor and Head of the Department, ***Senior Lecturer, Department of Orthodontics, PMS College of Dental Science and Research, Vattapara, Thiruvananthapuram. • Corresponding Author: Dr. Feba Varghese, E-mail: drfebavarghese@gmail.com

solid phase materials capable of reducing friction between two surfaces sliding against each other without the need for a liquid media. Biocompatible nanoparticles have been coated on stainless steel wires and brackets to reduce friction⁹. Inorganic fullerene-like nanoparticles of tungsten disulphide (WS₂) has also been evaluated in reducing friction of NiTi substrate¹⁰. Various new self-lubricating coatings¹¹⁻¹³ like Carbone Nitride (CN_x), Zinc oxide etc have been used instead of WS₂ considering its possible toxicity. Newer methods like coating the arch wires using inorganic fullerene like Molybdenum Disulfide nanoparticles and diamond like carbon coating and nitro carburizing also reduce friction^{14,15}.

A new material containing polysulfone embedded with hard alumina nanoparticles was developed in the year 2012 by UC3M for making orthodontic brackets. The material had the properties of increased strength, reduced friction and biocompatibility while maintaining the transparency of the bracket¹⁶.

2. Nanoparticles in Orthodontic adhesive

Orthodontic adhesive that contain 0.005- 0.01 microns size nano fillers are polymer nanocomposites. According to Geraldini and Perdigao¹⁷, nano-composites have a good marginal seal to enamel and dentine when compared with total-etch adhesives. The advantages of nanocomposite materials include excellent optical properties, easy handling characteristics and superior polishability¹⁸. Also, nanofillers may reduce surface roughness of orthodontic adhesives, which is one of the most major factors for bacterial adhesion¹⁹. Light cured resin-modified GIC (Ketac TM N100 Light Curing Nano ionomer) is a nanoionomer that has been introduced recently²⁰.

3. Nanoparticles in elastomeric ligature

Elastomeric ligatures aid as a carrier scaffolding for nanoparticles delivery which can be anticariogenic, antiinflammatory and antibiotic drug molecules embedded in the elastomeric matrix. The release of fluoride has been documented to be an initial burst during first few days followed by logarithmic decrease in studies²¹⁻²³.

4. Nanoparticles in antimicrobial agent

During the course of orthodontic treatment, white spot lesions and caries are commonly encountered due to plaque accumulation. This demineralization can be reduced by either coating the brackets or incorporating in cements and bonding agents nanoparticles like Nitrogen doped Titanium dioxide (TiO₂), Silver (Ag), Gold (Au), Silica (SiO₂), Copper (Cu/CuO) and ZnO nanoparticles¹. Among the commonly used concentrations of ZnO and Chitosan nanoparticle mixture added to resin composite, 10% (w/w) induces antibacterial property significantly²⁴.

5. Temporary anchorage devices (TADs)

Complete osseointegration has been a demerit complicating the removal of TAD. Hence TADs are manufactured with smooth titanium surfaces now a days. On the other hand, lack of osseointegration is also one among the various factors for the failure of TADs^{25, 26}. Thus TADs should be fabricated with an ideal surface that balances between stimulation of initial osseointegration and easy removal once the purpose is met. Biocompatible coatings like Titanium nanotubes enhance initial osseointegration and can serve as an interfacial layer between the newly formed bone and the TAD¹.

► Future of Nanotechnology in orthodontics

1. Nanorobots in orthodontics

Nanorobots are self-sufficient machines functional at the nanoscale²⁷. Different nanorobot molecule types are illustrated by a series of chemotactic sensors and their functioning is controlled by a stimulator. Research has been initiated on the use of nanorobotics for medical applications like drug delivery, management of aneurysms and tumors. The principle of use of such nanorobots could be extended to dentistry and orthodontics in distant future, where nanorobots with specific motility mechanisms would navigate through periodontium to remodel it directly allowing accelerated orthodontic tooth movement.

2. Nanoindenter

In order to evaluate nanoscale surface characteristics of biomaterials, a nanoindenter coupled with atomic force microscope (AFM) is used. It is also used to evaluate mechanical properties such as hardness, elastic modulus, yield strength, fracture toughness, scratch hardness and wear properties by nano indentation studies²⁸.

3. Bio MEMS/NEMS for orthodontic tooth movement and maxillary expansion

Biomedical Micro electromechanical systems (Bio MEMS) can be defined as the science and technology of operating at the microscale for biological and biomedical applications, which may or may not include any electronic or mechanical functions. They consist of various micromachined elements usually on silicon substrates, which also includes gears, motors and actuators with linear and rotary motion for applications to biological systems. Implantable bioMEMS have been used as biosensors for in vivo diagnosis of diseases and drug delivery microchips²⁹⁻³⁰. Devices integrating electrical and mechanical functionality on the nanoscale level are called Nanoelectromechanical systems (NEMS). When nanostructured conductive materials are used, the large surface area of these nanomaterials can increase the enzyme loading and facilitate reaction kinetics, and hence improve the power density of the biofuel cells. It is expected that the MEMS/NEMS based system can be applied over the coming few years to develop biocompatible powerful biofuel cells, which can be safely implanted in the alveolus of the

maxilla or mandible or in the palate to enhance orthodontic tooth movement or rapid maxillary expansion.

4. Shape memory polymers

Shape-memory polymers are a class of stimuli-responsive materials, which have the capacity to remember a pre-programmed shape imprinted during the synthesis; can be reformed at a higher temperature to impart a desired temporary shape; and recover their original shape when influenced by a stimulus, such as heat, light, or magnetic field^{32,33}. Applications of nanoparticles in shape-memory nanocomposite polymers can increase thermal conductivity of the polymers^{34,35}. Future research directions in shape-memory nanocomposite polymers to yield esthetic orthodontic wires is an interesting zone in orthodontic biomaterial research.

5. Nano LIPUS devices

Low-intensity pulsed ultrasound (LIPUS) has been reported to be effective in liberating preformed fibroblast growth factors from a macrophage-like cell line (U937), and it enhances angiogenesis during wound healing³⁶. Also, it has been described to enhance bone growth into titanium porous-coated implants and bone healing after fracture and after mandibular distraction osteogenesis³⁷⁻⁴⁰. The exact mechanism by which US stimulation works on bone cell activities are still unknown.

6. Smart brackets with nanomechanical sensors

Nanomechanical sensors can be assimilated into the base of orthodontic brackets in order to provide real-time feedback about the applied orthodontic forces. This allows the orthodontist to adjust the applied force so that the force applied is within the biological range to efficiently move teeth. Lapakiet al^{41,42} reported on the introduction of a 'smart' bracket for multidimensional force and moment control. They described on a large-scale prototype bracket that utilized microsystem chip encapsulated into small low profile contemporary bracket systems with reduced dimensions to allow clinical testing of this technology.

► Conclusion

In the persistently progressing arena of dental biomaterials, the applications of nanotechnology have offered the pathway for fabrication of materials with upgraded physical and mechanical properties. The potential for research in this area is vast, even though nanotechnology in dentistry especially orthodontics is in its early phase. Hence further researches and its incorporation into clinical orthodontics can very well be beneficial to orthodontists as well as patients.

► References

- Panchali B, Anam M, Jahurul m, Meryam SR, Ragini M. Nanoparticles and their Applications in Orthodontics. *Adv Dent & Oral Health*. 2016; 2(2): 555-584.
- R.P. Feynman, There is plenty of room at the bottom, *Eng. Sci.* 23 (1960) 22-36.
- Drexler KE. *Engines of creation, the coming era of nanotechnology*. Anchor press, New York, 1980.
- Drexler KE. *Molecular Engineering: An Approach to the Development of General Capabilities for Molecular Manipulation*. *Proc Natl Acad Sci* 1981; 78:5275-5278.
- Rodgers P. *Nanoelectronics*. *Nature Nanotech*, 2006.
- Freitas RA Jr: *Nanomedicine, Basic Capabilities*, Georgetown, TX: Landes Bioscience, 1999; 1:345-350.
- Horikoshi S, Serpone N. 2013 *Introduction to Nanoparticles*. *Microwaves in nanoparticle synthesis: Fundamentals and Applications*. 1-24.
- DeeptiGovindankutty. Applications of nanotechnology in orthodontics and its future implications: A review. *International Journal of Applied Dental Sciences* 2015; 1(4): 166-171.
- Redlich M, Katz A, Rapoport L, Wagner HD, Feldman Y, et al. (2008) Improved orthodontic stainless steel wires coated.
- SamorodnitskyNaveh GR, Redlich M, Rapport L, Feldman Y, Tenne R (2009) Inorganic fullerene-like tungsten disulfide nanocoating for friction reduction of Nickel-Titanium alloy. *Nanomedicine (Lond)* 4(8): 943-950.
- Wei S, Shao T, Ding P (2010) Study of CNx films on 316L stainless steel for orthodontic application. *Diamond and Related Materials* 19(5-6): 648-653.
- Kachoei M, Eskandarinejad F, Divband B, Khatamian M (2013) The effect of zinc oxide nanoparticles deposition for friction reduction on orthodontic wires. *Dent Res J* 10(4): 499-505.
- Goto M, Kasahara A, Tosa M (2008) Reduction in frictional force of ZnO coatings in a vacuum. *Jpn J Applied Phys* 47(12): 8914-8916.
- Wu H, Yang R, Song B, Han Q, Li J, Zhang Y, et al. (2011) Biocompatible inorganic fullerene-like molybdenum disulfide nanoparticles produced by pulsed laser ablation in water. *ACS nano* 5(2): 1276-1281.
- Zhang H, Guo S, Wang D, Zhou T, Wang L, et al. (2016) Effects of nanostructured, diamond like, carbon coating and nitrocarburizing on the frictional properties and biocompatibility.
- Universidad Carlos III de Madrid - Oficina de Informacion Cientifica (2012) Nanoparticles provide reinforcement for invisible braces in Orthodontics Science daily.
- Geraldeli S, Perdigao J. Microleakage of a new restorative system in posterior teeth. *Journal of Dental Research (special issue A)*: 126 (Abstract), 2003.
- Lee YK, Lim BS, Rhee SH, Yang HC, Powers JM. Changes of optical properties of dental nano-filled resin composites after curing and thermocycling. *J Biomed Mater Res* 2004; 71B:16-21.
- Quirynen M, Bollen CM. The influence of surface roughness and surface free-energy on supra- and subgingival plaque formation in man. *J Clin Periodontol*. 1995; 22:1-14.
- Killian CM, Croll TP. Nano-ionomer tooth repair in pediatric dentistry. *Pediatr. Dent* 2010; 32(7):330-535. 27.
- Wiltshire WA. determination of fluoride from fluoridereleasing elastomeric ligature ties. *Am. J Orthod Deniofacialthop*. 1996; 110(4):383-387.
- Wiltshire WA. In vitro and in vivo fluoride release from orthodontic elastomeric ligature ties. *Am. J Orthod DentofacOrthop*. 1999; 115(3):288-292.
- Miura KK. Anticariogenic effect of fluoride-releasing elastomers in orthodontic patients. *Braz. Oral. Res* 2007; 21-(3)228-233.
- Mirhashemi A, Bahador A, Kassae M, Daryakenari G, Ahmad Akhouni M, et al. (2013) Antimicrobial Effect of Nano-Zinc Oxide and Nano Chitosan Particles in Dental Composite Used in Orthodontics. *J Med*.
- Miyawaki S, Koyama I, Inoue M, Mishim K, Sugahara T, Takano-Yamamoto T et al. Factors associated with the stability of titanium screws placed in the posterior region for orthodontic anchorage. *Am J Orthod. DentofacialOrthop*. 2003; 124(4):373-378.
- Kuroda S, Sugawara Y, Deguchi T, Kyung HM, TakanoYamamoto T. Clinical use of minis-crew implants as orthodontic anchorage: success rates and postoperative discomfort. *Am J Orthod. DentofacOrthop*. 2007; 131(1):9-15.
- Cavalcanti A, Rosen L, Kretly LC, Rosenfeld M, Einav S (2004) Nanorobotic challenges in biomedical applications, design and control IEEE ICECS Int'l Conf. on Electronics, Circuits and Systems Tel-Aviv, Israel.

28. Stach EA, Freeman T, Minor AM, Owen DK, Cumings J, et al. (2001) Development of a nanoindenter for in situ transmission.
29. Nuxoll EE, Siegel RA. Bio MEMS devices for delivery. *IEEE Eng. Med. Biol. Mag* 2009; 28(1):31-39.
30. Xu B. Bio MEMS enabled drug delivery, *Nanomedicine* 2005; 1(2):176-177.
31. Gourley PL. Brief overview of BioMicroNano technologies. *Biotechnol. Prog.* 2005; 21(1):2-10.
32. S.I. Gunes, S.C. Jana, Shape memory polymers and their nanocomposites: a review of science and technology of new multifunctional materials, *J. Nanosci. Nanotechnol.* 8 (4) (2008) 16161637.
33. M.A. Stuart, W.T. Huck, J. Genzer, M. Müller, C. Ober, M. Stamm, et al., Emerging applications of stimuli-responsive polymer materials, *Nat. Mater.* 9 (2010) 101-113.
34. Q. Meng, J. Hu, A review of shape memory polymer composites and blends, *Compos. A Appl. Sci. Manuf.* 40 (11) (2009) 1661-1672.
35. J. Leng, X. Lan, Y. Liu, S. Du, et al., Shape-memory polymers and their composites: stimulus methods and applications, *Prog. Mater. Sci.* 56 (7) (2011) 1077-1135.
36. Young SR, Dyson M. The effect of therapeutic ultrasound on angiogenesis. *Ultrasound Med Biol.* 1990; 16:261-269.
37. Tanzer ME, Harvey A, Kay P, Morton, Bobyn JD. Effect of noninvasive low intensity ultrasound on bone growth into porouscoated implants. *J Bone Joint Surg.* 1996; 14:901-906.
38. Abramovich A. Effect of ultrasound on the tibia of the young rat. *J Dent Res.* 1970; 49:1182.
39. Heckman JD, JB Ryaby J, McCabe JJ, Frey Kilcoyne RF. Acceleration of tibial fracture-healing by non-invasive, low-intensity pulsed ultrasound. *J Bone Joint Surg.* 1994; 76:26-34.
40. El-Bialy TH, Royston TJ, Magin RL, Evans CA, Zaki AM, Frizzell LA. The effect of pulsed ultrasound on mandibular distraction. *Ann Biomed Eng.* 2002; 30(10):1251-1261.
41. Lapatki BG, Paul O. Smart brackets for 3D-force-moment measurement in orthodontic research and therapy- developmental status and prospects. *J OrofacOrthop.* 2007; 68(5):377-396.
42. Lapaiki HG, Bartholomeyczik J, Ruther P, Jonas IE, Paul O. Smart bracket for multi-dimensional force and moment measurement. *J Dent Res.* 2007; 86(1):73-78.

Is CBCT a transcendant approach in surgical treatment planning of an impacted supernumerary maxillary parapremolar?: A case report

*Josie Kurian Paul, **Angel Mary Elias, ***Sujith Jones, ***Parvathy Jayagopal

Abstract

A case report describing a case of impacted maxillary parapremolar which was stumbled upon during radiographic investigation of a maxillary first molar which was indicated for

RCT. Radiographic diagnosis through routine investigations like IOPA and OPG fell short in forming a precise surgical strategy due to complex three dimensional position of the tooth. In

such a scenario CBCT study proved to be paramount in surgical treatment planning.

KDJ 2018 | Vol. 41 | No. 4 | Pg 189-191

► Introduction:

Supernumerary teeth are defined as the presence of excessive number of teeth/tooth in relation to normal dental formula i.e. 20 deciduous and 32 permanent teeth. Their reported prevalence ranges between 0.3–0.8% in the primary dentition and 0.1–3.8% in the permanent dentition^{1,3}. Males are affected approximately twice as often as females. Supernumerary teeth can occur as singles, multiples, unilaterally or bilaterally and in the maxilla, the mandible or both¹.

Supernumerary teeth may erupt normally, remain impacted, appear inverted or assume an abnormal path of eruption⁴. However, only 13–34% of all permanent supernumerary teeth are erupted, compared with 73% of primary supernumerary teeth¹. The most frequent location for supernumerary teeth are the midline of maxilla, palatal area of upper incisors, lower premolar area and distal of upper and lower third molar⁵. Supernumerary teeth are estimated to occur in the maxilla 8.2 to 10 times more frequently than the mandible,^{2,3,6} and most commonly affect the premaxilla¹.

Supernumeraries can be classified according to morphology or location.

Based on Morphology: Conical

They have conical or triangular-shaped crowns and complete root formation. Mostly found as isolated single cases and are usually located between the maxillary central incisors (mesiodens)^{7,8}.

Tuberculate

They have a barrel-shaped appearance and a crown consisting of multiple tubercles⁷. Tuberculate types have either incomplete or absent root formation⁷. They are usually found in a palatal position relative to the maxillary incisors^{1,7}. Tuberculate supernumeraries are often bilateral. It has been suggested that tuberculate supernumeraries may represent a third dentition⁷.

Supplemental

Supplemental supernumerary teeth resemble their respective

*Senior Lecturer, Dept of Oral and Maxillofacial Surgery, **Senior Lecturer, Dept of Prosthodontics; ***Senior Lecturer, Dept of Oral and Maxillofacial Surgery, Royal Dental College, Challissery • Corresponding Author: Dr. Josie Kurian Paul, E-mail: drjosiekp@outlook.com

normal teeth. The most common supplemental tooth is the permanent maxillary lateral incisor, although supplemental premolars and molars also occur¹.

Odontomes

There are two different types of odontome: compound and complex. Compound odontomes comprise many separate, small tooth-like structures. A complex is a single, irregular mass of dental tissue that has no morphological resemblance to a tooth.

Based on Location

Mesiodens

Typically, a mesiodens is a conical supernumerary tooth located between and palatally the maxillary central incisors^{1,8,9}.

Paramolar

A paramolar is a supernumerary molar, usually rudimentary, situated buccally or lingually/palatally to one of the molars or in the interproximal space buccal to the second and third molar.

Distomolar

A distomolar is a supernumerary tooth located distal to

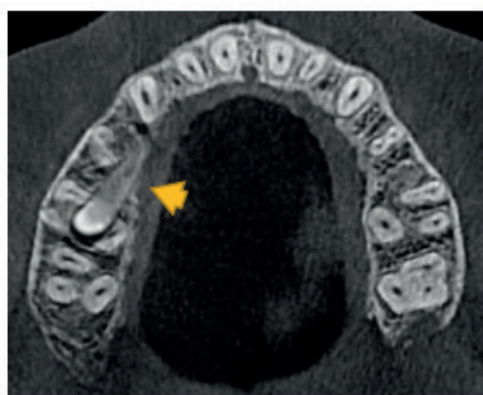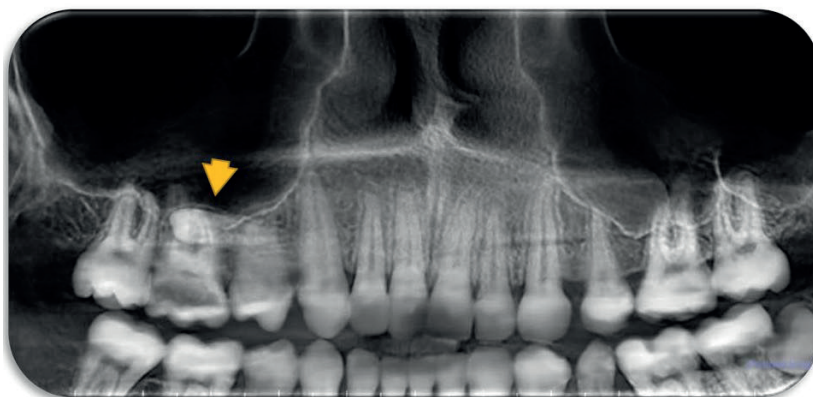
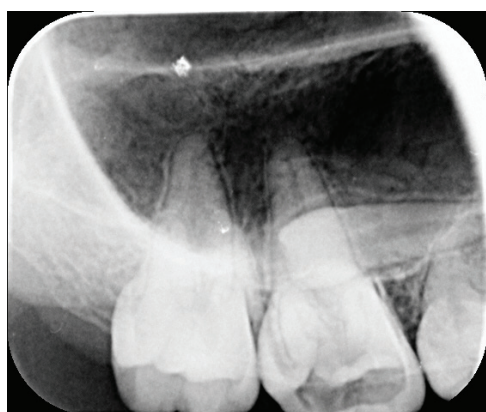a third molar and is usually rudimentary Parapremolar This is a supernumerary tooth that forms in the premolar region and resembles a premolar. The most useful radiographic investigation is the rotational tomography (OPG) and occlusal or periapical radiographs are also helpful.

► Case report:

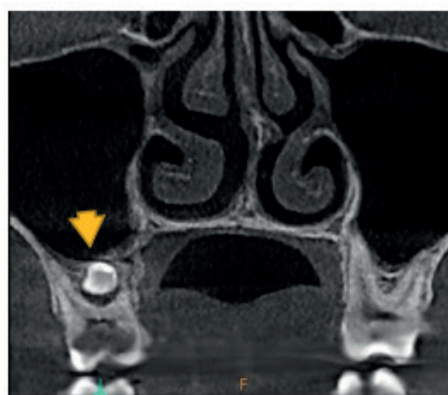
A 19 year old lady, Miss Gayathri came to the clinic with chief complaint of pain on the upper maxillary right maxillary molar region. On routine radiographic investigation [IOPA], a radio-opaque structure resembling a tooth was seen overlapping the apices of the tooth numbered 15, 16 (fig 1). Tooth numbers 14 was missing in the quadrant, which was extracted for orthodontic treatment.

This happenstance finding was later diagnosed with an OPG (fig 2) which reiterated the initial finding without throwing much light on the exact three dimensional stance of the supernumerary paramolar. A CBCT study was then undertaken to elucidate its position.

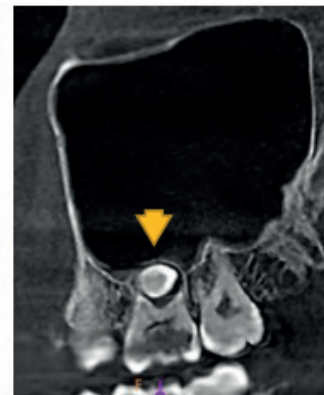CBCT revealed the position of the supernumerary tooth as follows: (fig 3)



Axial



Coronal



Sagittal

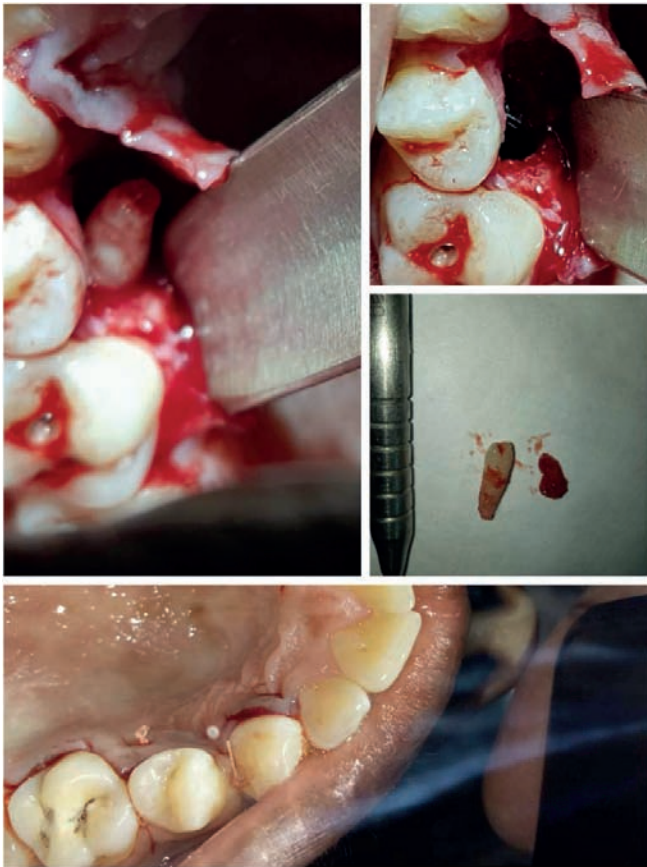


Fig 4: Surgical procedure

Localization of supernumerary tooth

- Well-defined tooth-like radiopacity with distinct enamel, dentin and pulp chamber, of size 17.7 mm (length) x 4.9 mm (buccopalatal) x 5.0 mm (mesiodistal)
- Situated in a horizontal direction within the right maxillary posterior alveolus close to the sinus floor, palatal to the root of 15 and between the roots of 16
- Crown is bicuspid, showing single root having single canal each with closed apex

- Mild superior dilaceration of root noted, starting at 2.2 mm from apex

A specific treatment plan was formed only after a thorough CBCT study. Thus a seemingly cumbersome procedure turned out to be a straightforward one without much difficulty that took only approximately 30 min (fig 4). Patient was recalled for suture removal and completion of root canal treatment of tooth numbered 16. She did not complain of any post operative complication such as pain or swelling. There was no mobility of tooth numbered 16, which remains asymptomatic till date after 3 months post surgery.

► Conclusion:

Though OPG and IOPA remains the mainstay in diagnosing impacted maxillary supernumerary teeth, CBCT has unparalleled advantage in surgical treatment planning, three dimensional mapping and predicting difficulty of maxillary impacted teeth and hence can reduce surgical time and significantly reduce postoperative complications.¹¹

► References:

1. Rajab LD, Hamdan MAM. Supernumerary teeth: review of the literature and a survey of 152 cases. *Int J Paediatr Dent* 2002;12:244–54.
2. Yusof WZ. Non-syndrome multiple supernumerary teeth: literature review. *J Can Dent Assoc* 1990;56:147–49.
3. Stafne EC. Supernumerary teeth. *Dent Cosmos* 1932;74:653–59.
4. Nazif MM, Ruffalo RC, Zullo T. Impacted supernumerary teeth: a survey of 50 cases. *J Am Dent Assoc* 1983;106: 201–04.
5. Hyun HK, Lee SJ, Ahn BD, Lee zh, Heo MS, Seo BM et al. Nonsyndromic multiple mandibular supernumerary premolars. *J Oral Maxillofac Surg* 2008;66(7):1366–69.
6. Acikoz A, Tunga U, Otan F. Characteristics and prevalence of nonsyndrome multiple supernumerary teeth: a retrospective study. *Dentomaxillofac Radiol* 2006; 35:185–90.
7. Primosh RE. Anterior supernumerary teeth – assessment and surgical intervention in children. *Pediatr Dent* 1981;3:204–15.
8. Liu JF. Characteristics of premaxillary supernumerary teeth: a survey of 112 cases. *ASDC J Dent Child* 1995;62: 262–65.
9. Von Arx T. Anterior maxillary supernumerary teeth: a clinical and radiographic study. *Aust Dent J* 1992;37: 189–95.
10. Bodin I, Julin P, Thomsson M. Hyperodontia. I. Frequency and distribution of supernumerary teeth among 21,609 patients. *Dentomaxillofac Radiol* 1978;7:15–17.
11. Radiographic predictors for maxillary canine impaction Ali Alqerbana, Reinhil de Jacobs, bSteffen, Fieuws c, Guy Willems d: *American Journal of Orthodontics and Dentofacial Orthopedics* Volume 147, Issue 3, March 2015, Pages 345–354

Comparative evaluation of antimicrobial efficacy of Chitosan, sodium hypochlorite and MTAD against *Enterococcus faecalis*—an in-vitro study

* Anu George Vettithanam, * Aswathy L Surendran, ** Rajesh Pillai,
N O Varghese, *Afzal A, ***** Samyukta Nair

Abstract

Introduction: Root canal treated teeth are about 9 times more likely to harbour *E. faecalis* than cases of primary infections and are the main reason for the failure of endodontic therapy.

Aim: Compare the antimicrobial efficacy 3% sodium hypochlorite (NaOCl), MTAD and 0.2% chitosan with and without sonic activation against enterococcus faecalis.

Method: Single rooted mandibular premolar tooth was selected. Access cavity preparation was done and canals were enlarged up to F2 Protaper size. Samples was autoclaved and canals were inoculated with *E. faecalis*. Cleaning and shaping was done with 4 irrigants NaOCl, chitosan, MTAD and saline with and without sonic agitation. CFU were measured by digital colony counter.

Result: Sonic activation resulted in less colony forming units. NaOCl showed less colony forming units while compared to chitosan and MTAD. MTAD and chitosan showed almost similar results.

Key words: *Enterococcus faecalis*, Sodium hypochlorite, MTAD, chitosan, sonic activation

KDJ 2018 | Vol. 41 | No. 4 | Pg 192-197

► Introduction

Bacteria and its products are the major cause for the development and perpetuation of periradicular diseases.¹ The root canal is dominated by obligate anaerobic bacteria and some facultative strains like *Enterococcus faecalis* have been involved in persistent infections; thus affecting the prognosis of the root canal therapy.¹

Enterococci are hardy microorganisms that adapt to the nutrient rich, oxygen depleted, ecologically complex environments of the oral cavity, gastro-intestinal tract and the vagina.² *E. faecalis* proficiently invade and escape into the dentinal tubules thereby surviving the chemo-mechanical instrumentation and intracanal medications only to reemerge and thus re infect the obturated root canal. *E faecalis* possess a number of virulence factors that may allow it to survive. According to a study conducted by Love M et al it was

concluded that the ability of the organism to cause a failure of endodontically treated teeth was in its ability to remain viable in the dentinal tubule and its capability to adhere to collagen in the presence of human serum.^{2,3}

Chemo-mechanical preparation plays a major role in disinfection by causing a drastic reduction in the bacterial populations located in the main root canal⁶. The choice of an irrigant depends on their effectiveness to serve as lubricant during instrumentation, flush debris and smear layer and according to the variations in chemical formulations; have different impact with pulp, necrotic tissues and microorganisms⁷. Sodium hypochlorite (NaOCl) is the most widely used irrigant due to its antimicrobial and organic tissue dissolving ability but it is toxic to the periapical tissues and weakens dentine by reducing its flexural strength and resilience by making it more susceptible to deformation and possibly fractures⁵.

* PG Student, ** Professor and Head of the Department, ***Principal and Professor, ****Professor, ***** Senior Lecturer, Department of Conservative Dentistry and Endodontics, PMS College of Dental Science and Research, Vattappara, Thiruvananthapuram, Kerala • Corresponding Author: Dr. Anu George Vettithanam, E-mail: anugeorgev@yahoo.com

Chitosan is an amino polysaccharide biopolymer with a unique chemical structure as a linear polycation with a high charge density, reactive hydroxyl and amino groups as well as extensive hydrogen bonding. It is obtained from chitin, which is widely distributed in nature mainly as a structural component in the exo-skeletons of arthropods (including crustaceans and insects), marine diatoms and algae, as well as some fungal cell walls.^{4,16,17,18} Chitosan based films and gels display good oxygen/moisture transmission coefficients and substantivity and also are endowed with permeation and absorption enhancing effects, enhancing the dissolution and bioavailability of poorly absorbable drugs and are also capable of binding strongly to transition metals in vitro through a chelation process and thus lending themselves to a variety of applications.^{4,16,17,18}

In the field of dentistry chitosan has shown to exhibit a potent plaque reducing action as well as in vitro antibacterial activity against several oral pathogens implicated in plaque formation and periodontitis, including *Actinobacillus actinomycetecombitans*, *Streptococcus mutans* and *Porphyromonas gingivalis*.⁶

A mixture of tetracycline, citric acid and detergent is marketed as BioPure MTAD (Dentsply, Tulsa Dental, Tulsa, OK)⁸. Tetracycline being a bacteriostatic prevents the growth of micro-organisms. and in the absence of bacterial cell wall lysis, antigenic by-products (endotoxins) are not released. It also shows the property of substantivity as it can be absorbed and gradually released from tooth structures such as cementum

and dentine also shows anti-collagenase activity^{8,19}. According to a study by Torabinejad and Khademi it was concluded that combination of 1.3% NaOCl as a root canal irrigant with MTAD as a final rinse was more effective against *E faecalis* than 5.25% NaOCl with 17% EDTA.^{8,19}

However, its greatest disadvantage is its ability to intrinsically stain teeth during odontogenesis, can chelate calcium ions and get incorporated into teeth resulting in discoloration of both primary and permanent dentitions. It is contraindicated in pregnancy. It is expensive and has a short shelf life and has to be used in 48h even if refrigerated. It demonstrates lesser compatibility to dental pulp cells for revascularization procedures^{8,19}.

Antibacterial irrigating solutions alone may not be effective to remove and kill the bacterial biofilms within the root canal [9,10]. Sonic and ultrasonic micro-energies are predominantly used in contemporary irrigation agitation techniques^{10,11,12}. There is renewed interest in sonic agitation techniques with the introduction of EndoActivator (DENTSPLY) where a smooth disposable polymer tip produces a powerful hydrodynamic turbulence within the root canal system^{12,13}. Previous studies have also proven the superiority of sonic agitation over static irrigation and passive ultrasonic agitation.^{14,15}

Thus, the aim of the study was to compare the antimicrobial efficacy of 0.2%chitosan with the commonly used root canal

Table 1: Comparison of CFUs among the study groups

Group	Irrigant used	Subgroups	CFU in 105/ml		P
			Mean(N=7)	SD	
A	NaOCl	Conventional Syringe irrigation	0.462	0.041	<0.001
		Sonic Activation	0.004	0.000	
B	Chitosan	Conventional Syringe Irrigation	0.746	0.046	<0.001
		Sonic Activation	0.008	0.001	
C	MTAD	Conventional Syringe Irrigation	0.769	0.433	<0.001
		Sonic Activation	0.059	0.004	
D	Saline	Conventional Syringe Irrigation	5.684	0.998	<0.001
		Sonic activation	3.366	0.650	

irrigants i.e. 3%NaOCl and MTAD and to compare the effects of these three irrigants in the presence of sonic agitation using EndoActivator (DENTSPLY).

► Materials and Methods

Preparation of Chitosan solution

For preparation of the 0.20% chitosan (Marine Bangalore India,) solution, 200mg was diluted in 1000 mL of 1% acetic acid and the mixture was stirred for 2 h using a magnetic stirrer until obtaining crystalline homogeneous solution with 3.2 pH.

Preparation of MTAD solution

It consisted of two parts; Part A liquid supplied in syringe (Multiple dose, 20ml). [4.25% citric acid and 0.5% polysorbate detergent (Tween 80)] and Part B powder supplied in a bottle (multiple dose 600mg) [3% doxycycline hyclate]. The nozzles of the syringe containing liquid and bottle containing powder were snugly fit. The liquid was slowly injected from the syringe into the powder. The bottle was shaken slowly back and forth for up to 60secs for complete assimilation of the powder and the liquid. The entire powder particles were ensured to be completely dissolved in the liquid and the final solution thus obtained was yellowish in colour.

56 healthy human mandibular premolar teeth extracted for orthodontic treatment were taken. Teeth were cleansed using ultrasonic scalers to render them free from calculus and

tissue tags, following which they were stored in physiological saline until use.

Access cavity was prepared. Pulp was extirpated and working length was established 1mm short of the apex where the file exited the apical foramen. Gates Glidden drills #3 (Mani INC, Tachigi-ken, Japan) were used to prepare coronal access. Initial guide path was established using no 15 K-file and worked up to size No. 25 K-file. The samples were then sterilized in an autoclave for 15mins at 121°C and 15lb of pressure to ensure complete sterilization within the canal space. Efficacy of sterilization was tested by sampling the root canal with paper points. The paper points were placed into a test tube containing 1ml reduced transport fluid, vortexed for 10s, placed onto Brain Heart Infusion Agar (BHI) Biogenix Laboratories, Thiruvananthapuram, India) and incubated at 37°C for 48h and examined for growth. The teeth were then placed into a BHI broth inoculated with 10 µl Enterococcus faecalis culture, ATCC 29212 (Growth adjusted according to 1% McFarland's Standard). The broth was kept for incubation for 96 hours at 37°C.

At the end of 4 days, the teeth were removed from the broth and excess fluid in canal was removed using sterile paper points. The specimens were divided into four groups (A, B, C, D) of 14 teeth each and the groups were further subdivided into two sub groups (I and II) of 7 specimens depending on whether conventional syringe irrigation was done or sonic activation

Table 2: Multiple comparison between the various irrigant groups

Multiple comparison	Conventional Syringe irrigation			With sonic activation		
	mean difference	se	p	mean difference	se	p
Saline VS MTAD	4.914	0.291	<0.001	3.306	0.174	<0.001
Saline VS Chitosan	4.937	0.291	<0.001	3.358	0.174	<0.001
Saline VS Hypochlorite	5.221	0.291	<0.001	3.362	0.174	<0.001
MTAD VS Chitosan	0.022	0.291	0.939	0.052	0.174	0.769
MTAD VS Hypochlorite	0.306	0.291	0.304	0.056	0.174	0.752
Chitosan VS Hypochlorite	0.283	0.291	0.340	0.004	0.174	0.982

with EndoActivator. The groups were as follows The groups were as follows:

- Group A 3% Sodium hypochlorite
 Sub group I: Conventional syringe irrigation
 Subgroup II: Sonic Activation
- Group B: 0.2% Chitosan
 Sub group I: Conventional syringe irrigation
 Subgroup II: Sonic Activation
- Group C: MTAD
 Sub group I: Conventional syringe irrigation
 Subgroup II: Sonic Activation
- Group D: (Control Group) Saline
 Sub group I: Conventional syringe irrigation
 Subgroup II: Sonic Activation

The teeth were instrumented using Protaper rotary instrument and enlarged up to Protaper F2 size instrument and concomitant irrigation was carried out using the test irrigants i.e. 3% NaOCl, 0.2%Chitosan and MTAD (1ml per minute protocol was followed). In all the conventional syringe irrigation groups; irrigation was accomplished using 30 gauge ProRinse needle(DENTSPLY) placed 1-2mm short of the working length. The time of contact of each irrigant was 1 min and final flush was done with 5 ml of distilled water to terminate the action of the irrigant.

Similarly, Sonic agitation was accomplished (Subgroup II across all the irrigant groups) with EndoActivator (Dentsply) at 10,000 cycles per second.

A sterile 30gauge needle was used to collect 0.01mL(10µL) of the sample from the canal. Using a bacterial inoculation loop;

the bacterial suspension was placed on BHI agar. Plates were then incubated at 37°C for 24Hr and the number of colony forming units were counted using the Digital colony counter and was expressed in CFUs/ml. A specimen without treatment was taken as positive control. Mean Log Colony forming Units (CFUs) were compared among the groups using analysis of variance (ANOVA) followed by post – hoc Games Howell test. The results were analyzed with the statistical Package for Social sciences (SPSS)/Predictive Analytics software version 22.

► Results of the Study

Table 1 shows the mean CFUs in the various irrigant groups including the subgroups with or without sonic activation. There was a dramatic difference in the reduction of CFU with any of the 3 irrigant groups versus saline. Out of the three irrigant groups NaOCl stood out as the most effective, followed by chitosan and then MTAD (Figure 1). However, there was no statistically significant difference in the colony counts between these three individual irrigant groups either with or without sonic activation. There was also a significant difference in each of the individual irrigation subgroups with and without sonic activation. In the group NaOCl the CFU decreased by 12 times by the use of sonic activation (Figure 2). This difference was statistically significant with p value <0.001. Similar observation was made for Chitosan and in the MTAD groups with a drastic decrease in the colony counts with sonic activation. Using saline as an irrigant resulted in colony counts greater than 12 times compared with the experimental groups. In the saline group sonic activation did result in a statistically significant difference in colony counts but not as evident as was seen in the three experimental groups

For further clarification; Table 2 presents the difference between various sub groups. As already mentioned, there is a definite statistically significant difference between saline versus any of the three irrigant groups and also within each of the

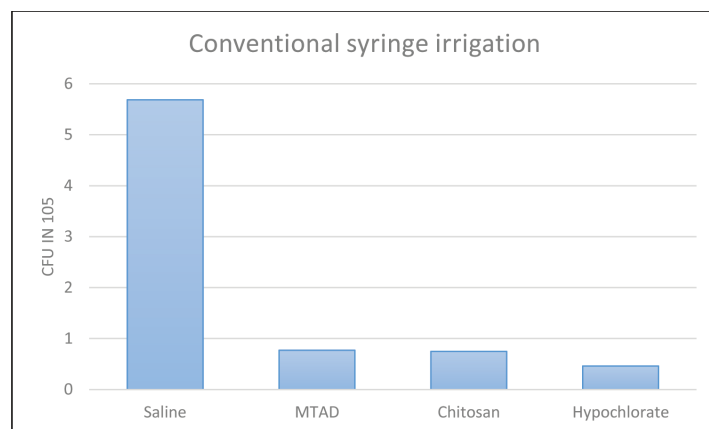


Fig 1: Colony Forming Units (CFU) with individual irrigants applied through conventional needle irrigation

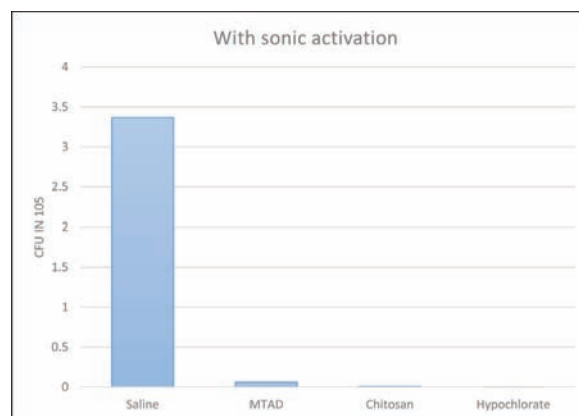


Fig 2: Colony Forming Units (CFU) with individual irrigants applied with sonic activation

experimental irrigant groups with and without sonic activation. However, there was no statistically significant difference in the CFUs between MTAD, Chitosan and Hypochlorite.

► Discussion

Many authors have concluded that to eliminate bacteria from the root canals predictably, the supporting action of a disinfecting agent is mandatory. Hence, an irrigant should ideally destroy microorganisms and neutralize their products without damaging host tissue. Therefore, the desirable concentration should have low toxicity and adequate antibacterial effects.^{20,7}

In this study it was aimed to evaluate the antimicrobial efficacy of 3% NaOCl, 0.2%Chitosan, MTAD with and without sonic activation. There are multiple studies which have compared these irrigant solutions individually but very few with a head to head comparison as in the current study. The *in vitro* study was done without decoronation of the extracted tooth samples similar to a study done by Siqueira et al, in order to mimic real world clinical practice²¹. The current study has shown that the three irrigant groups NaOCl, Chitosan and MTAD are all significantly superior to saline as an irrigant solution though the difference between them individually is not statistically significant in the number of bacterial colonies it prevents. Furthermore, sonic activation with any of the irrigant solution makes its antimicrobial efficacy significantly greater.

Sodium hypochlorite as an irrigant solution has been used for more than 70 years because of its well-known antimicrobial action and its ability to dissolve tissue. Sodium hypochlorite toxicity is directly proportional to its concentration.^{21,22,5} In one study comparing the antibacterial efficacy of 0.5% and 3% NaOCl the bactericidal effect of 3% sodium hypochlorite can reach a greater depth into dentinal tubules than the 0.5% solution, with the action of the more diluted solution being largely superficial and limited to the first 100-µm layer of the root canal wall. Increasing the concentration of sodium hypochlorite would improve the penetration depth of its antibacterial action to some extent, but complete eradication of bacteria from the dentinal tubules can hardly be achieved by needle-and-syringe irrigation with sodium hypochlorite solution alone.²⁸

Siquera et al showed that irrigation with NaOCl was significantly better than saline in its antimicrobial efficacy but failed to show any further improvement with sonic activation as in current study. They had also compared sequential irrigation with hydrogen peroxide after NaOCl with no improvement in the colony count.²¹

Chitosan's antibacterial nature is due to the interaction between positively charged chitosan and a negatively charged bacterial cell which transmutes the bacterial cell permeability,

leading to the leakage of intercellular components and cell death. Chitosan binds to DNA and inhibits mRNA synthesis by penetrating toward the nuclei of microorganisms and interfering with the synthesis of mRNA and proteins. Biofilm formation was significantly less with surface treatment with chitosan in a study by DaSilva et al.²³ In another comparative study between Chitosan, NaOCl and chlorhexidine by Yadav et al, Chitosan was found to be equivalent in efficacy to the two others, all of them being significantly better than saline²⁴. In the current study Chitosan was marginally less efficacious than NaOCl and more than MTAD, but just like the Yadav et al study there is no statistically significant difference between the irrigants.

MTAD was introduced in endodontic as a substitute to EDTA to eradicate the smear layer. It is a combination of an antibiotic 3% doxycycline, a chelating agent 4.5% citric acid and a detergent Tween 80. It has less toxicity than 5.25% NaOCl and EDTA. Previous several studies have proven the efficiency of NaOCl as a root canal irrigant over MTAD which is in concordance with this study where 3%NaOCl stood out as the best irrigant even though the difference in colony counts between 3%NaOCl and MTAD was not statistically significant.^{8,25,26}

The EndoActivator system (Advanced Endodontics, Santa Barbara, CA) is a sonically driven canal irrigation device that produces vigorous intracanal fluid agitation. This sonic device seems to be more effective in the removal of bacteria and smear layer from the root canals than conventional irrigation. Sonic agitation has been convincingly been proven to be superior in antimicrobial efficacy as compared to manual agitation or conventional needle irrigation in a study by Rajshekhar et al. Though that study used NaOCl only, in the current study, all three irrigant groups, Chitosan, NaOCl and MTAD all showed much greater and significant reduction in colony counts when sonic agitation was applied.²⁷

The results clearly demonstrated that the action of test irrigants could reduce the number of bacterial cells from the root canal. Bacterial reduction was significantly superior when NaOCl was used as irrigant. In addition to the mechanical effects, NaOCl possesses chemical effects that help in the elimination of bacteria from the root canals. The present study demonstrates the antibacterial efficacy of chitosan almost equivalent to 3%NaOCl, which may well be replaced by this potential animal extract as endodontic irrigant to overcome the deleterious effects of the conventional irrigants (NaOCl and chlorhexidine) on dentine.

► Conclusions

Within the limitations of this study, it was concluded that

1. The antibacterial activity of the chitosan groups was at par with 3% NaOCl and MTAD.

2. Chitosan is a promising candidate as a future irrigant in the field of endodontics.

3. The use of sonic activation as an adjuvant will definitely improve the antibacterial action of the irrigants used.

► References:

- Ricucci D, Siqueira JF Jr. Biofilms and apical periodontitis: study of prevalence and association with clinical and histopathologic findings. *J Endod* 2010; 36:1277–88.
- Stuart CH, Schwartz SA, Beeson TJ, Owatz CB *Enterococcus faecalis*: its role in canal treatment failure and current concepts in retreatment. *J Endod*. 2006 Feb;32(2):93–8.
- Love, Robert. (2001). *Enterococcus faecalis* - A mechanism for its role in endodontic failure. *International endodontic journal*. 34. 399–405.
- Ballal N, Kundabala M, Bhat K, Acharya S, Ballal M, Kumar R, Prakash P. Susceptibility of *Candida albicans* and *Enterococcus faecalis* to Chitosan, Chlorhexidine gluconate and their combination in vitro. *Aust Endod J*. 2009 Apr;35(1):29–33
- Sassone L, Fidel R, Fidel S, Vieira M, Hirata R. The influence of organic load on antimicrobial activity of different concentrations of NaOCl and chlorhexidine in vitro. *Int Endod J* 2003; 36:848–52
- Kim JS, Shin DH. Inhibitory effect on *Streptococcus mutans* and mechanical properties of the chitosan containing composite resin. *Restor Dent Endod*. 2013 Feb;38(1):36–42.
- Haapasalo, Markus & Endal, Unni & Zandi, Homan & Coil, Jeffrey. (2005). Eradication of endodontic infection by instrumentation and irrigant solutions. *Endodontic Topics*. 10. 77 - 102
- Torabinejad M, Cho Y, Khademi AA, Bakland LK, Shabahang S. The Effect of Various Concentrations of Sodium Hypochlorite on the Ability of MTAD to Remove the Smear Layer" (*J Endodon* 2003; 29:233–9)
- Costerton JW, Stewart PS, Greenberg EP (1999) Bacterial biofilms: a common cause of persistent infections. *Science* 284: 1318–1322
- Thomas JG (2007) The science of biofilm dynamics in oral health: a paradigm shift. *Endo Tribune* 2(1): 1,16,18–21
- Van der Sluis LWM, Wu MK, Wesselink PR (2006) The influence of volume, type of irrigant and flushing method on removing artificially placed dentine debris from the apical root canal during passive ultrasonic irrigation. *Int Endod J* 39(6): 472–476
- Gutarts R, Nusstein J, Reader A, Beck M (2005) In vivo debridement efficacy of ultrasonic irrigation following hand-rotary instrumentation in human mandibular molars. *J Endod* 31(3): 166–170
- Ruddle CJ (2008) Endodontic disinfection – tsunami irrigation *ENDODONTIC PRACTICE* FEBRUARY 2008
- Khalap ND, Kokate S, Hegde V. Ultrasonic versus sonic activation of the final irrigant in root canals instrumented with rotary/reciprocating files: An in-vitro scanning electron microscopy analysis. *Journal of Conservative Dentistry: JCD*. 2016;19(4):368–372.
- Simeone M, Valletta A, Giudice A, Lorenzo PD, Iandolo A: The activation of irrigation solutions in Endodontics: a perfected technique. *Giornale Italiano di Endodonzia* (2015) 29, 65—69
- Rinaudo M. Chitin and chitosan: Properties and applications. *Prog Polym Sci* 2006; 31: 603–32.
- Raafat D, Sahl HG. Chitosan and its antimicrobial potential—a critical literature survey. *Microb Biotechnol* 2009; 2: 186–201.
- Elsaka SE, Elnaghy AM. Antibacterial activity of calcium hydroxide combined with chitosan solutions and the outcomes on the bond strength of Real Seal sealer to radicular dentin. *J Biomed Res* 2012; 26: 193–199.
- Torabinejad M, Shabahang S, Aprecio RM, Kettering JD. The antimicrobial effect of MTAD: an in vitro investigation. *J Endod*. 2003 Jun;29(6):400–3.
- Lin LM, Skribner JE, Gaengler P. Factors associated with endodontic treatment failures. *J Endod*. 1992 Dec;18(12):625–7.
- Siqueira JF Jr, Machado A G, Silveria RM, Lopes HP, De Uzeda M (1997) Evaluation of the effectiveness of sodium hypochlorite used with three irrigation methods in the elimination of *Enterococcus faecalis* from the root canal, in vitro. *Int Endod J* 1997 Jul; 30(4): 279–82
- Forough Reyhani M, Rezagholizadeh Y, Narimani MR, Rezagholizadeh L, Mazani M, Barhaghi MHS, Mahmoodzadeh Y. Antibacterial effect of different concentrations of sodium hypochlorite on *Enterococcus faecalis* biofilms in root canals. *J Dent Res Dent Clin Dent Prospects*. 2017 Fall;11(4):215–221
- DaSilva L, Finer Y, Friedman S, Basrani B, Kishen A. Biofilm Formation within the Interface of Bovine Root Dentin Treated with Conjugated Chitosan and Sealer Containing Chitosan Nanoparticles. *Journal of endodontics*. 2013;39(2):249–253.
- Yadav P, Chaudhary S, Saxena RK, Talwar S, Yadav S. Evaluation of Antimicrobial and Antifungal efficacy of Chitosan as endodontic irrigant against *Enterococcus faecalis* and *Candida albicans* Biofilm formed on tooth substrate. *J Clin Exp Dent*. 2017 Mar 1;9(3): e361–e367
- Bansal Ramta Bansal, Ramta. (2013). A Comparison of the Antibacterial Efficiency of MTAD (Mixture of Tetracycline, Citric Acid and Detergent), 2.5% Sodium Hypochlorite and 2% Chlorhexidine Root Canal Irrigants Against *Enterococcus faecalis* in Root Canals of Single Rooted Mandibular Premolars- An In Vitro Study. *IOSR Journal of Dental and Medical Sciences*. 5. 47–53
- Dunavant TR, Regan JD, Glickman GN, Solomon ES, Honeyman AL. Comparative evaluation of endodontic irrigants against *Enterococcus faecalis* biofilms. *J Endod*. 2006 Jun;32(6):527–31.
- Chatterjee R, Venugopal P, Jyothi K N, Jayashankar C M, Kumar S A, Kumar P S. Effect of sonic agitation, manual dynamic agitation on removal of *Enterococcus faecalis* biofilm. *Saudi Endod J* 2015; 5:125–8
- T S Wong, Debbie & Cheung, Gary. (2014). Extension of Bactericidal Effect of Sodium Hypochlorite into Dentine Tubules. *Journal of endodontics*. 40. 825–9. 10.1016/j.joen.2013.09.045.

Evaluation of sealing ability of two sealers using MTAD as a final irrigant: An invitro study

* Sandeep Chandran, *Mahesh M, **Rajesh Pillai, ***N O Varghese, ****Afzal A., *****Abe Antony

Abstract

AIM: The aim of this study is to evaluate whether the precipitate formed by using MTAD as a root canal irrigant do affect the sealing ability of different root canal sealers, confirmed with a push-out bond strength test.

MATERIALS AND METHODS: A total of 20 single rooted premolars are used for this study. All the teeth are enlarged using ProTaper Gold rotary files up to F2 file size. The teeth are divided into two groups (Groups I, II) of 10 teeth each based on the types of sealers used (Resin based and

MTA based). The groups are further sub divided into subgroups (A,B,C,D) 5 of teeth each based on the irrigants used (SALINE and MTAD) and obturated. The teeth are evaluated for push-out bond strength, with the help of a universal testing machine.

RESULTS: The mean value of AH plus group, without precipitate formation showed the highest mean value for the bond strength (32.69), which was statistically higher ($P < 0.05$) than the rest of the groups. In the MTA group the samples with precipitate formation showed the least bond

strength(18.44), which was statistically lower than all the groups.

CONCLUSION: The precipitate formed by the combination of sodium hypochlorite And MTAD tends to decrease the bond strength of the sealers used for obturation.

Keywords: AH plus, MTA fillapex, MTAD, Pushout bond strength.

KDJ 2018 | Vol. 41 | No. 4 | Pg 198-201

► Introduction

The ideal success of pulp space therapy depends on a host of factors. Some of this factors include effective cleaning and shaping of the root canal, as well as creation of an apical seal¹. In root canal cleaning and shaping can be achieved with mechanical instrumentation along with copious irrigation. Irrigating solutions when used along with mechanical instrumentation play a vital role in removing pulpal irritants². Some of this include pre existing debris, dentin chips, dentinal mud, bacteria and their toxic products, and the substrate necessary for bacterial growth².

Some of the commonly used irrigating solutions are sodium hypochlorite, chlorhexidine, Ethylenediaminetetraacetic acid (EDTA), mixture of tetracycline, acetic acid and detergent Tween-80 (MTAD). Sodium hypochlorite has effective antibacterial action, organic material dissolution, and also removes the necrotic tissue³. However, there is a safety concern if sodium hypochlorite is extruded out of the root canal into the periapical tissue, resulting in destructive tissue damage. Thus new irrigating solutions like MTAD has been advocated.

MTAD (fig no: 3) is an endodontic irrigant containing 3% doxycycline, 4.25% citric acid and 0.5% polysorbate 80. The latter is a detergent. Doxycycline and other tetracyclines are not only antibacterial, but also calcium chelators⁴.

Sealers play a pivotal role in enhancing success of endodontic treatment, sealers are to attain an impervious seal between the core material and radicular dentin⁵. Resin based sealers such as AH Plus (fig 2) sealer have been used most widely because of its acceptable physical properties, biocompatibility, fluid free seal, reduced solubility, and enhanced bond to root dentin. In addition, it showed a better wettability of dentin and gutta-percha and good handling characteristics⁶.

MTA fillapex (Angelus Indústria de Produtos Odontológicos S/A, Londrina, PR, Brazil) (fig 4) was recently introduced. Its chemical composition is based on the MTA with additives to obtain a consistency suitable to be used in pulp space therapy. It is a paste system containing Portland cement, bismuth oxide, and dehydrated calcium sulfate. The biological advantages of MTA-based sealers are the induction of new tissue formation

* PG Student, **Professor and Head of the Department, ***Principal & Professor, ****Professor, ***** Senior Lecturer, Department of Conservative Dentistry and Endodontics, PMS College of Dental Science and Research, Vattappara, Thiruvananthapuram Kerala • Corresponding Author: Dr. Sandeep Chandran, E-mail: dr.sandeepchandran@gmail.com

including cellular cementum and the induction of healing of lesion. It is also engineered to penetrate into lateral canals, highly radiopaque and provides a constant release of calcium ions maintaining a high pH which elicits antibacterial effects⁸.

The aim of the study was to evaluate whether the precipitate formed by MTAD as root canal irrigant do affect the sealing efficiency and push out bond strength of two root canal sealers.

► Materials and methods

A total of Twenty sound, single-rooted, extracted mandibular premolars were taken for this study(fig. 1). The teeth were stored in saline at room temperature and were decoronated using diamond disc at the level of cemento enamel junction. Canal patency was established by inserting a No-10 K-file until it was visible through the apical foramen and the working length was adjusted and measured using a 15-K file. All the samples were shaped with Pro Taper Gold file system (Dentsply, Maillefer, Ballaigues, Switzerland) using the crown-down technique. Each canal instrumentation was carried out up to the size F2 and master apical file (MAF) No 25. During instrumentation, irrigation was carried out using 5.25% Sodium Hypochlorite. The teeth are divided into two groups (Groups I, II) of 20 teeth each based on the types of sealers used (Resin based and MTA based). The groups are further sub divided into subgroups (A,B,C,D) of 10 teeth each based on the irrigants used (0.8% Isotonic saline and MTAD) and obturated.

GROUP A: MTA based sealer with saline as irrigant

GROUP B: MTA based sealer with MTAD as irrigant

GROUP C: Resin based sealer with saline as irrigant

GROUP D: Resin based sealer with MTAD as irrigant.

Table I Comparison of mean push –out bond strength values of different irrigants in respect to two sealers

	AH PLUS		MTA FILL APEX	
	SALINE	MTAD	SALINE	MTAD
Observation 1	33.23	26.56	25.44	19.18
Observation 2	32.65	25.88	25.64	18.44
Observation 3	32.77	27.12	25.29	17.88
Observation 4	32.15	26.23	25.12	18.12
Observation 5	32.65	26.44	25.38	18.56
Mean	32.69	26.45	25.37	18.44
Std Deviation	±0.38	±0.46	±0.19	±0.49

All the samples were stored in distilled water at 37°C for 24 hours. All the samples were then cut perpendicular to their long axis, to obtain 1 mm thick slices from the middle and coronal portions, using a slow speed diamond saw with lubrication. The exact dimension of each disk was measured with a digital caliper to be within the range of 1 ± 0.04 mm. The disks were then subjected to the micro push-out bond strength, using the universal testing machine loaded with a 0.76 mm diameter stainless steel plunger, at a speed of 0.5 mm/minute until bond failure occurred. For the statistical analysis one –way analysis of variance with Post hoc analysis was performed using (Tukey multiple comparisons) was applied for statistical analysis using spss software 2.0. Statistical significance level was set as $p < 0.05$.

► Results

The mean and standard deviation values of push-out bond strength (MPa) for two irrigants and sealers were calculated. From the analysis It was found that the mean value of AH plus group, without precipitate formation showed the highest mean value for the bond strength (32.69), which was statistically higher ($P < 0.05$) than the rest of the groups. In the MTA group the samples with precipitate formation showed the least bond strength(18.44), which was statistically lower than all the groups.

► Discussion

Different irrigating solutions are used alone or in combination with one another, to aid in better cleaning and shaping, and reduction of the bacterial load in root canals. For the success of endodontic treatment it is essential that cleaning and shaping must be followed by complete obturation, with an impervious, biocompatible, and dimensionally stable material. Gutta Percha is a root canal filling material and has served as a benchmark for evaluating newer materials when used with different sealers.

A wide variety of sealers are used along with Gutta Percha. Sealers can be grouped based on their prime constituent or structure, such as, zinc oxide eugenol, calcium hydroxide, glass ionomer, and resin sealer.

In our study AH plus sealer exhibited better push out bond strength when used along with saline as an irrigant. The probable reasons of higher push-out bond strength for AH Plus could be the formation of a covalent bond by an open epoxide ring to any exposed amino groups in collagen, very low shrinkage while setting, long-term dimensional stability, inherent volumetric expansion of AH Plus may have contributed to the superior bond strength of AH Plus⁷.

MTA fillapex showed less pushout bond strength when used along with MTAD as FINAL irrigant due to discoloured precipitate formed by the interaction of sodium hypochlorite and MTAD. One of the constituents of MTAD is tetracycline and

because of their calcium chelation ability, tetracyclines have a high affinity for tooth structure, and dark brown staining can occur when root canals are irrigated sequentially by NaOCl and MTAD. This irrigation sequence also results in a reduction of the substantivity of the MTAD anti microbial action⁸.

Red-purple staining of light-exposed, root-treated dentine occurs when root canals were rinsed with 1.3% NaOCl as initial rinse followed by use of MTAD as final rinse⁸. This process involves the oxidation of doxycycline by NaOCl wherein 1 mol of oxygen is absorbed per mole of adsorbed tetracycline and converted to a red-purple product. This red-purple degradation product that resulted from photo-oxidation of doxycycline was found to be 4- α , 12- α -anhydro-4-oxo- 4-dedimethylaminotetracycline (AODTC) with a high affinity for hydroxyl apatite. The conversion of dentine bound yellow precipitate to red-purple stained dentine probably requires light exposure, as stained dentine was absent when the specimens were stored in the dark but appeared when the light-protected specimens were subsequently exposed to light⁸.

In the precipitate groups the bond strength decreased, as most of the tubules were covered with the precipitate, decreasing the patency, which did not allow the resin sealer to penetrate inside the dentinal tubules to the full extent, resulting in weaker bond strength. AH plus, which was an resin -based sealer and mta fill apex reacted with the precipitate formed by MTAD.

The primary mode of adhesion of different sealers to root dentin is by forming tags that penetrate better into the root dentinal tubules, which open after the smear layer removal by EDTA. In case sodium hypochlorite is used, these open tubules harbor enough residual sodium hypochlorite, which can react with the MTAD used finally, and leads to the formation of a precipitate, which appears to coat the root canal surface and obliterate the dentinal tubules. This could possibly be the reason for the decrease in bond strength.

Thus, further exploration is required to establish an irrigation protocol for the newer irrigating materials to be used in combination with other materials, keeping in mind their interactions with one another, avoiding the occurrence of products that could provide harmful effects on the properties of other materials.

► Conclusion

Within the limitations of our study,

- The precipitate formed by the combination of sodium hypochlorite and MTAD tends to decrease the bond strength of the sealers used for obturation.
- The highest bond strength is noted in the AH PLUS group without precipitate.




Fig 1 Tooth samples

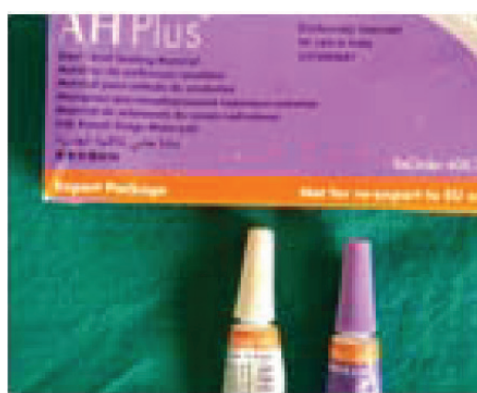

Fig 2 AH Plus Sealer



Fig 3 MTAD



Fig 4 Mtafillapex

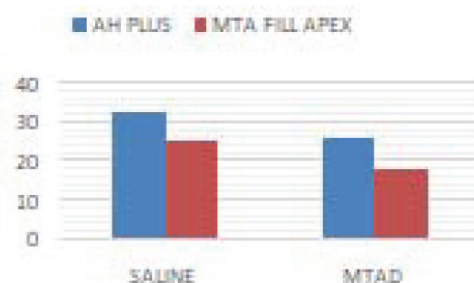


Fig 5 Graphical Representation of Mean Push out Bond Strength Values

• There is a marked decrease in the bond strength of MTA fillapex in the Presence of this precipitate, which is statistically significant

► References

1. Santos JN, Carrilho MR, De Goes MF, Zaia AA, Gomes BP, Souza-Filho FJ, Effect of chemical irrigants on the bond strength of a self etching adhesive to pulp chamber dentin. *J Endod* 2006;32:1088-90.
2. Schwartz RS. Adhesive dentistry and Endodontics. Part 2: Bonding in the root Canal system-the promise and the problems: A review. *J Endod* 2006;32:1125-32.
3. Ayhan H, Sultan N, Cirak M, Ruhi MZ, Bodur H. Antimicrobial effects of various endodontic irrigants on selected microorganisms. *Int Endod J* 1999;32:99-102.
4. Hulsmann M, Hahn W. Complications during root canal irrigation-literature review and case reports. *Int Endod J* 2000;33:186-93.
5. Leonardo MR, Tanomaru Filho M, Silva LA, Nelson Filho P, Bonifácio KC, Ito IY. In vivo antimicrobial activity of 2% chlorhexidine used as a root canal irrigating solution. *J Endod* 1999;25:167-71.
6. Verma D, Taneja S, Kumari M. Efficacy of different irrigation regimes on the push-out bond strength of various resin-based sealers at different root levels: An in vitro study. *J Conserv Dent* 2018;21:125-9.
7. Oliveira DP, Barbizam JV, Trope M, Teixeira FB. In vitro antibacterial efficacy of endodontic irrigant against *Enterococcus faecalis*. *Oral Surg oral Med Oral Pathol Oral Radiol Endod* 2007;103:702-6.
8. Tay FR, Mazzoni A, Pashley DH, Day TE, Ngoh EC, Breschi L. Potential iatrogenic tetracycline staining of endodontically treated teeth via NaOCl/MTAD irrigation: a preliminary report. *J Endod* 2006; 32:
9. Estrela C, Ribeiro RG, Estrela CR, Pécora JD, Sousa-Neto MD. Antimicrobial effect of 2% Sodium Hypochlorite and 2% chlorhexidine tested by different methods. *Braz Dent J* 2003;13:58-62.
10. Yamada RS, Armas A, Goldman M, Lin PS. A scanning electron microscopic comparison of a high volume final flush with several irrigating solutions: Part 3. *J Endod* 1983;9:137-42.
11. Shipper G, Teixeira FB, Arnold RR, Trope M. Periapical inflammation after coronal microbial inoculation of dog roots filled with guttapercha or Resilon. *J Endod* 2005;31:91-6.
12. Basrani BR, Manek S, Sodi RNS, Fillery E, Manzur A. Interaction between sodium hypochlorite and chlorhexidine gluconate. *J Endod* 2007;33:966-9.
13. Bui TB, Baumgartner C, Mitchell JC. Evaluation of the interaction between sodium hypochlorite and chlorhexidine gluconate and its effect on root dentin. *J Endod* 2008;34:181-5.
14. Torabinjad M, Cho Y, Khademi AA, Bakland LK, Shabahang S. The effect of various concentrations of sodium hypochlorite on the ability of MTAD to remove the smear layer. *J Endod* 2003;29:233-9.

Occlusal Concepts in Implants- A Review

*Jithin GN, *Amalorpavam, **T Sreelal, ***Aparna Mohan, ***Giri Chandramohan, ****Allen Jim Hines

Abstract

The present era has widely varying concepts regarding the number, location, distribution and inclination of implants required to support the functional and parafunctional demands of occlusal loading. Primary clinical dilemmas of planning for implants, their axial inclination, lengths, required volume & quality of supporting bone remain largely unanswered till date. Planning and executing optimal occlusion schemes is an integral part of implant supported restorations. Current concepts and research on occlusal loading

and overloading are reviewed together with clinical outcome and biomechanical studies and their clinical relevance discussed. Occlusal restoration of the natural dentition has classically been divided into considerations of planning for sufficient posterior support, occlusal vertical dimension and eccentric guidance to provide comfort and aesthetics. Mutual protection and anterior disclusion have come to be considered as acceptable therapeutic modalities. These concepts have been transferred to the restoration of

implant-supported restoration largely by default. However, in light of differences in the supporting mechanisms of implants and teeth many questions remain unanswered regarding the suitability of these modalities for implant supported restorations.

Key words: Occlusion, Implants, Implant Protected Occlusion.

KDJ 2018 | Vol. 41 | No. 4 | Pg 202-205

► Introduction

The goal of modern dentistry is to restore the patient to normal contour, function, comfort, aesthetics, speech & health. What makes implant dentistry unique is the ability to achieve this goal, regardless of the atrophy, disease, or injury of the stomatognathic system.

According to the literature, age is directly related to every indicator of tooth loss. Therefore aging population is an important factor to consider in implant dentistry. Aging causes several changes in bone quality and quantity, which further leads to decreased facial height, chin rotates forward giving a prognathic appearance & loss of tone of muscles of facial expression. There will be a decrease in height & width of supporting bone, decrease in keratinized mucosa, prominent mylohyoid & internal oblique ridges, loss of basal bone & muscle attachment near crest of ridge.

Early 1980's osseointegrated implants were introduced which altered the way in which partially and fully edentulous patients are treated prosthetically. The development of a proper

occlusal scheme plays a key role in the success of implants and prosthesis. Occlusion is critical for implant longevity because of the nature of the attachment of the bone to the titanium surfaced implant.

What is an Ideal Occlusion

According to GPT Occlusion is defined as any contact between the incising or masticating surface of the maxillary and mandibular teeth. Ideal Occlusion provides function without creating physiological abnormalities. Five important concepts of ideal occlusion given by Dawson (1974) are:-

- 1) Centric Relation
- 2) Anterior guidance must be in harmony with the border movements of the envelope of function
- 3) Disclusion of all the posterior teeth in protrusive movements
- 4) Disclusion of all posterior teeth on balancing side
- 5) No interference of all posterior teeth on the working side with either the lateral anterior guidance or the border movements of the condyles.

*PG student, **HOD, ***Reader, ****Senior Lecturer, Department of Prosthodontics, Sree Mookambika Institute of Dental Sciences, Kulasekharam, Kanyakumari District, Tamil Nadu.
• Corresponding Author: Dr Jithin GN, E-mail: dr.sandychandran@gmail.com

Concepts of occlusion

The dental literature has given various options on desired characteristics of occlusion of the natural dentition as well as for prosthodontic restorations. For analyses of occlusion: -

- 1) number of teeth
- 2) jaw relationships
- 3) occlusal contacts
- 4) occlusal interferences and
- 5) occlusal stability

must be verified. In a recent textbook on occlusion using an evidence-based approach, it was stated that there are no controlled studies on the optimal features of a harmonious natural and/or restored occlusion. It must be concluded that confusion remains concerning occlusal relationships. In discussions of occlusion, principles for bite registration are usually included. The literature on bite registration reveals a considerable variation and controversies regarding selection of articulators and use of facebows.

Principal components of the occlusion and their interaction

The occlusion may be viewed as consisting of three basic elements:-

- 1) posterior support
- 2) occlusal vertical dimension (OVD) and
- 3) eccentric or anterior guidance.

Posterior support

Posterior teeth provide the posterior occlusal support that bears considerable forces of mastication, swallowing and occlusal parafunction. Thus it maintains the occlusal vertical dimension.

Eccentric guidance

The eccentric guidance is the dynamic contact relation of the teeth as they slide voluntarily from maximum intercuspation (MI) to edge to edge relations in all excursions.

Parafunction

Eccentric occlusal parafunction may generate extremely high and potentially destructive loads, sufficient to wear down the teeth, fracture crowns and roots, break FPDs, dislodge or break abutment screws, fracture porcelain or superstructures, traumatize supporting bone and break implants. Planning of such an occlusal scheme should be done so as to minimize the potential destructive effects of this destructive phenomenon.

Anterior guidance

The degree of vertical and horizontal overlap determines whether the anterior teeth disclude the posteriors in protrusion

and whether the working side discludes the non-working side in lateral and lateroprotrusive excursions. When the anterior teeth disclude the posterior teeth in all excursions, this has been termed "anterior disclusion" and "mutual protection". Mutual protection is described as the molars protecting the anteriors in MI and the anterior teeth protecting the posteriors in excursions.

Mutual protection and anterior disclusion

Mutual protection and anterior disclusion are supposed to be desirable restorative occlusal schemes in tooth-supported fixed prosthodontics. Neuromuscular protective mechanisms and the mechanical advantage of a Class III lever are claimed to reduce occlusal loading, parafunction and TMDs. Applying these same principles to implants is problematic. Implants are more often supported buccally by thin buccal plates that do not have periodontal receptors and may be susceptible to cervical bone loss with occlusal overload. Considerations will vary between mixed tooth and implant-supported dentitions and between totally implant-supported fixed restorations.

Implant occlusion

The biophysiological differences between a natural tooth and endosseous dental implant are well known, but potential biomechanical characteristics derived from the differences remain controversial. The fundamental, inherent difference between the tooth and implant is that an endosseous implant is in direct contact with the bone while a natural tooth is suspended by periodontal ligament. The axial displacement of teeth in the socket are 25–100mm, whereas the range of motion of osseointegrated dental implants has been reported approximately 3–5mm (Schulte 1995). PDL is functionally oriented toward an axial load, which leads to the physiological-functional adjustment of occlusal stress along the axis of the tooth and periodontal-functional adaptability to changing stress conditions (Lindhe & Karring 1998). Furthermore, the tooth mobility from periodontal ligament can provide adaptability to jaw skeletal deformation or torsion in natural teeth (Schulte 1995). However, dental implants do not possess those advantages due to the lack of periodontal ligament. Upon load, the movement of a natural tooth begins with the initial phase of periodontal compliance followed by the secondary movement phase occurring with the engagement of the alveolar bone. In contrast, a loaded implant initially deflects in a linear and elastic pattern, and the movement of the implant under load is dependent on elastic deformation of the bone. Under load, the compressibility and deformability of PDL in natural teeth can make differences in force adaptation compared with osseointegrated implants.

A natural tooth moves rapidly 56–108mm and rotates at the apical third of the root upon a lateral load (Parfitt 1960), and

the lateral force on the tooth is diminished immediately from the crest of bone along the root (Hillam 1973). On the other hand, the movement of an implant occurs gradually, reaching up to about 10–50mm under a similar lateral load. In addition, there is concentration of greater forces at the crest of surrounding bone of dental implants without any rotation of implants (Sekine et al. 1986). The presence or absence of the PDL functions makes a remarkable difference in detecting early phase of occlusal force between teeth and implants (Schulte 1995).

Types and principles of implant occlusion

The types and basic principles of implant occlusion have largely been derived from occlusal principles in tooth restoration. Four occlusal concepts in implant occlusion are: -

- 1) Balanced Occlusion
- 2) Group Function Occlusion
- 3) Canine Protected or Mutually Protected Occlusion
- 4) Implant Protected Occlusion

Balanced Occlusion

It is defined as the simultaneous contacting of the maxillary and mandibular teeth on the right and left and in the posterior and anterior occlusal areas in centric and eccentric position developed to lessen or limit tipping or rotating of the denture bases in relation to the supporting structures (GPT).

- Unilateral balanced occlusion
- Bilateral balanced occlusion
- Protrusive balanced occlusion
- Lateral balanced occlusion

Group Function Occlusion

It is also called as the unilateral balanced occlusion. It is seen on the occlusal surface of teeth on one side. The group function on working side distributes load. Absence of contacts on the non working side prevents those teeth from being subjected to destructive forces.

Canine protected Occlusion

It is also called as mutually protected occlusion or organic occlusion. The posterior teeth protect the anterior teeth at centric relation; the incisors protect canine and posteriors in protrusion while canines protect incisors and posteriors during lateral movements. Canine is the key element of this occlusion.

Implant Protected Occlusion

It was introduced by Dr Carl E Misch which was previously called as medially positioned lingualised occlusion. Factors affecting implant protected occlusion are: -

- No premature occlusal contacts or interferences

- Influence of surface area
- Mutually protected articulation
- Implant body angle to occlusal load
- Cusp angle of crown (cuspal inclination)
- Cantilever or offset distance
- Crown height
- Occlusal contact position
- Implant crown contour
- Protect the weakest component
- Occlusal materials

This concept is designed to reduce occlusal force on implant prostheses and thus to protect implants. For this, several modifications from conventional occlusal concepts have been proposed, which include providing load sharing occlusal contacts, modifications of the occlusal table and anatomy, correction of load direction, increasing of implant surface areas, and elimination or reduction of occlusal contacts in implants with unfavorable biomechanics. Basic principles of implant occlusion may include:-

- (1) bilateral stability in centric (habitual) occlusion,
- (2) evenly distributed occlusal contacts and force,
- (3) no interferences between retruded position and centric (habitual) position,
- (4) wide freedom in centric (habitual) occlusion,
- (5) anterior guidance whenever possible and
- (6) smooth, even, lateral excursive movements without working/non-working interferences.

Occlusal guidelines for different clinical situations

In case of a full-arch fixed prosthesis, if the opposing arch is a complete denture, balanced occlusion is recommended. Group function or mutually protected occlusion with shallow anterior guidance is recommended when opposing natural dentition or a full-arch fixed prosthesis. There should be no working side and balancing contact on the cantilever. In case of overdentures, bilateral balanced occlusion with lingualized occlusion should be used. In case of severely resorbed ridges, monoplane occlusion should be used.

If the posterior arch is rehabilitated with a fixed prosthesis, contacts should be centered over the implant body, and narrow occlusal tables, flat cusps with minimized cantilever should be employed. Where necessary, the posterior occlusion must be placed in crossbite. Anterior guidance should be with the natural dentition, and group function occlusion should be employed with compromised canines.

As suggested by Quirynen M et al in case of the fully edentulous maxilla, whether the mandibular rehabilitation is done on an overdenture supported on two implants or on a

mucosal-implant-supported overdenture (four implants with a bar attachment), a balanced occlusal scheme (bilateral/lingualized/monoplane) is recommended. In conditions where a Kennedy class I partially edentulous condition is present in the maxillary arch and mandibular mucosal implant supported (four implants with a bar attachment) or an implant-supported prosthesis is planned for the mandibular arch, balanced occlusion is recommended. In case of a maxillary arch presenting with Kennedy class II condition, if a mucosal-implant-supported prosthesis is planned for the mandibular arch, balanced occlusion is recommended. If an implant-supported prosthesis is advised for the mandibular arch, group function or mutually protected occlusion is advised. In case of Kennedy's class I in maxillary arch that has been restored with fixed denture prosthesis or with implants, and a mandibular implant-supported prosthesis is advised, it is recommended to follow group function or mutually protected occlusion. In cases where the maxillary arch presents with Kennedy's class III and IV and implant-supported prosthesis is advised for the mandible, group function or mutually protected occlusion is recommended. Lastly, in case of the fully dentate maxilla and implant-supported prosthesis, group function or mutually protected occlusion is recommended.

► Conclusion

A poor selection of occlusal scheme can lead to biological and mechanical complications. The various consequences that can be encountered are implant failure, early crestal bone loss, screw loosening, uncemented restorations, component failure, porcelain fracture, prosthesis fracture, and peri-implant disease. An Implant Protected Occlusal scheme resolves several conditions to minimize overload on bone/implant interfaces and implant prostheses, thus restricting implant loads within

physiological limits. The guidelines need to be implemented in specific conditions to decrease stresses and develop an occlusal scheme to allow the restoration to function in harmony with the rest of the stomatognathic system and to maximize the longevity of the implants and prosthesis.

► References

- (1) Chapmann R J, Principles for occlusion of Implant Prostheses: guidelines for position, timing & force of occlusal contacts, Quintessence Int 1989; 20:473-80.
- (2) Carlsson G E, Dental Occlusion: modern concepts and their application in implant prosthodontics, Odontology 2009; 97: 8-17.
- (3) Schulte W, Implants & the periodontium, Int Dent J 1995; 45: 16-26.
- (4) Schuyler C H, Considerations of Occlusion in fixed partial dentures. Dent Clin North Am 1959; 37: 175-85.
- (5) Gross MD, Occlusion in implant dentistry. A review of the literature of prosthetic determinants and current concepts, Aust Dent J. 2008;53: 60-8.
- (6) Abhichandani S J, Bhojaraju N, Guttal S, Srilakshmi J, Implant Protected Occlusion: A Comprehensive Review, Eur J Prosthodont 2013; 1: 29-36.
- (7) Kim Y, Oh T J, Misch C E, Wang H L, Occlusal considerations in implant therapy: Clinical guidelines with biomechanical rationale. Clin Oral Implants Res 2005; 16: 26-35.
- (8) Verma M, Nanda A, Sood A, Principles of occlusion in implant dentistry, J Int Clin Dent Res Organ 2015;7: 27-33.
- (9) Swaminathan Y, Rao G, Implant Protected Occlusion, IOSR JDMS 2013; 11: 20-25.
- (10) Parfitt G J, Measurement of the physiological mobility of individual teeth in an axial direction, J Dent Res 1960; 39: 608-618.
- (11) Beyron H, Optimal Occlusion, Dent Clin North Am, 1969;13:537
- (12) Dawson P E: Evaluation, Diagnosis & Treatment of Occlusal problems, A Textbook of Occlusion.
- (13) Carl E Misch, A Textbook of Clinical Implantology, Elsevier.
- (14) Quirynen M, Naert I, van Steenberghe D, Fixture Design & overload influence marginal bone loss & fixture success in the branemark system. Clin Oral Implants Res 1992;3:104-11.
- (15) Lindhe J, Karring T, Anatomy of Periodontium, Clin Periodontology & Implant Dentistry 3rd edition Copenhagen 1998.
- (16) Hillam DG Stresses in the periodontal ligament, J Periodontal Res 1973; 8: 51-6.

Critical - size defect models in periodontal regeneration

* Thomas George, **Nebu George Thomas, ***Saumya John,
 Prameetha George Ittycheria, *Neethu Mercy James

Abstract

Periodontitis leading to the progressive destruction of tooth-supporting tissues is the major cause of tooth loss in adults. Though the ultimate therapeutic goal of periodontal therapy is to completely reconstruct those tissues lost to the disease process, the currently available conventional periodontal therapies is known to improve the clinical outcomes characterized by repair with little or no periodontal regeneration. The arena of periodontal regeneration is vast expanding with the development of various biomaterials, with an attempt to regenerate the damaged periodontium. Critical size defects are used in periodontal

research to evaluate the efficacy and safety of biologic constructs used for supporting or inducing periodontal regeneration in animals prior to clinical application. The present review article provides an overview of the previous studies which is relevant within the field of critical size defects in animal models used in the field of periodontal regeneration to provide guidance for researchers.

Scientific relevance: The search for newer regenerative therapies requires preclinical evaluation. Histologic analysis is the gold standard to determine the type of attachment after periodontal therapy

where in new attachment with periodontal regeneration should be the ideal outcome. Animal models offer the opportunity for histological observations. Thus, critical size defects in animal models can be used to determine the type of attachment and biologic potential and establish clinical potential and efficacy prior to clinical application.

Keywords: Experimental animal models, periodontal regeneration, critical size defects, alveolar bone, calvarial defects

KDJ 2018 | Vol. 41 | No. 4 | Pg 206-211

Periodontitis causes destruction of the tooth supporting tissues due to inflammation induced by bacterial plaque and results in different types of bone defects. This disease can be treated by mechanical and chemical means to control inflammation by reducing or eliminating the responsible microbial pathogens. Periodontal bone defect will lead to the loss of a tooth, which affects not only mouth function but also the esthetics of one's life. The morphology of the bone defect largely determines the treatment techniques to be used. One-wall angular defects usually need to be recontoured surgically. Three-wall defects if deep and narrow appear to be fortunate candidates for regenerative surgery compared with its wide, shallow¹ variant. Two -wall defects can be treated with either these methods depending on their width, depth and general configuration. Clinical studies have provided ample evidences

indicating that conventional periodontal therapy may improve clinical outcomes, but the healing is predominantly characterized by repair with little or no periodontal regeneration.² As the ultimate therapeutic goal of periodontal therapy is to completely reconstruct those tissues lost to the disease process with tissues that are structurally and functionally the same³, new attachment with periodontal regeneration is the ideal outcome of the therapy because it results in reconstruction of periodontium. A successful periodontal reconstruction predominantly comprises of regeneration of tissues including cementum, periodontal ligament, bone and gingiva.

Histologic analysis is the gold standard to determine the type of attachment and the amount of new cementum, periodontal ligament, and alveolar bone formed as the result of regenerative periodontal surgery. These analyses are not

* HOD and Professor, **Professor, ***Senior Lecturer, ****Post graduate student, Dept. of Periodontics, Pushpagiri College of Dental Sciences, Pushpagirimedicity, Perumthuruthy, Tiruvalla - 689107, Kerala • Corresponding Author: Dr. Thomas George M. E-mail: thomasgeorge@rediffmail.com

possible in humans because of the need to remove a tooth with its periodontium in Periodontitis causes destruction of the tooth supporting tissues due to inflammation induced by bacterial plaque and results in different types of bone defects. This disease can be treated by mechanical and chemical means to control inflammation by reducing or eliminating the responsible microbial pathogens. Periodontal bone defect will lead to the loss of a tooth, which affects not only mouth function but also the esthetics of one's life. The morphology of the bone defect largely determines the treatment techniques to be used. One-wall angular defects usually need to be recontoured surgically. Three-wall defects if deep and narrow appear to be fortunate candidates for regenerative surgery compared with its wide, shallow¹ variant. Two -wall defects can be treated with either these methods depending on their width, depth and general configuration. Clinical studies have provided ample evidences indicating that conventional periodontal therapy may improve clinical outcomes, but the healing is predominantly characterized by repair with little or no periodontal regeneration.² As the ultimate therapeutic goal of periodontal therapy is to completely reconstruct those tissues lost to the disease process with tissues that are structurally and functionally the same³, new attachment with periodontal regeneration is the ideal outcome of the therapy because it results in reconstruction of periodontium. A successful periodontal reconstruction predominantly comprises of regeneration of tissues including cementum, periodontal ligament, bone and gingiva.

Histologic analysis is the gold standard to determine the type of attachment and the amount of new cementum, periodontal ligament, and alveolar bone formed as the result of regenerative periodontal surgery. These analyses are not possible in humans because of the need to remove a tooth with its periodontium in large blocks from the healed area after successful treatment.

Animal models usually offer the opportunity for histological observations, which may contribute towards the better understanding of the nature of healing. On the basis, to test the outcome of therapy, defects must be produced in laboratory animals which share the same characteristics as those found in humans. As it is difficult to find naturally occurring periodontal bone defects that would be appropriate for the study in animals, experimentally induced bone defects are absolutely an alternative approach. These types of surgically produced defects can also help to stimulate the shape of osseous periodontal lesions.

Critical size defects

The term "Critical Size Defect" (CSD) in bone has been initially described by Schmitz & Hollinger (1986)⁴ as "the smallest size defect in a particular bone, that will not heal spontaneously during the lifetime of the animal". However, as the animal lifetime used in majority of clinical research is

thoroughly bounded by the completion of the study, the CSD concept was revisited by Cooper et al. (2010)⁵ which recently referred to the smallest size of a defect that does not heal spontaneously when left untreated for a certain period.

Among the animal kingdom, CSD models have been described for large animals (i.e., nonhuman primates, dogs and pigs) and small animals (i.e. rabbit, rat). Critical size defects are used in periodontal research to evaluate the efficacy and safety of biologic constructs used for supporting or inducing periodontal regeneration prior to clinical application. The most commonly used experimental models in periodontal research are the monkeys and dogs. Every model possesses its own advantage and disadvantage and there is no such model truly fit for all kinds of studies. The dental configuration of larger species of animals like nonhuman primates and dogs resemble human dento alveolar architecture more closely than that of smaller animals like rabbits and rats. But the major limitation of larger animals is that they are expensive and require specialized breeding and maintenance facilities, which limits their use to only specialized centres equipped with appropriate staff. Smaller animals are often preferred over larger animals because of the significantly lower costs, easier housing and handling, and minimal social concern while their major drawback is the limited similarity of their dentition to human dentition. In this mini-review of literature, selective citation has been made of relevant studies within the field of critical size defects in animal models used in the field of periodontal regeneration so as to provide guidance for researchers.

Non-human primates

Non-human primates are considered as the closest experimental model to humans, on the basis of their anatomical and biological similarities (Muschler et al., 2010)⁶. Monkeys are on the edge of being phylogenetically similar to humans. Histologically, the structure of the periodontium is also similar to that observed in humans. A major proportion of non-human primates have similar deciduous and permanent dental formulas as man with closely related dental anatomy, although the size of teeth is dramatically smaller. The most preferred non-human primates in periodontal research are macaques, baboons, chimpanzees and marmosets. First three have the same dental formula as human while marmosets have a different formula with 3 premolars and 2 molars in a quadrant. Smaller non-human primates such as marmosets have small oral cavities which may preclude their used for certain periodontal procedures.

Caton et al. (1994)⁷ described 3 types of experimentally-induced periodontal defects. (i) the acute defect model, (ii) the chronic defect model and (iii) the acute/chronic defect model. In the acute model, all defects are surgically-induced by removing all the periodontal components (bone, cementum and

periodontal ligament). The spontaneous regeneration of these reproducible defects is the major limitation of this method. In the chronic model, lesions are obtained by placing orthodontic elastics, silk sutures or ligatures around teeth during 12 to 20 weeks, depending on the type of animal studied. These defects are deeper in the interproximal spaces than in the buccal or lingual surfaces. In the combined acute/chronic model, the defects are surgically-created and ligatures are placed to ensure calculus accumulation and to prevent spontaneous regeneration of the defects. The size of the defect created depends on the anatomy and physiology of the species considered.

Standardized 2-walled (lingual and proximal) periodontal defects were created surgically by Ling et al (1994)⁸ using a diamond bur at the mesial surface of the mandibular lateral incisor on one quadrant. The height of the defect measured from the bottom of the defect to the crest of the lingual wall was 5 mm and the mesio-distal width was 3 mm. Sculean et al (1997)⁹ described a method by which bone defects, with a depth of approximately 6-8 mm and a width of 3-5 mm in the bucco-lingual direction were produced by means of a round bur at the mesial surfaces of 37, 35, 45, 47 and the distal surfaces of teeth 11, 21, 31, 41. To prevent spontaneous healing, metal strips were fixed to the tooth surface in the defect with a composite material.

All the teeth can be used in case of non-human primates, which makes it possible to obtain multiple test sites, with a limited number of animals. For example, in the study by Sculean et al in (2000)¹⁰, 24 critical -sized intraosseous defects were created at the level of the incisors and premolars in only 3 monkeys. The intraosseous defects were located in the mesial part of each tooth and had a depth of between 6 and 8 mm. This model is quite similar to those used in clinical human studies, and, for this reason, appears to be a pertinent animal model. The expense, ethical issues and special husbandry requirements for these animals limit their use in periodontal studies. Besides, wild captured monkeys can be disease carriers. Monkeys are also prone to systemic infections and diseases and pose difficulties in controlling post-surgical infections and trauma.

DOG

The docile temperament and natural susceptibility to periodontal disease make dog a preferable model in dental research for the study of periodontal disease progression, guided tissue regeneration, tissue wound healing, and dental implants. All dogs are diphyodont with deciduous and permanent dentition. Also, the periodontal tissues and the size of the teeth are quite similar to those observed in humans. The formula for permanent dentition is I 3/3, C1/1, Pm 4/4, M 2/3. The beagle is one of the most commonly used dog models due to its size and its extremely cooperative nature for evaluating periodontal regenerative therapies.

Several studies were found involving dogs to evaluate the regenerative procedures. Similar to the intrabony defect models in monkeys, Wikesjö et al (1994)¹¹ demonstrated that intrabony defects can be created in dogs. Critical-sized supra-alveolar defects measuring 5 mm were created surgically by removing alveolar bone around the full circumference of second, third, and fourth mandibular premolars. Intraosseous defects can also be created on upper jaw. Saito et al (2003)¹² created circumferential periodontal defects around all maxillary and mandibular premolars. The defect height from cemento-enamel junction to reduced alveolar bone crest was 4 mm. The exposed root surfaces were curetted to remove the periodontal ligament and superficial cementum.

In summary, the most commonly used animal model in periodontal research seems to be dogs due to reproducible critical-sized defects. However skeletal remodeling in the dog is more rapid than in the primates and humans (Giannobile et al. 1994)¹³ and also great variations in attachment loss between adjacent surfaces make it difficult to document the presurgical size of the defect and to evaluate the postsurgical healing response (Selvig, 1994)¹⁴. In addition, there are some other limitations of studying in dogs. The ethical policies regarding studies in dogs are very stringent. Also, dogs require special treatment such as exercise, maintenance, special daily care, husbandry issues, daily companionship and requirement of large space makes them less desirable for periodontal research.

MINIPIGS

Since the decade which involved the development of the Minnesota miniature pig (minipig) in 1949 at the Hormel Institute (USA), miniature pigs have been used as a large animal model in medical studies for scientific, economic, and ethical reasons.^{15,16} Studies have reported mini-pigs in dental research, mainly related to dental implant surgery and periodontal regeneration by enamel matrix derivatives as the oral maxillofacial structures of miniature pigs are similar to that of humans in anatomy and physiology.¹⁷

The miniature pig has both deciduous and permanent dentitions. The initiation of tooth development and eruption in the miniature pig is quite similar to that in humans. The dental formula of the deciduous dentition for the miniature pig is Di3/3, Dc1/1, Dp1/1, Dm3/3 (Weaver et al, 1966), or Di3/3, Dc1/1, Dp2/3, Dm2/1 (Li, 1993); for the permanent dentition it is I3, C1, P4, M3 (maxillary) and I3, C1, P3, M3 (mandible) The size and morphology of the miniature pig's deciduous teeth are similar to humans. However, almost all the permanent teeth in the miniature pig are larger than in humans.

CSD of the minipig mandible was 6 cm when the periosteum was preserved and 2 cm when the periosteum was removed¹⁸. The

minipig is an ideal animal model to study the bone regeneration efficacy of various synthetic bone grafts and scaffolds as their metabolism is similar to humans.^{19,20,21} Similarities between human and mini pig temporomandibular joint function, the shape, size, and anatomy of the mandible and bone turnover rate are made it suitable candidates for periodontal research.²²

RABBIT

Rabbit have been used to study surgically induced periodontal defect and periodontal regeneration. Critical-sized femoral defects are traditionally the most commonly used models in rabbits.²³ These defects in long bone are far from the specific situation of periodontal diseases but appear as a very interesting model for testing the bone healing.

The rabbit calvaria model has been widely used for the evaluation of graft materials in bone regeneration experiments because it permits surgical access and management compared with small rodent models (Szpalski et al. 2010)²⁴. Compared with other large animals (monkeys, dogs and minipigs), the rabbit can be considered as a more economical model to purchase and maintain (Haemmerle et al. 1992²⁵; Szpalski et al. 2010²⁴). Moreover, the anatomical and physiological characteristics of rabbit calvaria are sufficiently close to that of humans (Mardas et al. 2014)²². The insufficient blood supply and deficiency in bone marrow make it a good test area for the evaluation of bone repair and regeneration materials (Schmitz & Hollinger 1986)⁴. Studies conducted in rabbit calvaria have found that defects of diameter of 15 mm can be more considered critical (Hollinger et al. 1989)²⁶. Round dental burs, and trephine burs are used to create the bony defects. The round/fissure dental burs were the most commonly used method for square and rectangular defects, whereas circular trephines were the most commonly used method to create cylindrical defects. Critical size defects in the of range of 15 x 6 mm² (Jiang et al. 2006)²⁷, 12 x 8 mm² (Li et al. 2010)²⁸, diameter of 5mm (Liu et al. 2011)²⁹ and diameter of 6 mm (Park et al. 2013)³⁰ had been created in the mandible of rabbits.

With respect to the dental anatomy, some predominant differences compared to the human situation are present. In rabbits the teeth show open apices, they continuously erupt, and their roots are partially covered by enamel. In fact, the continuously growing rabbit molars do not exhibit an anatomic division into crown and root unlike the human situation. The average eruption velocity of rabbit molars is 2–3mm per week. Continuous tooth eruption has also been described for incisors in rats. Surprisingly, in contrast to rabbits, rat molars demonstrate this continuous eruption feature to a much lesser extent.

RAT

The widespread use of rodents in periodontal research attests

the utility of these animals. The rodent model is quite predictable in the sense of reproducing the disease with a high degree of reliability. Rodents have been used in periodontal research due to their advantages such as their small size, low cost, availability, handling and housing and detailed knowledge about their genetic structure. Most histologic features of the epithelium and connective tissue in the rat are similar to humans except for the sulcular epithelium which is keratinized (Listgarten 1975).

In 1997, a surgical model in rats was proposed by King et al.³¹ The defect width was standardized to the width of the bur (1.5 mm) and extended longitudinally (4 mm) immediately to either side of the two exposed buccal roots. This surgical model on the rat was reprised by Huang et al.³². Critical size defects of 4 mm in diameter were created in the left mandibular bodies of the rats for evaluation of the efficacy of osteoconductive scaffolds (Arosarena et al. 2003)³³. Critical size defects of 5 mm in diameter were created in the ascending ramus of the mandible⁵ of the evaluation of synthetic bone matrixes (Jiang et al. 2009).³⁴ Thus critical size defects were used to study the efficacy of different materials such as barrier membranes³⁵, bone grafts³⁶, growth factors³⁷ and hormones³⁸ in bone regeneration procedures.

Rat critical size calvarial defect model can be considered as a classical model in the assessment of periodontal regeneration. This experimental model is very accurate and popular among researchers, mainly due to certain reasons: the calvarial bone configuration establishes a uniform, reproducible and standardized defect that can be easily evaluated on the basis of radiographic and histological analysis; the biological inertness of skull (Prolo et al. 1984)³⁹; the anatomic location provides an adequate size for surgical access and intraoperative handling; the dura and the overlying skin set up an optimum support for implanted materials. (Gomes & Fernandes 2011)⁴⁰.

Variant defect sizes have been reported in the literature as being critical, with defects of 5 mm and 8 mm of diameter, the most commonly performed. Bosch et al (1998)⁴¹ reported that two defects of 5mm diameter (2.5 mm outwards from the center point of each side) can be created on each side of the skull. The main advantage of the 5.0 mm-diameter defect is the fact that the control and the experimental sites can be performed in the same animal, in a standardized way, as the dimensions of adult rat calvaria usually allow the creation of two defects of this dimension in the parietal bones and the avoidance of the inclusion of the sagittal suture in the defect, minimizing the risk of midsagittal sinus lesion. On the other hand, these laterally performed craniotomies may allow substance diffusion and impair local repair/regeneration due to the close vicinity of adjacent defects, which may blight the relevance of the model.⁴² Accordingly, the 8 mm defect continues to be used in many

reports which aim to assess different bone therapeutic strategies.

Furthermore, rats are well accepted models for periodontal research. The breeding and housing costs are relatively low, making it possible to carry out studies with sufficient numbers for statistical analysis. However, the continuous occlusal eruption and osseous apposition on the dental roots makes the modelling and analysis of the results difficult and can result in significant bias.

Future scope of critical size defect models

The utilization of the critical size defect model can be initiated as a first step in evaluating clinical scenarios, but it must be present in mind that even though an insight into the healing process is possible with these models, the observations are not directly translated to humans. It is highly important to emphasize that optimization of these models, which stimulates the healthy and systemic conditions, is a crucial step for conducting future research in order to ensure that the principles of the 3Rs (reduction, refinement, replacement) are followed. Furthermore, in future, comparative studies with variant defect sizes in standardized healing conditions are to be warranted to evaluate the smallest intraosseous defect in animals that does not heal spontaneously over the duration of the study and therefore can be used as a standard defect. Clinical evaluation should be limited to therapies showing promising results in such experimental models.

► Conclusion

It has been proven that the search for newer regenerative therapies requires preclinical evaluation in well characterized experimental models to determine biologic potential and safety, and analysis in discriminating large experimental models to establish clinical potential and efficacy. The use of pre-clinical in vivo models as an analog to the human is considered critical, not only because of the ethical concerns regarding safety but also regarding the economic, issues, as well as regulatory concerns.

► Reference

- Cortellini P, Tonetti M. Focus on intrabony defects: guided tissue regeneration. *Perio* 2000; 22: 104–132.
- Caton JG, Greenstein G. Factors related to periodontal regeneration. *Periodontol* 2000; 1993: 1:9–15.
- Wikesjö UM, Sigurdsson TJ, Lee MB, Tatakis DN, Selvig KA. Dynamics of wound healing in periodontal regenerative therapy. *J Calif Dent Assoc* 1995; 23: 30–35.
- Schmitz, J.P. & Hollinger, J.O. The critical size defect as an experimental model for craniomandibulofacial nonunions. *Clin. Orthop. Rel. Res* 1986; 205: 299–308.
- Cooper, G., Mooney, M., Gosain, A., Campbell, P., Losee, J. & Huard, J. Testing the critical size in calvarial bone defects: revisiting the concept of a critical-size defect. *Plast Reconstr Surg* 2010; 125: 1685–1692.
- Muschler GF, Raut VP, Patterson TE, et al. The design and use of animal models for translational research in bone tissue engineering and regenerative medicine. *Tissue Eng Part B Rev* 2010; 16: 123–145.
- Caton J, Mota L, Gandini L, & Laskaris B. Non-human primate models for testing the efficacy and safety of periodontal regenerative procedures. *J Periodontol* 1994; 65: 1143–50.
- Ling LJ, Lai YH, Hwang H, Chen H. Response of regenerative tissues to plaque: a histological study in monkeys. *J Periodontol* 1994; 65(8): 781–7.
- Sculean A, Karring T, Theilade J, Lioubavina N. The regenerative potential of oxytalan fibers. an experimental study in the monkey. *J Clin Periodontol* 1997; 24(12): 932–6.
- Sculean A, Donos N, Brex M, Reich E, Karring T. Treatment of intrabony defects with guided tissue regeneration and enamel matrix-proteins. an experimental study in monkeys. *J Clin Periodontol* 2000; 27(7): 466–72.
- Wikesjö UM, Kean CJ, Zimmerman GJ. Periodontal repair in dogs: supraalveolar defect models for evaluation of safety and efficacy of periodontal reconstructive therapy. *J Periodontol* 1994; 65(12): 1151–7.
- Saito E, Saito A, Kawanami M. Favorable healing following space creation in rhBMP-2-induced periodontal regeneration of horizontal circumferential defects in dogs with experimental periodontitis. *J Periodontol* 2003; 74(12): 1808–15.
- Giannobile W. V., Finkelman R. D. & Lynch S. E. Comparison of canine and non-human primate animal models for periodontal regenerative therapy. Result following a single administration of PDGF/IGF-I. *J Periodontol* 1994; 65: 1158–68.
- Selvig K. A. Discussion. Animal models in reconstructive therapy. *J Periodontol* 1994; 65: 1169–72.
- D. C. England, L. M. Winters, and L. E. Carpenter, “The development of a breed of miniature swine; a preliminary report,” *Growth* 1954; 18(4): 207–214.
- I. A. Polejaeva, S. H. Chen, T. D. Vaught et al., “Cloned pigs produced by nuclear transfer from adult somatic cells,” *Nature* 2000; 407(6800): 86–90.
- S. Wang, Y. Liu, D. Fang, and S. Shi, “The miniature pig: a useful large animal model for dental and orofacial research,” *Oral Diseases* 2007; 13 (6): 530–537.
- Jin-Ling Ma, Ju-Li Pan, Bao-Sheng Tan and Fu-Zhai Cui. Determination of critical size defect of minipig mandible. *J Tissue Eng Regen Med* 2009; 3: 615–622.
- Pieri F, Lucarelli E, Corinaldesi G, et al. 2009; Effect of Mesenchymal Stem Cells and Platelet-Rich Plasma on the Healing of Standardized Bone Defects in the Alveolar Ridge: A Comparative Histomorphometric Study in Minipigs. *J. Oral Maxillofac. Surg.* 67: 265–272.
- Konopnicki S, Sharaf B, Resnick C, et al. 2015; Tissue-engineered bone with 3-dimensionally printed -tricalcium phosphate and polycaprolactone scaffolds and early implantation: an in vivo pilot study in a porcine mandible model. *J. Oral Maxillofac. Surg* 73: 1016.e1–1016.e11.
- Kuo T, Lee S-Y, Wu H-D, et al. 2015; An in vivo swine study for xeno-grafts of calcium sulfate-based bone grafts with human dental pulp stem cells (hDPSCs). *Mater Sci Eng C Mater Biol Appl* 50: 19–23.
- Mardas, N., Derekz, X., Donos, N. & Dard, M. (2014) Experimental model for bone regeneration in oral and cranio-maxillofacial surgery. *Clin Orthop Relat Res* 2014; 27: 32–49.
- Schmitt JM, Buck DC, Joh SP, Lynch SE, Hollinger JO. Comparison of porous bone mineral and biologically active glass in critical-sized defects. *J periodontol* 1997; 68: 1043–1053.
- Szpalski, C., Barr, J., Wetterau, M., Saadeh, P. & Warren, S. Cranial bone defects: current and future strategies. *Neurosurg Focus* 2010; 29: 1–11.
- Haemmerle, C.H., Schmid, J., Olah, A.J. & Lang, N.P. Osseous healing of experimentally created defects in the calvaria of rabbits using guided bone regeneration. A pilot study. *Clin Oral Implants Res* 1992; 3: 144–147.
- Hollinger, J.O., Schmitz, J.P., Mizgala, J.W. & Hassler C. An evaluation of two configurations of tricalcium phosphate for treating craniotomies. *J Biomed Mater Res* 1989; 23: 17–29.
- Jiang X, Gittens SA, Chang Q, et al. 2006; The use of tissue engineered bone with human bone morphogenetic protein-4-modified bone-marrow stromal cells in repairing mandibular defects in rabbits. *Int J Oral Maxillofac Surg* 35: 1133–1139.

28. Li J, Li Y, Ma S, et al. 2010; Enhancement of bone formation by BMP-7 transduced MSCs on biomimetic nanohydroxyapatite/polyamide composite scaffolds in repair of mandibular defects. *J Biomed Mater Res Part A* 95A: 973–981.
29. Liu H-C, E L-L, Wang D-S, et al. 2011; Reconstruction of alveolar bone defects using bone morphogenetic protein 2 mediated rabbit dental pulp stem cells seeded on nanohydroxyapatite/collagen/poly(L-lactide). *Tissue Eng Part A* 17: 2417.
30. Park J-B, Lee K, Lee W, et al. 2013; Establishment of the chronic bone defect model in experimental model mandible and evaluation of the efficacy of the mesenchymal stem cells in enhancing bone regeneration. *Tissue Eng. Regen. Med.* 10: 18–24.
31. King GN, King N, Cruchley AT, Wozney JM, Hughes FJ. Recombinant human bone morphogenetic protein-2 promotes wound healing in rat periodontal fenestration defects. *J Dent Res* 1997; 76(8): 1460–70.
32. Huang KK, Shen C, Chiang CY, Hsieh YD, Fu E. Effects of bone morphogenetic protein-6 on periodontal wound healing in a fenestration defect of rats. *J Periodontol Res* 2005; 40(1): 1–10.
33. Arosarena O A, Falk A, Malmgren L, et al. 2003. Defect repair in the rat mandible with bone morphogenic proteins and marrow cells. *Arch. Facial Plast. Surg.* 5: 103–108.
34. Jiang X, Zhao J, Wang S, et al. 2009; Mandibular repair in rats with premineralized silk scaffolds and BMP-2 modified BMSCs. *Biomaterials* 30: 4522–4532.
35. Sandberg E, Dahlin C, Linde A. Bone regeneration by the osteopromotion technique using bioabsorbable membranes: an experimental study in rats. *J Oral Maxillofac Surg* 1993; 51:1106–1114.
36. Hirota M, Matsui Y, Mizuki N, et al. Combination with allogenic bone reduces early absorption of beta-tricalcium phosphate (betaTCP) and enhances the role as a bone regeneration scaffold. Experimental animal study in rat mandibular bone defects. *Dent Mater J* 2009; 28:153–161.
37. Deppe H, Stemberger A, Hillemanns M. Effects of osteopromotive and anti-infective membranes on bone regeneration: an experimental study in rat mandibular defects. *Int J Oral Maxillofac Implants* 2003; 18:369–376.
38. Dahlin C, Linde A, Gottlow J, Nyman S. Healing of bone defects by guided tissue regeneration. *Plast Reconstr Surg* 1988; 81:672–676.
39. Prolo DJ, Gutierrez RV, DeVine JS, Oklund SA. Clinical utility of allogeneic skull discs in human craniotomy. *Neurosurgery*. 1984 Feb;14(2):183–186.
40. Gomes, P.S. & Fernandes, M.H. Rodent models in bone-related research: the relevance of calvarial defects in the assessment of bone regeneration strategies. *Lab Anim* 2011;45: 14–24.
41. Bosch C, Melsen B, Vargervik K. Importance of the critical-size bone defect in testing bone-regenerating materials. *J Craniofac Surg* 1998; 9:310–16.
42. Viateau V, Logeart-Avramoglou D, Guillemain G, Petite H. Sourcebook of models for biomechanical research. In: Conn P, editor. *Animal models for bone tissue engineering purposes*. Totowa: Humana Press Inc; 2008. p. 725–35.

Sclerotherapy with polidocanol A conservative way for treating vascular malformation- A Case Report

* Sujith Johnes, **Shaju George, ***Ranjith Kalliath, ****Parvathi Jayagopalan

Abstract

Sclerotherapy is considered to be a best way of treating vascular malformations. We report a case of venous malformation of the left buccal mucosa which has

been conservatively treated with polidocanol sclerotherapy.

KDJ 2018 | Vol. 41 | No. 4 | Pg 212-213

► Introduction:

Vascular malformation is a generalized term used to describe a group of lesions present at birth formed by an anomaly of angiovascular or lymphovascular structures. They consist of various congenital vascular lesions ranging from simple skin discolorations to large devastating deformations.

The ISSVA classification system divides vascular anomalies into 2 (binary) primary biological categories: (1) vasoproliferative or vascular neoplasms (2) Vascular malformations

The major distinction between the two categories is

whether there is increased endothelial cell turnover, which is ultimately determined by the identification of mitoses seen on histopathology. Vascular malformations do not have increased endothelial cell turnover. Instead, vascular malformations are structural abnormalities of the capillary, venous, lymphatic, and arterial system that grow in proportion to the child^{1,2}. They are subdivided into 2 categories: (1) slow- or low-flow and (2) fast- or high-flow malformations. Low-flow malformations contain combinations of capillary, venous, and lymphatic components¹.

► Case report

A young female patient of 16 years of age reported to the

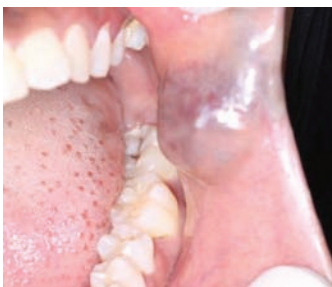

Fig. a

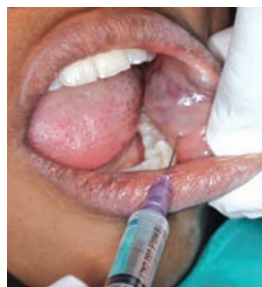

Fig. b

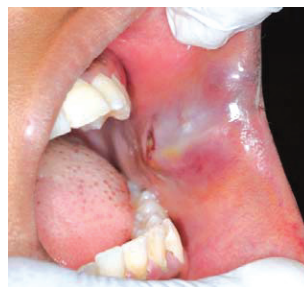

Fig. c

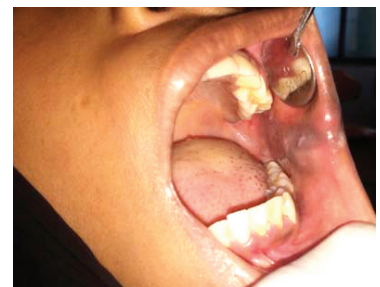

Fig. d

* Senior Lecturer, ** Professor and HOD, ***Professor, ****Senior Lecturer, Department of Oral and Maxillofacial Surgery, Royal Dental College, Palakkad.
• Corresponding Author: Dr. Sujith Johnes E-mail: sujithjohnes@gmail.com

Department of Oral and maxillofacial surgery as an outpatient with a chief complaint of a painless lump on the left cheek. The patient has been noticing the growth since 5 years. Apparently there was no significant change in size and it was not associated with bleeding or pain. Case history reveals absence of trauma prior to noticing the lump. On examination, a solitary dome shaped well-defined growth of size 1.5 x 2cm (Fig a) which is grayish blue in color was noted on the anterior aspect of buccal mucosa adjacent to left commissural region, surface of which appeared lobulated and non ulcerated.

The lesion was found to be soft in consistency, compressible, non-tender and non-pulsatile. Further investigation to obtain information regarding the feeding vessels of the lesion, a Color Doppler Ultra Sonography was done which revealed a small hypoechoic lesion measuring about 1.1 x .8 cm with no significant increase in the vascularity suggestive of a venous or venolymphatic malformation. Differential diagnosis can include Venous malformations, Lymphatic malformations, combined malformations like capillary- lymphatic malformation (CLM) and capillary lymphatic venous malformation (CLVM).

Sclerotherapy procedure was done using 3% polidocanol (Asklerol (3%/2ml vial)). Owing to its inherent local anesthetic action, prior administration of local anesthetic agent was not required. Totally 2ml of 3% polidocanol was injected around the entire perimeter of the lesion [fig b]. It was then followed by a manual compression for 3 to 5 minutes using sterile gauze. Patient was instructed to take analgesics and recalled after first and second week.

Post operative period of one week and two weeks shows considerable degree of the regression of the lesion [fig c,d].

► Discussion

Venous malformations are present at birth but not always apparent. They typically become more noticeable as the patient matures; enlarges steadily during puberty, plateaus during adulthood seldom undergoes spontaneous regression unlike hemangioma.³ Such characteristics stands true in the present case as patient started noticing the growth six years ago during which patient was probably at the age of puberty and ever since then the lesion has seldom undergone any change in its size.

Ultra Sonography is able to determine the basic type of lesion, direct initial management, and plan further imaging evaluation, For sonography to be a useful modality, it must include grayscale, color Doppler, and spectral Doppler tracings to evaluate vascularity and determine types of vessels present. Venous malformations appear as hypoechoic or heterogeneous

lesions in 80% of cases as is true in the present case.^{3,5}

The treatment goal should be to cure the venous malformation; however, cure may only be obtained in case of small, focal lesions. With proper treatment the venous malformations can shrink but will persist and re-expand when there is trauma and/or hormonal influence.^{6,7} Various methods have been used to treat venous malformations, including conservative treatment such as head position elevation, sclerotherapy, laser therapy, and surgery. Conservative treatment is primarily suitable for small, isolated, asymptomatic venous malformations. Other beneficial conservative treatments include local compression, anti-infection therapy, pain control, etc.⁷

Sclerotherapy has become the current mainstream treatment for venous malformation. It can be used as a single modality or can be combined with surgery and/or laser surgery. For large lesions, multiple treatments are necessary. Recurrence may occur in incompletely treated cases.⁷

Polidocanol, also known as lauromacrogol or aethoxysclerol (chemical name: lauryl alcohol polyoxyethylene), is a more moderate form of ethanol. It is an effective sclerosing agent that consists of 95% hydroxypolyethoxydodecane and 5% ethyl alcohol and is known to have a low risk of complications.⁷

► Conclusion

Small venous malformations can be effectively treated with sclerosing agent like polidocanol rather than surgical methods without much adverse effects and less rate of recurrence in our case can be seen.

► References

1. Vascular Malformations: Classification and Terminology the Radiologist Needs to Know Lowe, Lisa H. et al. *Seminars in Roentgenology*, 2011; (47)2: 106 – 117.
2. Mulliken JB, Glowacki J: Hemangiomas and vascular malformations in infants and children: A classification based on endothelial characteristics *PlastReconstrSurg*, 1982; 69: 412-422.
3. Mohan R, Dhillon M, Gill N. Intraoral venous malformation with phelboliths. *The Saudi Dental Journal* 2011; 23: 161-3.
4. Garzon, M.C., Huang, J.T., Enjolras, O., Frieden, I.J., 2007. Vascular malformations: part I. *J. Am. Acad. Dermatol.* 56(3): 353–370.
5. Dubois, J., Soulez, G., Oliva, V.L., Berthiaume, M.-J., Lapierre, C., Therasse, E., 2001. Soft-tissue venous malformations in adult patients: imaging and therapeutic issues. *Radiographics* 21(6): 1519–1531.
6. Venous malformations. *Int J ClinExp Med* 2013; 6(5): 377-389.
7. Puig S, Casati B, Staudenherz A, Paya K. Vascular low-flow malformations in children: current concepts for classification, Zheng et al. *Guidelines for the treatment of head and neck diagnosis and therapy. Eur J Radiol* 2005; 53: 35-45.

51st Kerala State Dental Conference



ida
Indian Dental Association
Kerala State

Venue : "The Calicut Trade Centre"

Date : 4th, 5th & 6th January 2019

HOST: IDA MALABAR

*Includes registration kit, inaugural dinner, banquet, two lunches, gifts, entry to scientific sessions and trade fair

**Includes registration kit, entry to scientific sessions and trade fair

***No certificate of participation, eligible for inaugural dinner, banquet, two lunches, entry to scientific sessions and trade fair

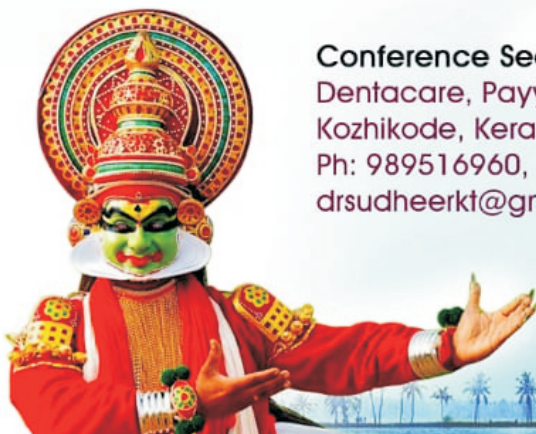Registration Details

Registration Type	Amount
Reception Committee Member	₹ 4,000.00 + GST = ₹ 4,720.00
Delegate**	₹ 1,300.00 + GST = ₹ 1,534.00
Accompanying persons***	₹ 2,600.00 + GST = ₹ 3,068.00
Children between 7-12 years***	₹ 1,750.00 + GST = ₹ 2,065.00

We accept



FOR ONLINE REGISTRATION VISIT
www.51ksdc.com



Conference Secretariat
Dentacare, Payyoli P.O
Kozhikode, Kerala-673522
Ph: 989516960, 0496-2600969
drsudheerkt@gmail.com



Association News

► CDE Report



Dr Anil Thunoli
Chairman CDE

Dear friends,

At the outset I thank the President, Secretary and all other colleagues of Indian Dental association Kerala state for the wonderful support and backup offered during my tenure this year as the CDE chairman of IDA Kerala.

This year we could conduct 8 state level CDE programs and more than 130 CDE programs at the local branch level. Kudos to the Presidents,

Secretaries and CDE Conveners of all the local branches for the hard work and effort in making the CDE programs successful.

The 7th state CDE program was held on 4th November 2018 at Hotel Kabani International, Muvattupuzha. Prof. Dr Suresh Sajjan took the class on troubleshooting in complete denture prosthesis. Lecture was followed by hands on and live demonstration on patient.

The 8th CDE program was held on November 11th at Hotel Ramada, Allepy. The topic was Dental Photography and the faculty was Dr Mayur Davade. It was a two days programme and the hands on was conducted on next day November 12th. Congratulations to IDA Malanadu branch and IDA Green Valley branch for hosting 7th CDE and IDA Alapuzha

and IDA Mavelikara branch for hosting 8th state CDE

"A Journey Through Orthodontics" on which the National level CDE was conducted on 17th and 18th of November at IMA House, Kochi. It was inaugurated by Dr Alias Thomas, past national president of IDA. The first day of program was enlightened by wonderful lectures by Dr Badri Thiruvengkatachari, Dr Akshay Rathi and Dr Binoy Ambooken. Second day's lectures were carried out by Dr Joby Peter, Dr Joseph Varghese, Dr Girish PV and Dr Sony Jacob. The program was well attended and very well appreciated by every one. Heartfelt gratitude to IDA Kochi branch for hosting it in a fabulous manner and a big thanks to head office especially Dr Ravindranath, National CDE Chairman for the opportunity given. The official launching of Biometric attendance maintenance system was done by Dr Ciju Paulose, President IDA Kerala at inaugural session of national CDE.

So at the fag end of this IDA year thanks once again to all my friends and fellow members who stood by me during my tenure as CDE Chairman. And I wish my successor the very best and offer my full fledged support.

Thanking you,
Your's in IDA

Dr Anil Thunoli



► CDH Report



Dr. Joby J Parappuram
Chairman, Council on Dental Health

Dear members,

It's time for the final bell and so is the time for the final report.

I would like to thank you all for giving me this opportunity to be the Chairman Council on Dental Health for the last one year. Because of your constant support we could do a lot of programs this year.

November was a busy month for all of us. So many state programs...

Even then all most all branches were going well with their CDH programs.

The main event in the month of November was Children's Day and World Diabetic day.

The state program was hosted by IDA Quilon. Lucky me... I got a chance to be with them on that day.

The first session was held at Jana Maithiri East Police Station in collaboration with ORC & CAP. The programme was inaugurated by Smt Ilakkiyya S Subcollector, Quilon & Guest of Honour Dr Suresh Kumar G -Hon.Sec.IDA KSB.

The second session was held at Balika Mandiram LP School, Karbala, Quilon from 12 pm-3.30pm in collaboration with DMOH Kollam for "students, parents & teachers of the school". The Chief Guest & other

dignitaries were warmly welcomed with a memorable welcome parade by the tiny tots of the school which was heart touching.

A car rally was organised from Jana Maithiri East Police Station to Balika Mariyam LP School Karbala, at 11.30 am. The car rally with the theme "More smiles per smiles", a wonderful event for public awareness on "Children's day & World Diabetes Day. More than ten doctors had participated in the rally. The event was flagged off by Sri Suresh Kumar - ASI East Police Station (in the absence of Sri. M.R Sathish Kumar ACP DCRB & Distal nodal Officer CAP). The events of the state programme were well covered in leading dailies like the Malayala Manorama Newspaper.

Other than this state program, many other branches like - Malanadu, Kodungalloor, Thrippunithura, Attingal have participated in making November 14 wonderful.

I take this opportunity to congratulate all the CDH chairmen, Presidents and Secretaries of all the branches to make this IDA year beautiful. I also thank Dr. Ciju A Paulose, Dr. Suresh Kumar G, Dr. Anjana, all other state office bearers, all executive committee members, my clinic staff, my wife- Dr. Jeni Merlin and my family for supporting me year through.

Have a Happy X Mas season and a prosperous new year. See you all at Milan...

Jai IDA

Dr. Joby J Parappuram



Dr Susha C N
WDC chairperson

WDC Report

Dr Anney George
WDC secretary



WDC TRIPUNITHURA

+Care for your teeth campaign: dental check ups with distribution of tooth pastes & brushes with brushing demo at the following Institutions: technique was taught to children. Samples of toothpaste and toothbrush were also provided.

As a part of CARE FOR YOUR TEETH Campaign IDA Tripunithura Women 's Wing conducted a dental check up for children of primary kindergarten school at Mekhara Tripunithura. Proper brushing technique was taught to children. Samples of toothpaste and toothbrush were also provided.

Primerry kindergarten school-Mekhara, Choice Kinderland-Girinagar, Celebrated National tooth brushing day with Children of Eurokids – Maradu & On International day of people with disability at Adharsh Rehabilitation centre.

+ World Food day: offered food for inmates of Pakalveedu - old age home

+Lecture on Oral Health & Diabetes for dental doctors on 28th November by Dr Sherin at Smile Care Dental Clinic

+Childrens day at Poornathrayeesa Balashramam,conducted painting competition & Healthy Smile competition with adoption of Institution.

WDC MALANADU

+ 23rd Oct: Conducted Dental check up camp, awareness class & distribution of dental kits at St.Pauls Old age home in association with Mar Baselious Dental College

+14 Nov: Coloring Competition of children at Diet lab,UP school

+27th Nov: 6th ECM & release of Official Bulletin by Dr Manesh Scharia

+30th Nov:Healthy Habits for a smiling future at Diet up school, by Dr Marilyn Alias

WDC PALAKKAD

+ 10th Oct: World Mental day: Dental awareness class by Dr Shabeena Sheikh at Malamuzha Voc.Higher Sec.School for autistic students with distribution of dental kits.

+16th Oct: World food day: Served lunch at Snehajwala old age home

+22nd Oct: Oral Screening camp at Sathya Seva Samithi

+14th Nov:Oral Screening camp at GLP School in assoc with Lions club

+16th Nov:Dental & Medical camp, in assoc. with womens wing of IMA, at Sree Sathya Sai baba school for 250 students

+19th Nov: State prog:Women empowerment class,Self defence demo (police officers -vanitha cell) & BLS classes at Chittur Govt. Victoria Girls Higher Sec.School, in the gracious presence of Dr Susha CN, Dr Sreekanth & Dr Venugopal

WDC CKK

Donated Rs 25,000 to a lady doctor, whose clinic had bee affected by the floods this August.

WDC NORTH MALABAR

+30th Sept: Dental Camp -organised by 7th mile Juma masjid

+11 th Nov: Childrens day Prog: Dental camp for 200 students-organised by Vivekananda Vidyalaya.

WDC QUILON

+27th Oct: State Prog: Seminar 'Rise, Walk & Conquer' for Nirbhaya Volunteers, Community Counselors & Mithra Womens Cell TKMC AS in assoc. with DLSA, DCPU, City Police & Kudumbasree Dist. Mission, Inaugurated by Smt. Mercykuttyamma –Hon'ble Minister of Fisheries, in the esteemed presence of Dr Abhilash GS-President Elect.

+6th Nov: 'Oral Health Month & National tooth brushing day': Counseling class & Dental Awareness Class for the inmates of CSI Bala Bhavan & CSI Balika Mandiram & free treatment adoption of Balika Mandiram Orphanage.



► Hope Report



Dr Deebu J Mathew
Vice Chairman, Legal cell of IDA HOPE

Dear friends and colleagues in the profession,

Greetings from the Legal cell of IDA HOPE, the flagship scheme for members of IDA KSB. As most of you would be aware IDA HOPE is the subcommittee of IDA Kerala state devoted entirely to the benefit of its member and it comprises of two divisions- One the social

security wing which provides the financial support to the member and the other wing being the Legal cell which extends support in the event that a member faces litigation during the course of his practice.

It is this component of HOPE - the legal cell which provides legal assistance and advice to any of its members in the unfortunate event that he or she becomes embroiled in a dispute which might reach a criminal, civil or consumer redressal forum. We assure that the best possible advice is given to a member in establishing the true scientific facts in the proper forums when an issue crops up. The legal cell plays an important role as many a time we are able to produce acclaimed academicians in the courts to provide impartial expert opinions on cases.

Crisis management more than often could help defuse a situation which could evolve into a potentially lengthy legal process and so it is imperative that members inform the local branch and the HOPE office whenever he or she is subject to a dispute involving patient treatment.

The other scenario is when a member receives a legal notice from a lawyer or a court summons. In such cases the legal cell takes up the matter as soon as all relevant documents pertaining to the patient treatment are submitted through the local branch office. More than often a proper studied reply to the legal notice will nip in the bud further legal proceedings. This reply is framed by legal experts along with the

expert opinions take from eminent academicians and practitioners in the field of dentistry.

In the unfortunate event that the patient or his legal counsel aren't satisfied with the reply then the matter becomes escalated to a litigation and here the entire burden of the legal proceedings will be overseen by the HOPE legal cell and timely interventions taken when and wherever necessary. The legal cell also ensures that expert witnesses are provided to clarify and establish the scientific arguments and medical and dental findings whenever required in court proceedings.

At this point allow me to STRESS ON the importance of

- Proper documentation of treatment procedures (case sheet records)
- Obtaining consent of patients before treatment
- Avoiding telephonic prescription
- Proper and clear communication with patients

All these if properly and systematically maintained will go a long way in avoiding legal entanglement.

Even if all safeguards and precautions are taken we never know what could happen and so it is always good in the better interest of our practice and livelihood to have HOPE coverage.

I take this opportunity to praise the efforts of all local branch Presidents, Secretaries and HOPE representatives, all members of the HOPE Management Committee, all members of the State Executive Committee, the past and present office bearers of IDA KSB and IDA HOPE and of course the members of IDA HOPE for the continued and unwavering support in keeping this fraternal support scheme at its best.

If you have any queries you could always write to me by e-mail to hopelegalcell@gmail.com and I could offer any assistance to the best of my ability

Thanking you in all sincerity

Dr Deebu J Mathew

► Wayanad Branch

A staff training programme 'AMAZING Assistants' was taken by Dr Civy V Pulayath at Kalpetta in May.

Conducted a family tour to yellow bamboo resorts, Gonikoppal in June.

Free denture distribution programme was conducted for the needy patients. 43 complete dentures were distributed.

Third state level CDE was conducted at Wynd valley resorts Kalpetta. Dr Joby Peter took class on early prevention of malocclusion and guiding the dentition.



Indian Dental Association, Wayanad District Branch
Conducted Free Denture Distribution Programme for Needy People
In Wayanad, Venue: Wynd Valley Resort, Kalpetta. On . 5.8.2018

► Palakkad Branch

World Mental Day: 2018 OCT 10

Project: Interactive sessions and dental awareness class to autistic pupils at Malamuzha Vocational Higher Sec School, Malamuzha.

World Food Day 2018 Oct 16

Project: Lunch with the inmates of Snehajwala Old Age Home at Kottekkad, Palakkad

Had a memorable and most valued moments with the inmates of Snehajwala. Most of us are already regular visitors at the centre. Visited all the rooms and served food to them. Truly homely food was served which was sponsored by WDC Palakkad.

Oral screening camp 2018 NOV 14th

Venue: GLP School, in Association with Lions Club Palakkad Fort Town

WDC conducted oral examination for the students, advised necessary treatment plans, distribution of medicines, referral for emergency conditions, oral hygiene instructions and an interactive session regarding all the doubts related to dental problems. More than 80 students were examined in detail

Oral screening camp 2018 NOV 16th

Venue: Sree Sathya Sai Baba Primary School, Koduvayur in association with Women's wing of IMA

It was a full day medical and dental examination session for 250 students. A group of dental and medical practitioners under single roof. Doctors from various departments like dermatology, ophthalmology, pediatrics and dental surgeons participated

CDE Activities

Two Half Day CDE programmes were conducted on the same day (28/10/2018) at Hotel ATS Grand Kera, Palakkad

(9.30 am- 12.30pm) 7th CDE Programme

Introduction to 3D imaging in General Dentistry by Dr Anu Sushanth MDS (Oral Medicine And Radiology)

8th CDE Programme (1.30pm- 4.30pm)

Periodontology in General Practise by Dr Ullas Menon MDS (Periodontology)

9th Inter branch 2 day CDE DENTA QUEST was conducted in the 10th and 11th of November 2018. It was a grand success with almost 182 members attending the 2 day programme.

A camp was conducted 300 students at Vallikode Aided School and was attended by: 1. Dr Vipin T P, 2. Dr Natheer, 3. Dr Deepak, 4. Dr Azham, 5. Dr Rineesh

PUBLICATIONS

Two issues of Dentale magazine for the month of September and the November published

WDC - IDA Palakkad State Program November 19th

After the sessions, pleasantries were distributed to the vanitha Police team and for the BLS TEAM along with tea and snacks. Our chief

guests sincerely acknowledged our efforts and enjoyed the sessions too.

The WDC Palakkad Team really had prestigious memorable moments which further enriched with the very simple and humble personalities like Dr.Susha, Dr.Sreekanth, Dr.Venugopal and the whole IDA Palakkad team.

WDC - IDA Palakkad State Program November 19th

Power Packed Vanitha Cell Team took a breath taking class about Women- safety and how to overcome critical situations which women have to face in the present scenario. Since it's a girl's school, students got a very well interactive sessions with full freedom, without any hesitation. Defense demo using our own body parts as a gadget in a more handy way was very beneficial for all of us. The vanitha cell team had distributed their cards which includes the help line numbers to all students and teachers.

Though BLS classes are a full day course our INSCOL Team brilliantly handled it to summarize in a few hours. They delivered a knowledge full class about vital signs and some first aids in an apparent way. Not only they gave a descriptive demo on CPR, but also made, the NSS students, to do the same on phantoms. Really the students also enjoyed the dynamic sessions.

WDC - IDA Palakkad State Program November 19th

November 19th was a magnificent day for WDC Palakkad Branch. We the WDC Palakkad Team felt privileged to host a state program at Chittur Govt Victoria Girls Higher sec School. The Program started out in two sessions.

1. Women empowerment awareness class and demo on defense by senior lady police officers of Vanitha Cell, District Police Office Palakkad.

2. Basic Life Support (BLS) by Team INSCOL, Detailed some basic ideas about first aid and demo on CCPR to NSS students

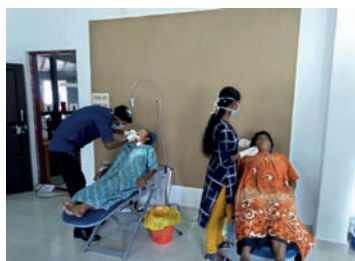

► Central Kerala -Kottayam Branch

Central Kerala Kottayam Branch conducted the Annual General Body Meeting on Dec 2, 2018 and New Epson projector was bought for the branch

CDH activity

Camp at Nalla Samarayan Orphanage, Thampalakkad, Kanjirappally.



► Coastal Malabar Branch

Executive committee meetings: conducted two executive committee meetings on 01/10/18 and 15/11/18.

Chilamboli: Our branch hosted the Chilamboli 2018, the cultural festival of IDA Kerala state on 11th November 2018 at hotel K K residency, payannur. The function was inaugurated by Mr. Gokul Suresh, Cine actor. Dr Ciju A Paulose, president IDA Kerala state presided over the function. 10 Branches including IDA Trivandrum, IDA Tiruvalla, IDA Malanadu, IDA Kochi, IDA Malabar, IDA Wayanad, IDA Tellicherry, IDA Vadakara, IDA North Malabar and our branch actively participated and IDA Coastal Malabar branch bagged the overall trophy and IDA Kochi was the 1st runner up and IDA North Malabar 2nd runner up. The programmes included a variety skit and cinematic dance and off stage events like pencil drawing, colouring and soap carving. The prizes were distributed by Dr. Sreehari G.K. and Miss Anaswara Rajan, cine artists.

CDE Activity:

11th CDE programme: conducted a 2 days endodontic workshop on 27th and 28th October 2018 at Hotel K K Residency, Payyannur. The faculty was Dr Madhu Hariharan, Assoc Prof, Dept of Conservative Dentistry, Amritha Dental College. 11 Members attended the hands on programme which included access cavity preparation, cleaning and shaping and obturation of extracted teeth.

CDH activities

1. Conducted a dental check up and awareness class for anganwadi kids in association with lions club of Trikaripur on 8th October 2018.
2. Conducted a dental check up and awareness class at EMS Mandiram, Puracherry in association with Kairali Swasraya Sangam on 14th October 2018.

3. Childrens day: conducted a dental check up and awareness class at Edanad west L.P school, Edat on 14th November 2018. Various competitions for childrens like best smile, healthy teeth were conducted and prizes distributed.

Donation to IDA Kerala State Disaster Relief Fund: Our branch donated Rs 1 lakh towards IDA Kerala state disaster relief fund and handed over the cheque to Dr Joby V Parappuram, state CDH chairman on 2nd October 2018 at Payyannur.

Dental cricket league: Our branch actively participated in the dental cricket league of IDA Kerala state on 20th and 21st October 2018 held at Kottayam.

Family activities: organized a special show of Kayamkulam Kochunni for our members on 18th October at Shanthi Cinemas, Payyannur.



► Mavelikkara Branch

IDA Mavelikkara celebrated Deepawali this year with colourful programs. As we are one of the most flood affected area we all celebrated Deepawali as not just a festival of lights, rather it was celebrated as our festival of hope and strength. Almost 100 families are gathered together at green valley convention centre Dr Anil John inaugurated the programme. Dr LALU MC and DR BESSY ANOOP presented a gazhal concert. followed by orchestra, dandiya and firework displays.

Anti tobacco programme. IDA Mavelikkara conducted an anti tobacco anti narcotic awareness programme for students in association

with the excise department at ALL SAINTS high school and junior college Adoor on 15th October 2018. School manager Fr Paul Nilackal presided the function. Shri Anto Antony MP inaugurated the function. Excise C I Mr K Mohanan gave message on harmful effects of tobacco and narcotics. Dr George Koshy explained the projects of IDA Mavelikkara against tobacco consumption among students. Awareness video on harmful effects of tobacco was also exhibited. Anti tobacco pamphlets were distributed.



► Attingal Branch

CDH:

Observed International Day for Elderly on October 1st at Chakkulathamma Sanjeevani Ashram Charitable Trust Old Age Home, Kilimanoor. Our CDH convenor Dr Roshith S Nath examined all the inmates and give awareness class and distributed tooth brushes and pastes.

Free Denture Programme:

CDH wing of IDA Attingal Branch along with Staffs and PGs, of Prosthodontic Department, of PMS Dental College and Research Centre conducted a Free Denture Programme on 8th November.

15 dentures fabricated, preliminary impression to denture delivery, in a single day.

Children's Day:

Observed on November 14th at Timekids School, Attingal. Conducted dental check up, took awareness class, distributed tooth brushes and pastes.

World Diabetes Day:

World Diabetes Day observed on November 14th.

Distributed pamphlets, gave awareness talk to the public at each main junctions from Kilimanoor to Pallickal.

CDE:

Our fifth CDE programme conducted on 4th November at Hotel Karthika Park, Kazhakutom.

Dr Yohan Chacko was the faculty. 53 members attended the programme.

TV talks:

Dr Premjith S and Dr Biju A Nair attended Doctors on line programme in Mangalam channel on 12th October and 9th November respectively.

Executive Committee Meetings:

We conducted three Executive Committee Meetings so far.



► Quilon Branch

October:

20th October: 6th Branch level CDE on “Management of Endodontic Instrument separation” by Dr Praveena G.

20th & 21st October: Participated in DCL, Kottayam

23rd October: 3rd ECM & EOGM for HO election

27th October: WDC State programme, inaug. by Smt. Mercykutty Amma- Hon'ble Minister of Fisheries in the gracious presence of Dr Abhilash G S –President Elect IDA KSB at TKM College in assoc. with DLSA, DCPU, Kudumbasree Dist. Mission, Kollam City Police & Mithra Womens Cell TKMC AS for Nirbhaya Volunteers, Community Counselors & Womens cell TKMC AS from 10 am -2.30 pm.

November:

3rd November: Awareness class, Dental screening camp for 60 boys in relevance to OHM & treatment adoption of Mannaniyya Umarul Farooq Yatheem Khana, Quilon by CDH wing

6th November: Medical & Dental camp & an educative class in relev. to OHM & Nat. Tooth brushing day for 84 children of CSI Bala Bhavan & CSI Balika Mandiram with treatment adoption of Bala Bhavan by CDH wing

Counseling class by Counselor & dental awareness class with treatment adoption of Balika Mandiram by WDC wing

11th November: Chilamboli: Attended by Dr Shibu Rajagopal past State Sec. & past State VP IDA KSB.

14th November: CDH State prog: “Childrens day & World Diabetes day”:

First Session: in collab. with ORC & CAP: Quiz & Paint. Compet. for SMART 40 students at Jana Maithiri East Police Station, Inaug.

by Smt. Ilakkiya- Sub Collector -Kollam & Dr Suresh Kumar G –Hon. Sec. IDA KSB in the gracious presence of Dr Joby J Parappuram CDH Convenor IDA KSB.

Second Session: at Balika Maryium LP School, inaug by Dr Suresh Kumar G & AEO Kollam in the gracious presence of Dr Joby J Parappuram. Teachers-parents orient.prog, Diab.day Pledge, Dental Camp, Med Camp, Free Bld sugar test, Anemia detect. Diab. neuro study, Dental Health Exhibition etc

Third Session: Car Rally from Jana Maithiri East Police Station –Balika Mariyam School, flagged off Sri Suresh Kumar-ASI East Police station

17th & 18th November: National CDE: Dr Sulfikar Ali, Dr Sundaresan, Dr Biju Kumar S D, Dr Ciju P Cherian, Dr Siju K Eapen, Dr Athira Baburaj, Dr Ajith R Pillai & Dr Anney George participated (8 members).

25th November: Interbranch Level CDE on “Diagnosis & Management of Oral Mucosal Lesions” by Dr Deepu George Mathew, Dr Jubin Thomas & Dr Renju M Kunjumon at The Vaidya Hotel, Qln.

28th November: 4th ECM

DECEMBER

2nd December: In Relev to “National Oral Cancer Day & State Project Paal Punchiri” for Anganwadi School children, helpers & workers across Qln Dist in Collab with ICDS Qln. & NSS unit TKMC AS, Inaug. by Sri M Noushad-MLA Quilon: Oral cancer talk, Teachers –Parents training by Dr Aswathy S & Dental Screening Camp were conducted.



► Nedumbassery Branch

1. Flood relief fund for immediate sanitation has distributed in the general body meeting.

2. Flood relief fund contribution to the state handed over to the state President during the State executive meeting held at Kochi.

3. Staff Training programme conducted with demonstration.

4. CDE for practice management conducted by Dr Civy.

5. CDE on Online marketing conducted by Dr Arun Jose

6. CDH activity oral awareness class and check up @Aluva Vidyadhiraja School

7. Branch Tour - 60 member sunset cruise was a memorable experience for members.



► Kunnamkulam Branch

IDA Kunnamkulam conducted 2 CDEs on October 18th and December 14th, and a Family Meet on November 4th.

Family Meet - 2018

Date- November 4th, 2018

Main Event- Donated a sum of Rs 10000/- each to six families directly affected in Kerala floods.

Venue- KR Residency

Time- 5.30p.m-10.30p.m

Chief Guest- Harinarayanan (Lyricist)

Participants-132

CDE by Dr Abdul Latheef

Date-October 18th, 2018



Topic - Creative Dentist For The 21st Century (Soft Skills In Dentistry).

Venue - KR Residency

Time- 7.30p.m -9.30p.m

Participants -36.

CDE by Dr M.A Vinod

Date- December 14th, 2018

Topic- 21 Key Factors for Non-Surgical re-treatment of RCT in your Office

Venue- KR Residency.

Time- 7.30p.m- 9.30p.m

Participants 41



► Kottarakkara Branch

1. Interbranch CDE on Clinical Orthodontic Diagnosis and Treatment Planning by Dr Benoy Ambookan on 30th September



jointly organised by IDA Kottarakara, Pathanamthitta & Mavelikara.

2.CDE on Biopsy Techniques an Update by Dr SUNJITH S on 10th November 2018.

3. Dental check up camp at settlement colony, Kuryottumala Punalur in association with Sathya sai trust on 18th November 2018

4.CDE on ORTHODONTICS ACROSS AGES by Dr VINEETH V T on 25th November 2018.

1. Dental camp at SVMHHS VENDAR

2. CDE on Sterilization and disinfection Practice-Fiction Versus Reality by Dr Mili James

3. Dental camp at St John's Residential School, Anchal

4. CDE on Space maintenance in Paediatric practice by Dr Sujo Mathew.



► Trivandrum Branch

1. CDH Activities

1. IDA Trivandrum CDH wing in association with Sri Satya Sai Seva Samithi conducted an oral screening camp on Thursday, Oct 25th at Valiyavila UPS, Thirumala, Trivandrum from 10am-1pm. 87 patients were examined.

2. IDA Trivandrum CDH wing in association with Sri Satya Sai Seva Samithi conducted dental checkup camp at Chandramangalam, Aanadu Nedumangad, Trivandrum on Sunday, Oct 28th from 10am-12pm. 35 patients were examined and were provided with tooth brushes and tooth pastes.

3. IDA Trivandrum CDH wing in association with Sri Satya Sai Seva Samithi conducted dental checkup camp and an oral hygiene class for 22 children and 7 teachers in Govt. UPS, Kunnukuzhy, Trivandrum on Tuesday, October 30th from 10am-12pm. A painting competition was held on the same day and prizes were given.

4. IDA Trivandrum CDH wing in association with Sri Satya Sai Seva Samithi conducted dental awareness class and dental checkup camp for 38 children and 6 teachers at Govt. LPS School, Nemom on Saturday Nov 3rd from 10am-12.30pm. A skit based on moral values and oral hygiene was played by the children and a drawing competition was also held and prizes were distributed.

5. IDA Trivandrum branch in association with Sri Satya Sai Medical wing conducted a dental checkup camp along with their medical camp on Sunday, Nov 11 that Vellar, Kovalam from 10am-1pm. 63 patients were examined.

6. IDA Trivandrum CDH wing conducted a mega dental camp on Sunday, Nov 11 at Okhi affected areas of Poonthura@St.Thomas Church from 9.30am-1pm. 230 patients were examined. All were provided with tooth brushes and tooth pastes.

2. CLINICAL CLUBS

1. The Eighth clinical club of IDA Trivandrum was held in IDA Hall, Innu apartments on Tuesday, Oct 9th from 8pm-9.30pm as case presentations by Dr.C.P.John and Dr.Krishnakumar on the topic Endodontics and cosmetic dentistry. 33 Members attended the session which was followed by dinner.

2. The Ninth Clinical club of IDA Trivandrum was held on Tuesday, Nov 11th from 8pm-9.30pm by Dr.C.P.John and Dr.Gins Paul as case presentations on the topic "Cosmetic dentistry-Full mouth rehabilitation" from 8pm-10pm. 38 members attended the session which was followed

by dinner.

3. CDE Programmes

1. The 8th CDE of IDA Trivandrum branch was held on Sunday, Oct 28th from 9.30am-5pm at Hotel Classic avenue by Dr.Jojo Kottoor M.D.S on the topic "Practical tips for endodontic success" followed by a live demo session.

4. EXECUTIVE COMMITTEE MEETINGS

1. The Eighth Executive committee meeting of IDA Trivandrum branch was held on Wednesday, Oct 31st at Hotel Residency towers from 8pm-9.30pm.

5. Women's Council Activities

1. IDA Trivandrum Women's Council

The Fifth meeting of the Women's Council of IDA Trivandrum was held on Sunday, Oct 21st from 4pm-5pm at IDA hall, Innu apartments.

Followed by a talk on the topic "Breast cancer awareness-what women needs to know"

By Dr.Reggi Jose, Medical Director, Snehitha Women's health foundation(Prof: Community Medicine, Gokulam Medical College).

24 Members attended the meeting which was followed by high tea.

6. Donation to IDA Disaster Relief fund

IDA Trivandrum branch donated Rs. 2,40,000 to the IDA Kerala State Disaster relief fund. The cheque for the amount was handed over to the IDA State Asst. Secy Dr.Krishnakumar on October 9th at IDA Hall, Innu apartments after the Clinical Club meeting.

7. Children's day observation

The childrens day Nov 14th was observed by IDA Trivandrum by donating 60 new born baby kits to new born babies in Govt. Women and Children Hospital, Thycaud, Trivandrum. Dr. Aseem H, Dr.Capt. Pramod and Dr.Preetha handed over the kits to Dr. Devika, Pediatrician of Women and Children Hospital.

8. IDA Kerala State Students Conference 2018

IDA Kerala State Students Conference-2018 hosted by IDA Trivandrum branch was held on Saturday, November 24th@Sarvodaya Vidyalaya, Trivandrum from 9am-5pm. Inauguration of the Conference was done by Dr.Ciju A. Paulose, President-IDA Kerala State. President Elect Dr.Abhilash.G.S., Vice President-Dr.Sangeeth K.Cheria, Hon. Secretary-Dr.Suresh Kumar &CDH Chairman-Dr.Joby.J.Parappuram attended the function.



► Tripunithura Branch

CDH:

1. IDA Tripunithura conducted a dental camp, as part of School dental programme, at Govt. north LPS Perumbalam, on 3 October. 2018. Samples of toothpaste were distributed.

2. As part of oral hygiene awareness our CDH conducted a camp at St. George LPS, Tripunithura.

3. As part of Snehaspasham 2018 we conducted a dental camp at Anjanaya Charitable Trust Old Age Home, Chembu on 31st October 2018.

CDE:

1. On October.6.2018 at Hotel Hill Palace, IDA Tripunithura conducted a CDE on Use of Soft Tissue Lasers in dental practice. The

faculty was Dr. Jaison Valiyakulangara.

2. A CDE on Panoramic Imaging - A wider view to taper diagnosis was conducted on November.2.2018 at Hotel Hill Palace, Tripunithura. The faculty was Dr. Aravind M.S.

Obituary:

Dr. Biju V. Jose (53 years) who was a member of IDA Tripunithura passed away on October.10.2018 and his funeral was conducted on October. 19. 2018 at St.George Cathedral, Karingachira.



► Malanadu Branch

CDE Programs:

04-11-2018: State CDE on "trouble shooting in complete denture prosthesis" was held at Hotel Kabana, Muvattupuzha

05-11-2018: CDE on "Balanced occlusion in complete denture" was held at Mar Baselious dental college, Kothamangalam

24-11-2018: CDE & workshop on "Dentart Esthetics" was held at Hotel Kabani, Muvattupuzha

25-11-2018: CDE & workshop on "Dentart Esthetics" was held at Hotel Kabani, Muvattupuzha

27-11-2018: CDE of "influence of antibiotics in dental infections" was held at hotel Kabana, Muvattupuzha

29-11-2018: CDE on "Comprehensive basic endodontics for general practitioners" was held at A.V Hall of Dr Kurians multispeciality clinic, Muvattupuzha

CDH Programs:

21-10-2018: IDA Malanadu in association with Indira Gandhi dental college, Kothamangalam & Thrikalathoor St George Youth association conducted dental camp at SCM Hall, Thrikakathoor

23-11-2018: IDA Malanadu in association with Mar Baselious dental college, Kothamangalam conducted dental camp at St Paul's Old age home, Odakalli

24-10-2018: IDA Malanadu conducted dental awareness camp for Anganwadi teachers of Vengoor panchayath. Dental awareness classes were conducted by Dr Terry Thomas, President, IDA Malanadu. Around 350 dental kits were distributed to the anganwadi children of Vengoor panchayath.

29-10-2018: IDA Malanadu conducted dental awareness camp at Govt Higher Secondary School, Kadayiruppu. Dental awareness class was conducted by Dr Ninan Thomas.

07-11-2018: IDA Malanadu in association with Mar Baselious dental college, Kothamangalam conducted dental camp at Swanthanam buds school, Odakalli,

18-11-2018: IDA Malanadu in association with Mar Baselious dental college, Kothamangalam conducted dental camp at Mathrika Residents Association, Chittor, Thodupuzha

EXECUTIVE MEETINGS:

23-10-018: 8th Executive meeting of IDA Malanadu was held at Parappuram guest house, Muvattupuzha

06-11-2018: 9th Executive meeting of IDA Malanadu was held at Chinnas Auditorium, Koothatkulam

PUBLICATION (JOURNAL RELEASE):

27-11-2018: 4th Edition of Malanadu Dental journal was released in presence of state President Dr Ciju A Paulose 1st Bulletin of IDA Malanadu was released by Dr Alias Thomas, Past National president 2nd Bulletin

was released by Dr Joby J Parappuram, CDH Chairman, IDA KSB. WDC Bulletin of IDA Malanadu was released by Dr Manish Scharia.

SPECIAL DAYS:

14-11-2018: World Diabetes day was observed in association with Sanjoe Hospital, Perumbavoor. Diabetic awareness classes, diabetes and poor oral concerns and stress management in diabetes classes were conducted. Dental kit distribution was done at the hospital.

14-11-2018: Children's day was celebrated at three places

Children's day celebration week at Mar Baselious dental college, e-poster competition and collage for students and drawing competition for pediatric patients in dept of pedodontics

Colouring competition for anganwadi children of Okkal panchayath

Colouring completion for children was conducted at Surabhi Nagar resident association, Kakkanad.

WDC Activities:

23-10-2018: WDC of IDA Malanadu in association with Mar Baselious Dental College, Kothamangalam conducted dental camp at St Paul's Old age home, Odakalli

27-11-2018: 6th executive meeting of WDC of IDA Malanadu was held at Hotel Kabani, Muvattupuzha

27-11-2018: Official Bulletin of WDC of IDA Malanadu was released by Dr Manesh Scharia

29-11-2018: Colouring competition for children at DIET lab U.P School and health talk on "Healthy Habits for a Smiling future" was conducted by Dr Marilyn Alias

BRANCH ACHIEVEMENTS

04-11-2018: IDA Malanadu in association with IDA Green valley conducted state CDE on "Trouble shooting in complete denture prosthesis"

25-11-2018: IDA Malanadu was proud to Host IDA Kerala State sports meet "SPARK 2018" at Village International School, Thodupuzha

Student Activity:

01-11-2018:

"INTELLECTUALS" intercollegiate scientific presentation competition- paper presentation review, presentation case report, e – poster presentation

02-11-2018: Inter college debate & quiz competition for under graduate and post graduate students

14-11-2018: Children's day celebration week at Mar Baselious Dental College, E-poster competition and collage for students and drawing competition for pediatric patients in dept of Pedodontics.



► Malabar Branch

1, Sixth State CDE: 12th CDE of Malabar branch and 6th State CDE was hosted by IDA Malabar branch and was conducted on 07/10/18 at Hotel Maharani Kozhikode. Dr. Anil Thunoli CDE Chairman IDA Kerala State welcome the gathering, Dr. Ranvindrath National CDE Chairman was the Chief guest. Faculty of the CDE was Dr. Mili James and Dr. Eapen Thomas. 92 members participated

2, Release of Third Edition of Malabar Dentist: Third edition of Malabar Dentist, the journal of IDA Malabar was released on 07/10/18 at Hotel Maharani. Dr. Ravindranath National CDE Chairman released the Journal in the presence of Dr. Mehul R Mahesh, Dr. Anil Thunoli and many other dignitaries.

3, Dental Checkup Camp: IDA Malabar in association with youngstar club conducted dental Checkup camp, awareness class and distribution of dental health kit at GLP School Odiyathoor. Around 120 patients were examined, on behalf of IDA Malabar branch Dr. Ahmed Shafi, Dr. Junaid and Dr. Shabanna participated.

4, Interaction and Motivation to NEET MDS 2019 entrance aspirants: IDA Malabar branch President Dr. Mehul R Mahesh and IPP Dr. Binu Purushothaman had an interaction with Neet MDS 2019 entrance aspirants at our own IDA – Focus entrance coaching classes.

5, Dr. Sharafudheen Memorial Cricket Tournament (Branch level): IDA Malabar in association with GDC Alumni Association conducted Dr. Sharafudheen Memorial 2nd cricket tournament at Calicut Medical College Ground. Four teams participated, team Milan won the trophy.

6, Participation in IDA Kerala State Cricket Tournament: IDA Malabar branch cricket team 'Team Milan' participated in the two day cricket tournament held at Kottayam and reached semi finals. 15 members squad participated the tournament.

8, IDA KERALA STATE – ASAP – TRAINERS TRAINING PROGRAMME: Two day ASAP Training of Trainers programme was conducted by IDA Kerala State on 15th and 16th October at Hotel Marina Residency Kozhikode hosted by IDA Malabar branch. 28 registered trainers participated.

7, Thirteenth CDE (Half Day CDE & Live Demo): Thirteenth CDE of IDA Malabar branch was conducted on 28/10/18 at Hotel Maharani Kozhikode. The Faculty of the CDE was Dr. Anandakrishna MDS from Chennai. Topic of the CDE was Innovative Paradigms in Prosthetic Rehabilitation.. 75 members participated.

8, Family Get Together: IDA Malabar branch conducted family get together on 04/11/18 at Rennai Kappad Beach Resort at Kappad. Programme started at 10:30 am followed by many fun games, variety entertainments and lunch. 52 members along with their kids and family participated.

9, Participation in Chilamboli 2019: IDA Malabar branch participated in IDA Kerala State Cultural fest Chilamboli 2019 held at Payyanur on 11/11/2018. 15 members team from Malabar branch

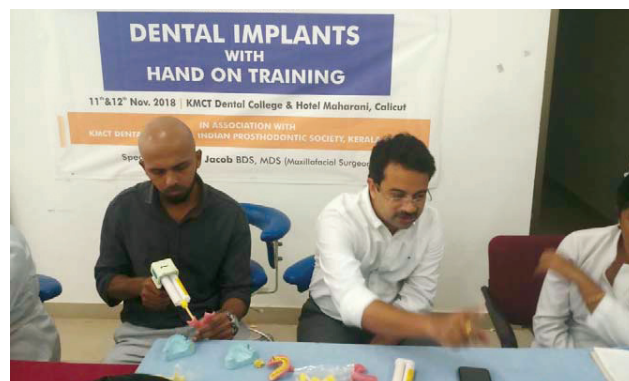participated and won many trophies.

10, Fourteenth CDE on Dental Implants (Two Day CDE with Hands On): IDA Malabar branch in association with KMCT Dental College and Indian Prosthodontic Society Kerala State conducted a two day CDE Programme on 11th and 12th November at Hotel Maharani and KMCT Dental College. The Faculty for the CDE was Dr. Sony Jacob MDS. The theory and Lecture was taken on 1st day which includes Introduction to Implantology, difference between implant and tooth, Analyzing bone radiographically OPG & CBCT. Second day includes hands on implant placement, Components and instruments, impression procedures and infection control, which was done in KMCT dental College.

11, Children's Day Celebration. On Children's day IDA Malabar Conducted an awareness class and dental health kits were distributed for the students and parents of Asha Kiran School, an Institute for differently abled students. Also a drawing and painting Competitions were conducted for the students of Asha Kiran. Asst Education Officer Kozhikode Smt. Lalitha inaugurated the programme. Dr. Jaseem Asst Professor Dept of Pedodontics Govt Dental college Kozhikode took the awareness class. A Cheque of Rs.10000/- was handed over to Principal Asha Kiran.

12, Branch Level Shuttle Badminton Tournament & Indoor Games: IDA Malabar branch conducted branch level shuttle tournament and indoor games including Caroms and Chess for its members, spouse and kids on 23/11/18 at Indoor Stadium Kozhikode.

13, Fifteenth CDE on Mindful Dentistry: Fifteenth CDE of IDA Malabar branch on Mindful Dentistry was conducted on 25/11/2018 at Hotel Marina Residency Kozhikode.



► Pathanamthitta Branch

13-10-2018 WOMEN'S WING Dine Together

Organized family dinner meet on 13th October 2018 at Hotel Hills park, Pathanamthitta.

Dr.Sujith P R presided over the meeting. The discussions about family tour to Nainital was taken in the meet.

18-10-2018 FAMILY TOUR Nainital

Organised family tour to the glittering jewel in the Himalayan necklace- Nainital, popularly known as the lake district of India and is situated in Uttarakhand. We started our journey from Nedumbassery airport on 18th October and reached Delhi. From Delhi, it took 300kms, a six hour journey to Nainital by bus which was a fabulous experience. We got an opportunity to visit the CORBETT, which is a perfect place for nature enthusiasts and wildlife lovers. The popularity of this place is the captivating landscape for the delight of nature lovers.

29-10-2018 EXECUTIVE COMMITTEE MEETING

The 4th executive committee meeting of the branch was held at Hotel Hills Park, Pathanamthitta on 29th October 2018. Dr.Sujith P R presided the meeting. Had full attendance for the meeting. Agenda: Minutes of previous meeting, Report, Election 2019, Programme planning (three months), Accounts, Tour, IDA HOPE, ASAP, any other matter with prior permission to chair.

4-11-2018 CDH- Oral Health Screening Camp

Organised oral health screening camp as part of IDA- CHILDLINE project Naleyude Nirapunchirikal at SC Pre metric hostel, Ranni. Dr.Sujith P R presided the meeting. The camp was conducted under

the supervision of Dr. Binu Chacko, Dr. Ralu Varghese. 48 inmates were benefited by the programme

18-11-2018 CDE Programme

The sixth CDE Programme Core Life Support- CPR Workshop was conducted on 18th November Sunday at Parayil Hotel, Pathanamthitta. Dr.Sujith P R presided over the meeting. IPP Dr.Hema Rajesh welcomed the faculty team and participants. CDE Chairperson Dr.Anita Markose introduced the faculty team. The workshop was taken by Indian Institute of Emergency Medical Services, Kottayam. The workshop was interesting and informative. The faculty team communicated things in a class way.

25-11-2018 GENTLEMEN'S TOUR

Organised one day Gentlemen's Tour on 25th November 2018 to Kavalam, located on the borders of Alappuzha and Kottayam districts on the banks of Vembanadlake. Its natural scenic beauty is legendary. What makes Kavalam unique is its vast "watery junction" that joins five canals at one place unlike other road junctions. The fun filled trip combined with awesome food and boating. The programme was very enjoyable to all participants.

26-11-2018 CDH – Oral Health for Overall Health

Conducted Oral Health Check up and Awareness programme at Govt. UP School, Panniyali, Omalloor, Pathanamthitta on 26th November 2018. Dr.Anita Markose, Dr.Ralu Varghese, Dr.Sujith P R, Dr. Revathy were participated in the camp. Dr.Dhanya Krishnan took Awareness Class. Dental kits were also distributed during the programme. 86 students were benefitted by the programme.



► Eranad Branch

IDA Eranad won the IDA KERALA state dental cricket league

IDA Eranad conducted clinical assistants training programme by Dr Civy V Pulayath on 14th October at hotel Rose, Nilambur. 105 dental Assistant participated.

6th CDE of IDA Eranad on Nov 04 th, by Dr.Jojo Kottoor on the topic of BEYOND ENDODONTICS. 78 members attended the CDE and 26 attended the Hands-on session.

