



KDJ

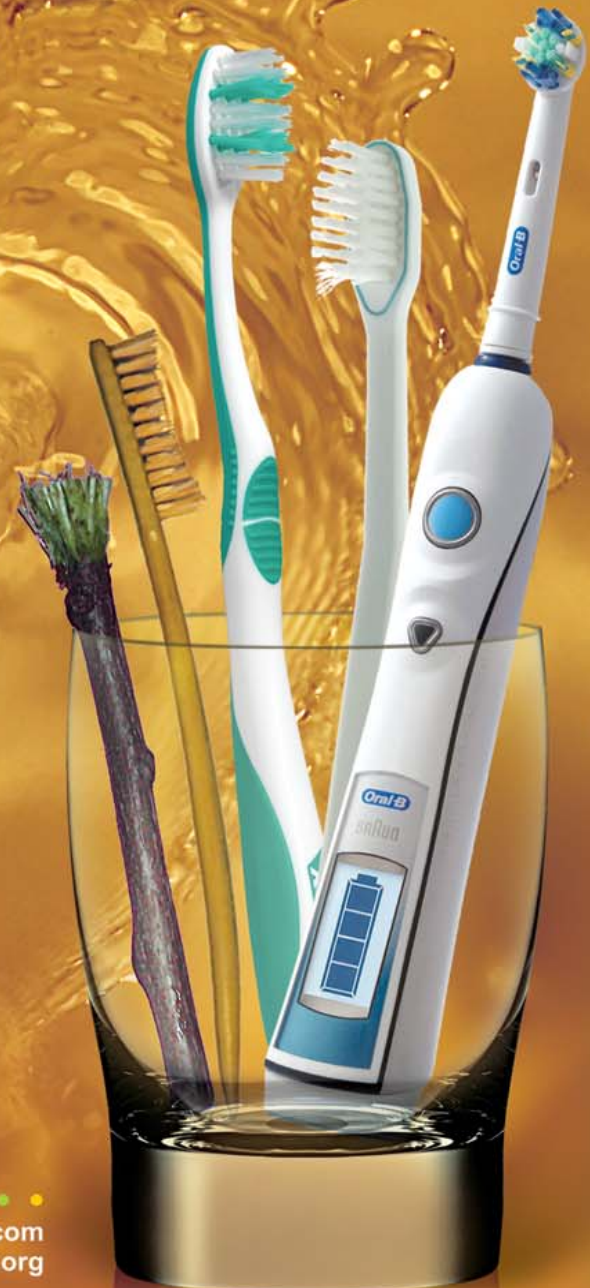Kerala Dental Journal

Quarterly Publication of Indian Dental Association, Kerala State Branch

Vol 32 | No. 3

July 2009

- *Guest Article*
Restorative materials
- **Effect of selected food items on the tarnish and corrosion resistance of alloys used in dentistry**
- **Peripheral cemento ossifying fibroma**
- **Management of oral lichen planus**
- **Three rooted mandibular first molar with four canals**
- **Rehabilitation of advanced endo-perio lesions**
- **Soft tissue management during second stage implant surgery**
- **Diagnose**
- **Quiz**



Email: editorkdj@gmail.com
Web: www.idakerala.org



President's Message	126
Editorial	127
Current status of dental materials research in SCTIMST, Trivandrum Bhuvaneshwar G.S.	129
Current status of dental materials research in SCTIMST, Trivandrum Part I: Restorative materials Lizymol P.P. and Kalliyana Krishnan V.	130
Effect of selected food items on the tarnish and corrosion resistance of alloys used in dentistry Manikya Arabolu	135
Anaphylaxis-A Fatal Medical Emergency Venugopalan P.P.	137
Peripheral cemento ossifying fibroma Sunil S.	141
Management of oral lichen planus Shilpashree S.	144
Three rooted mandibular first molar with four canals Abhishek Parolia	147
Myiasis Anjana Ravindran	150
Rehabilitation of advanced endo-perio lesions Hegde Deepak Divakar	152
Prosthetic rehabilitation of facial defect with silicone prosthesis Manju V.	154
Soft tissue management during second stage implant surgery Dipen Shah	156
Forensic dentistry Kalwa Pavankumar	159
Research Findings Bindu R. Nayar	161
Diagnose the following case Rani Mol P., Girija K.L., Tinky Bose, Anita Balan	162
Quiz Rani Mol P., Anita Balan	163
Secretary's Report and Association News	165

President's Message



Dr. K.N. Pratap Kumar

Dear colleagues,

Hope this issue finds you all in the best of health and spirits. This is indeed a great pleasure to communicate you all through this column. Summer is here again. I, with my cabinet colleagues are working fervently to make our IDA year a memorable one. The presence of our association is becoming more popular and meaningful in our state. I am indeed thrilled and proud to inform you that now we are in the TC and Health Record of Kerala Government NRHM Project. 'Minus to plus 2' programs to be implemented this academic year. This year's project 'Prabudha Keralam' is under way. Several branches have conducted their own programs under 'prabudha keralam' and is being coordinated by the CDH wing. As the first step, oral cancer week was observed state wide rendering free check up and references being made to major centers for further free treatment and follow ups. The importance of early diagnosis and detection of oral cancer is stressed up on enough. I had the unstinted support from the office bearers of state and local branch level to give utmost care for every event that is being implemented. The encouragement I received from several of my colleagues gave me inspiration, hope and courage to execute and delegate projects and programs. Our association maintains a high level of social obligation and commitment to the society in a glorified manner. I could witness the activities of CDH projects and CDE programs which were under taken had gained recognitions from within and outside the association. The Presidents, Secretaries and office bearers of all the 27 branches have done extremely well. I feel proud to congratulate each and every one of you to maintain our UNITY.

Individuals and organizations that have a selfish attitude have no right to expect growth. Greed always wants more. Needs can be satisfied, but greed can't. It is a cancer of the soul. Greed destroys relationship. The way out of greed is to learn to live within your means and be satisfied. Being content does not mean lack of ambition. One of the important secrets to success, what I have learned from my experience is that instead of being against something, be for something. That way you don't become a part of the problem, but part of the solution. Hard work is both a beginning and an end in itself. The harder the person works, the better he feels, and the better he feels, the harder he works. The best ideas will not work, unless you work the ideas. We need to learn from the nature. The duck keeps paddling relentlessly underneath but appears smooth and calm on the top. Nature gives birds their food but doesn't put it in their nests. They have to work hard for it. Nothing comes easily. Even small accomplishments require hard work.

Live your dream. But you can't live your dream at the expense of others. We need to make personal sacrifices for our family, friends, organizations those we care about and 'who depend' on us.

"The best insurance for tomorrow is a job well done today". Learn to excel in life and in profession.

With regards, love, and best wishes
Yours in IDA

Dr. K.N. Pratap Kumar
President IDA Kerala State

Strengthen the relations

Getting admission to a professional college for the son or daughter is a dream of any parent in Kerala. To realise the dream, parents would go to any extent of sacrifice. A parent belonging to a middle class family feels the future of the son or daughter secured, if admitted to a professional college. The real nature of the professional course and its future is never weighed while seeking admission. A professional student if not completing the course, is generally considered as a great failure. If a student decides to end his life – whatever be the reason – it becomes a disaster, at least to that family. Always such incidents provoke a blame game with copious addition of drama provided by the media. Media is interested only in the short term sensation; afterwards everything is forgotten. We must seriously think of the solutions which would effectively stop such an incident to recur.

Amongst youngsters, tendency to commit suicide is becoming prevalent due to stiff competition, advanced syllabus, changing trends in social and moral values, mixed negative feelings and fear of losing self esteem- seen especially among the urban middle class. At present the growing suicidal tendency in India is more among the adolescent students of secondary level, students of IIT and medical sciences. Some of the studies have shown that 35% of students have problems with career, 22 % with relationships, 16 per cent with family, 12 % with examination stress and 15% remained indifferent. 55 % students who took a decision to put an end to their lives took the responsibility upon themselves, 34 % of students blamed the present educational system and others passed the responsibility to parents, friends and teachers.

Youngsters relish in experimenting, experiencing and expanding. They need help and guidance in decision-making, problem solving, critical thinking, developing interpersonal skills, self-awareness, empathy, coping with stress and managing emotions. But the teenagers do not relish the idea of help and guidance from parents and teachers. This may not always be true. Beneath the frequent violent outbursts, sudden mood swings and related interpersonal problems of a youngster, there may be a person inside him crying out for help. The solution is to have effective communication among the student, parent and teacher. Parents think that his job is over as the son is in a professional college. Teachers think that their job is over once they teach the subject. Parents should know that there is a reason for taking disciplinary action against the student. Teachers should also convince the student on the reasons for disciplining. Whenever the student feels disappointed and seems to be at a loss to confide in parents or teachers, he may take drastic steps. Timely intervention of a counselor may save many precious lives. We should all look beyond our roles and build the golden triangle connecting the students, teachers and parents. Youngsters are precious because future of our profession rests with them. Life is there to live and no one has the right to put an end to it.



Dr. K. Nandakumar



EDITOR

Dr. K. Nandakumar

ASST. EDITOR

Dr. R.M. Baiju

BUSINESS MANAGER

Dr. Mathew Jose

EDITORIAL CONSULTANTS

Dr. Santhosh Sreedhar
Dr. K. Chandrasekharan Nair
Dr. K. George Varghese
Dr. Ipe Varghese
Dr. Oommen Aju Jacob
Dr. Thomas Manjooran
Dr. N.O. Varghese
Dr. Sobha Kuriakose
Dr. T. Sreelal
Dr. Siby Xavier

EX-OFFICIO MEMBERS

Dr. K.N. Pratap Kumar
Dr. Antony Thomas
Dr. C.K. Ashokan
Dr. Samuel K. Ninan

EDITORIAL BOARD

Dr. Anita Balan
Dr. Sreela Jayakumar
Dr. Twinkle S. Prasad
Dr. K.S. Ravindran Nair
Dr. Sooraj
Dr. Ajith Kumar
Dr. V.T. Beena
Dr. Bindu J. Nair
Dr. Hari
Dr. Bindu R. Nayar
Dr. Arun Sadasivan
Dr. Anil Mathew
Dr. P.A. Murukan
Dr. Pradeep Dethan
Dr. Eldo Koshy
Dr. Sheela Sreedharan
Dr. M.S. Suchitra
Dr. V.P. Kannan
Dr. Vinod Krishnan
Dr. Benoy Kurian
Dr. Joseph Issac
Dr. V.G. Sam Joseph
Dr. V.I. Paul
Dr. Gibi Paul
Dr. Manju Renjith
Dr. Jayakrishnan

EDITORIAL OFFICE

Neelambikam, Attukal, Manacaud
Trivandrum, Kerala - 695 009
Phone: 0471-2459235
Mobile: 09447066100
e-mail: editorkdj@gmail.com
web: www.idakerala.org

**OFFICE BEARERS OF
IDA KERALA STATE**

PRESIDENT

Dr. K.N. Pratap Kumar

IMM. PAST PRESIDENT

Dr. C.K. Ashokan

PRESIDENT ELECT

Dr. Samuel K. Ninan

VICE PRESIDENTS

Dr. Jaibin George
Dr. Sony Thomas
Dr. Santhosh Sreedhar

HON. SECRETARY

Dr. Antony Thomas

JOINT SECRETARY

Dr. C.C. Joseph

ASST. SECRETARY

Dr. S.Narayanan

TREASURER

Dr. K.S. Ravindran Nair

EDITOR

Dr. K. Nandakumar

CDE CONVENOR

Dr. O.V. Sanal

CDH CONVENOR

Dr. G. Anil



The early history and evolution of the toothbrush has its origin in the "chewingsticks" used by the Babylonians as early as 3500 BC. Chew stick was about the size of a pencil. One end was chewed into and became softened and brush-like while the opposite end was pointed and used as a pick to clean food and debris from between the teeth. The twigs used belonged to aromatic trees that had the ability to clean and freshen the mouth. The earliest literature showing the use of these twigs is found in Chinese literature at around 1600 BC. The toothbrush was first invented by the Chinese in the XVth century and brought back to Europe by travellers. This toothbrush was made of hairs from the neck of a Siberian wild boar which were fixed to a bamboo or bone handle. The people, found the wild boar hair too stiff and preferred horse hair, which was softer. Animal hair was popular until nylon was invented, in the XXth century. Mass-production was started by William Addis of England. Handles were carved out of the bone of cattle and the heads of the natural bristles were placed in the bored holes made in the bone and kept in place by thin wire. The first American to patent a toothbrush was H. N. Wadsworth in 1857.

In 1937, in the Du Pont laboratories in Nemours, U.S., nylon was invented by Wallace H. Carothers. In 1938, this new material became a symbol of modernism and prosperity through the commercialization of nylon stockings and of Dr. West's miracle toothbrush with nylon bristles.

The first real electric toothbrush was produced in 1939 and was developed in Switzerland. The electrical toothbrush was first marketed in the United States in 1960 by Squibb. The brush was called the Broxodent. General Electric introduced a rechargeable cordless toothbrush in 1961. Interplak was the first rotary action electrical toothbrush for home use, introduced in 1987.

Edited by
Dr. K. Nandakumar
Hon. Editor

Published By:
Dr. Antony Thomas
Hon Secretary

**For Indian Dental Association
Kerala State Branch**

Production : **Suman Graphics**
sumangfx@gmail.com

**Winner of the Best State Branch
Journal Award at the
National Level
2005-06, 2006-07 & 2007-08**

For Private Circulation only

Current status of dental materials research in SCTIMST, Trivandrum

*G.S. Bhuvaneshwar

Foreword

Dental products account for 30-35% of the total medical devices sold in the country and the dental market is valued at around 446 million US \$ annually (around Rs. 2230 crores). Growth rates of 15 to 20% are forecast for this market in the coming years. Unfortunately 80-85% of the devices are imported and the indigenous production is limited to a few items such as amalgams, dental cements and some equipments. As a result of this and also due the generally high cost of the imported products, there has been a consistent demand for developing indigenous products, which can help bring down the prices and reduce the cost of dental care. With this objective in mind, Sree Chitra Tirunal Institute for Medical Sciences & Technology undertook the development of dental products as early as 1990 and over the period of 20 years has come out with a number of technologies, which have been transferred to industry and the products put into the market. The objectives of this program were two fold a) to make available to the public quality proven dental products comparable with best imported ones and b) to make them available at an affordable cost so that the dental treatment, which was a luxury for many, will become more affordable to many more.

India has a middle class population of nearly 200-220 million with a strong purchasing power, who place a premium on good health. Over the last decade, they have attached increasing importance to healthy teeth and dental cosmetics. This segment constitutes the main customer base for the growing dental industry today. A rough estimate indicates that India has at least 40,000 practicing dentists of whom nearly 70% are located in metropolitan cities. Recent estimates show that at least 270 institutes offer dentistry qualifications for some 80,000 dental students in India and they require high-grade equipment and quality dental products.

The Dental Products Lab in the Biomedical Technology Wing of the Institute has successfully developed a number of products for restorative and orthodontic treatments. Many of these have been transferred to industry. Anabond-Stedman Ltd., Chennai successfully commercialized the first group of technologies they received from the Institute for restorative composites and placed them on the market under the brand name 'Restofill' followed by bonding agents 'Stedbond' and 'Stedbond-S'. Both self-cure and radiopaque light cure composites have been developed. Recently the technology for a new caries-dissolving agent has also been transferred to industry, for which, clinical evaluation is presently ongoing.

The Bioceramics Lab successfully developed a series of hydroxyapatite and hydroxyapatite-bioglass composite and these have been commercialized and placed on the market by the industrial partners under the brand names of 'Periobone-G' and 'Grabio-Glascera'. These technologies were developed for periodontal treatment and they have also been successfully commercialized.

These developmental activities have been well supported by leading dental clinicians in the region. The Institute is grateful to all these clinicians and students, especially the faculty from Trivandrum Dental College, who have actively provided clinical inputs and have extended support for clinical evaluation of these products.

Developmental activities are continuing in the Biomedical Technology wing of the Institute in the areas of polymers, ceramics and metals to develop novel new products, which will cater to the needs of the dental community. In addition, these laboratories are extremely well equipped for dental material testing. Some of these equipments are micro computerized tomography unit for 2D and 3D morphometric analysis, which finds wide applications in marginal leakage and dental caries evaluation, FT-Raman spectrometer, dental thermocycler, two and three body wear testers, micro-FTIR for the infrared analysis of microscopic sections, X-ray diffractometer for crystalline phase determination, mercury porosimeter for finding pore size, atomic emission (ICP) spectrometer for trace element analysis, transmission electron microscope and scanning electron microscope (including the Environmental SEM). Moreover a large number of dental student communities are benefited through extension of the testing services, carrying out postgraduate projects etc. Workshops and hands-on-courses are conducted in the Institute for the benefit of dental community. It is expected that by 2020, at least 50% of the dental material market in India would be met by products developed from indigenous technologies.

The first article deals with the state of art in restorative materials, their advantages and disadvantages. Activities of Dental Products Laboratory of SCTIMST during the last two decades in their thrust for the indigenous development of various restorative materials, various steps in composite preparation, their characterization, chemistry of glass ionomer cements, various facilities currently available for dental materials evaluation and the details regarding the various products available in the market based on technologies developed are highlighted.

The second article reviews various kinds of bone graft materials, synthetic as well as natural, which are in use in dental and oral surgery. Recent developments in the area of bioactive glasses, glass-ceramics, bioactive composites and cements are reviewed and discussed in detail. In the latter section, the article covers the successful developments of many of these products at the Bioceramics Laboratory of SCTIMST and the current on-going research.

References

1. FDI Market Overview from the FDI Meeting 2004 in New Delhi, India
2. Market Study by Consulimus AG, December 2006
3. Global Markets GMD ME0088ICR April 2008

* Head, Biomedical Technology Wing
Sree Chitra Tirunal Institute for Medical Sciences and
Technology, Trivandrum - 695012

Guest Article

Current status of dental materials research in SCTIMST, Trivandrum

Part I: Restorative materials

* Lizymol P.P. and Kalliyana Krishnan V.

Introduction

Modern dentistry uses a wide variety of materials for the aesthetic repair of teeth. These are broadly divided into composite resins and glass ionomer cements, though in recent years new hybrid materials have appeared. Acid modified composites (compomers), resin modified glass ionomer cements (RMGIC) and Gionomers, are some examples. Each of these materials has its own advantages and disadvantages. Currently attempts are being made to develop tissue-engineered tooth.

The first tooth colored material used in restorative dentistry was composites which have significant advantages for patients. As an alternative to composites glass ionomers may be used in non-load bearing applications. Compomers are composite materials composed of an ion leachable glass embedded in a polymeric matrix. Compomers were developed in an attempt to “better” the glass ionomer restorative materials. They were touted as being similar to glass ionomers but have much better esthetics and are easier to place and polish. Although they had better handling properties than GICs, they released much less fluoride and could not be recharged. Currently available compomers in the market are F2000 (3M), Dyract AP (Dentsply/Caulk) and Compoglass F (Vivadent)

In the 1990's manufacturers improved shortcomings of GIC by adding resins to glass ionomers to produce resin-modified glass ionomers. These products (e.g., Fuji II LC.; Vitremer, 3M ESPE; Photac-Fil Quick, 3M ESPE) have much better esthetics and handling characteristics than glass ionomers. Importantly, they also retain many of the glass ionomer's beneficial properties, such as long-term fluoride release and the ability to be recharged with topically-applied fluoride. They tend, however, to discolor over time. Gionomers are a relatively new type of restorative material. The name “gionomer” is a hybrid of the words “glass ionomer” and “composite”, which pretty well describes what a gionomer is claimed to be. Their manufacturers claim they have properties of both glass ionomers (fluoride release, fluoride recharge) and resin composites (excellent esthetics, easy polishability, biocompatibility). Gionomers are distinguished by the fact that, while they are resin-based, they contain pre-reacted glass-ionomer (PRG)

particles. The particles are made of fluorosilicate glass that has been reacted with polyacrylic acid prior to being incorporated into the resin. The pre-reaction can involve only the surface of the glass particles (called surface pre-reacted glass ionomer or S-PRG) or almost the entire particle (termed fully pre-reacted glass ionomer or F-PRG). Gionomers are similar to compomers and resin composites in being light activated and requiring the use of a bonding agent to adhere to tooth structure. Example of commercially available gionomer is Shofu's *Beautiful*.

The research on dental tissue engineering lead by Professor Paul Sharpe at King's College London Dental Institute demonstrated that tooth development can be initiated in stem cells, and that fully formed teeth can be created in developmental models. However the lack of any enamel forming cells in the enamel of fully developed erupted teeth precludes the potential for cell-based approaches for enamel regeneration

The goal of modern restorative dentistry is to functionally and cosmetically restore lost tooth structure. Destroyed coronal tooth structure, most commonly resulting from dental caries, is currently restored using metal or polymer-based materials; primarily silver amalgam, resin-based composites and metal or porcelain crowns. Ideally, a dental material to be used in the oral cavity should be harmless to all oral tissues—gingiva, mucosa, pulp, and bone. Furthermore, it should not contain any toxic, leachable, or diffusible substance that can be absorbed into the circulatory system, causing systemic toxic responses, including teratogenic or carcinogenic effects. The material also should be free of agents that could elicit sensitization or an allergic response in a sensitized patient.

The problem associated with composites is that they have no bonding with tooth. A bonding system capable of good adhesion between the tooth and the composite resin is required. The first breakthrough for adhesive approach occurred when composite materials began to be used and Buonocore^{1,2} discovered in 1950's that tooth enamel can be etched and bonded to composite without unnecessary sacrifice of sound tissue. He tried to repeat it with dentin, but adhesion to dentin was poorer with etching than without etching. But the seed for a convergence of adhesive, conservative and esthetic dentistry was planted by Buonocore.

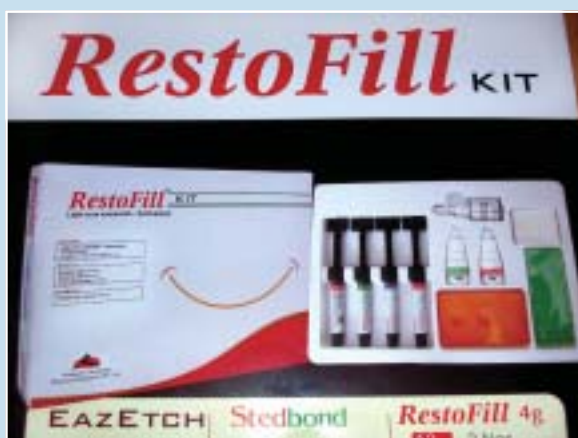

Fig. 1. Restofill kit marketed by Anabond Stedman

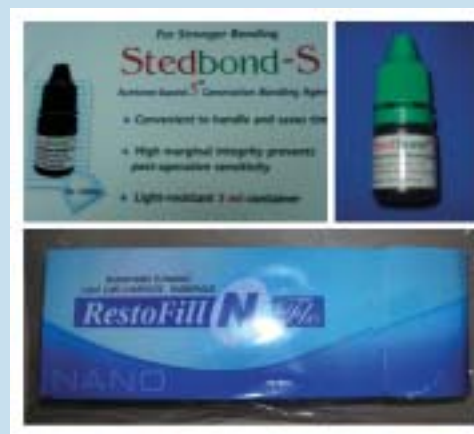

Fig. 2. Bonding agent and nano composite marketed by Anabond Stedman

The history of polymeric dental materials started with the discovery of 2,22 -bis-[4-(methacryloxypropoxy) - phenyl]propane (**Bis-GMA**) by the father of modern composites Dr.Rafel L Bowen^{3,4} in 1962. He wanted a bulky monomer because smaller monomer molecules tended to shrink too much (Methyl methacrylate shrinks 27-30% during polymerization!). But his BisGMA monomer was too thick and viscous, so he also added some less viscous monomer TEGDMA as a diluent to get the correct consistency. Bowen's BisGMA- TEGDMA monomer system remains one of the most popular systems even now. There are reasons why BisGMA is bulky and highly viscous: (a) There are two bulky aromatic groups in the structure (b) There are also two hydroxyl groups which make the monomer molecules to cling together through hydrogen bonds to make it exist as an oligomer. The result is a viscous oligomer. An aliphatic TEGDMA monomer with no hydroxyl groups is used as the diluent to facilitate it's convenient handling. The bifunctionality of the two monomers also helps in cross-linking

After the discovery of BisGMA by Bowen in 1962, it has been used as the most common monomer in composite restoratives. Though the monomer forms strong homopolymers with fair modulus and flexural strength, attempts were made by many researchers to replace Bis GMA with monomers having low viscosity and more functionality. Visible light cure composite materials based on polyfunctional monomers have been found to exhibit enhanced performance with better mechanical properties and less residual monomers.⁵ Recently a new family of organic-inorganic hybrid materials termed as organically modified ceramics (ormocers) is used as substituents for BisGMA. The first dental restorative material based on the ormocer technology (Definite, Degussa A-G, Hanau, Germany) was put on the market in 1998.⁶

Dental materials research in Dental Products Lab

Research work to develop dental products started in Biomedical Technology Wing of SCTIMST in the early nineties as a result of the Oral Task Force of Government of India identifying the need to develop indigenously restorative dental products on a priority basis. The oral task force also identified this laboratory to undertake the task as it had by then successfully developed and commercialized the blood bag system. Composite restoratives imported at a high cost result in a huge drainage of foreign exchange. Our attempt to develop indigenous products and its subsequent commercialization contributed to reduce the burden of the import component in the economy substantially. As per a survey carried out in 2005 (The Hindu, November 29, 2005) the annual dental materials market alone accounts for Rs.3200 crores and about 80% of it is imported. A few dental products made in India are cements, amalgams, orthodontic brackets and wires, crowns and impression materials, orthodontic appliances and rubber dams.

Extensive research work has been carried out in our laboratory during last 15 years⁷⁻⁹ on development of restorative materials started with the synthesis of Bisphenol A - glycidyl methacrylate (Bis GMA) using indigenous chemicals and the group successfully standardized the synthesis parameters. This method for preparing BisGMA has been accepted worldwide by many laboratories. Later the group successfully developed self cure (chemical cure), non- radiopaque light cure, and radiopaque light cure composites, 3rd generation dentine bonding agent based on BisGMA and 5th generation single solution bonding agent (SSBA)¹⁰ based on pyromellitic glycerol dimethacrylate (PMGDM) and their technologies have been successfully transferred to industry and commercialized (Fig.1) (Trade Names: *Restofill* composite, *Stedbond*, *Stedbond-S*

bonding agent). Later in order to develop monomers with multifunctional methacrylate groups, monomers such as urethane dimethacrylates (UDMA) and urethane tetramethacrylates were synthesized and used for the preparation of restorative composites.¹¹⁻¹⁴ The resultant composite had excellent compressive strength (350-400MPa) diametral tensile strength (40-50MPa) surface hardness (50-60 kg/mm²). The material was found non-cytotoxic to L929 fibroblast cells.

We have subsequently made attempts to develop new organically modified ceramic based dental composites. The concept of ormocer is to combine properties of organic polymer (functionalization, ease of processing at low temperatures and toughness) with properties of glass like materials (hardness, chemical and thermal stability) in order to generate new/synergistic properties. The processing steps are based on sol-gel type reaction already well known for the synthesis of ceramics. In the case of ormocers, the formation of the additional organic network or cross-linking follows after the build up of the inorganic network. Tailoring of multifunctional ormocer precursors is the basis for their use as matrices for dental composite. Low shrinkage during curing, good mechanical properties, abrasion resistance, suitable elasticity, adhesion to teeth and good toxicological data led to the successful development of ormocers as matrices for dental composite applications.⁶

The new dimethacrylate and tetramethacrylate inorganic-organic hybrid materials developed are organically modified ceramic resins containing alkoxides or mixtures of alkoxides of silicone, aluminum, calcium and titanium with various polymeric methacrylate groups. The selection of alkoxide and specific organic monomers having functional groups that are responsible for enhanced properties of the inorganic-organic hybrid materials is important.

Preparation of paste

A dental composite comprises of resin matrix and filler. The polymer is strengthened by a filler addition to the monomer before polymerization. This is done after coating a silane coupling agent to the filler to ensure bonding at the filler-resin interface. The filler addition makes the monomer into a composite structure. The addition of filler into the polymer helps to improve the properties of the polymer in a number of ways. It increases strength, reduces shrinkage, reduces thermal expansion coefficient, alters optical properties, and so forth. In a dental composite (which consists of a resin matrix and a filler distribution), for example, we need to increase the modulus of elasticity and strength of the resin, decrease its shrinkage, thermal expansion coefficient etc. as well as optimize its translucency. Filler incorporation helps in all of these things. Typically used fillers are quartz or silicate glass particles. Radio-opacity of the filler is an important consideration so that the composite presence in the tooth can be readily detected

in radiographs for diagnosis. Heavy elements like Barium, strontium, ytterbium etc. are incorporated for this purpose. Beyond composition, the filler particle size, and its dispersion have been found to be the most important filler parameters.

Mean filler particle size is carefully controlled to make the composite properties reproducible and uniform. However, filler particle sizes are often used in a bimodal distribution with high frequency of particle sizes around two mean particle sizes: one larger and one smaller, the smaller one often being colloidal silica. Some of the composites are referred to as hybrids because of this bimodal distribution of particles. Nanohybrids and nanocomposites were developed in recent years. Nanoparticles have dimensions in the order of several nanometers. Generally, the nanoparticle size under favor are those with particle size <100 nm. The nanohybrids use nanofiller particles and minifiller particles to get sufficient filler packing into the composites. The nanocomposites use nano particles to do the same. The nanocomposite developed using SCTIMST Know-How is marketed by Anabond Stedman with the trade name *Restofil N Flo*.

Evaluation of composites and bonding agents

Chemical cure, light cure non radiopaque, light cure radiopaque and dual cure composites based on Bis GMA, composites based on urethane tetra methacrylate and organically modified ceramic resin were characterized extensively and the results were published.

Some of the properties studied¹⁵⁻¹⁹ are aging studies of BIS-GMA based polymers, shelf life studies of a visible light cured dental composite paste, effect of amine activators on the properties of chemical curing dental composites., effect of diluent on the properties of urethane based dental composites, effects of diluent concentration upon the properties of organically modified ceramics based composites²⁰ and comparison of the thermal properties of different oligomers by thermogravimetric²¹ techniques. Shear and tensile bond strengths and micro leakage of the different bonding agents were also evaluated. Shear and tensile bond strengths and micro leakage of the different bonding agents were also evaluated. We correlated monomer conversion of an indigenously developed novel organically modified ceramic based dental composite using FT-Raman spectroscopy and vickers hardness number.²² In order to study the long term effect of storage in aqueous media and effect of thermal cycling, the surface hardness was studied as it is one of the most important physical properties for a comparative study of dental materials. Surface hardness correlates well to compressive strength and abrasion resistance.²³ Moreover it is especially suited in monitoring the surface phenomenon of radiation induced effect on polymers because it investigates the surface of the material and is a non-destructive method. Effect of thermal cycling bulk properties of an organically modified ceramic

composite was also studied. Mechanism of loss of surface and bulk properties during thermal cycling was explained using micro computed tomography results. Linear polymerization shrinkage and depth of cure of organically modified ceramic based dimethacrylate and tetra methacrylate resin based composites were evaluated and a correlation was made between monomer conversion and shrinkage. Tetramethacrylate resins showed better shrinkage properties compared to dimethacrylate resins. Effect of storage in aqueous media on surface hardness of various dental restoratives were studied²² and found that composites and compomers have a loss in surface hardness where as GIC has a significant increase in surface hardness. The high solubility of acrylic polymers may be the reason for the high degradation of composites during storage.²⁴ In glass ionomers, the ionic reactions are a continuous process during storage resulting in crosslinking. Moreover in glass ionomers a bond once debonded can always be re-formed if the others are maintained²⁵. As the chemical bonds formed in glass ionomers are ionic, it can be considered as more dynamic in nature. Also the acid base reaction serves to strengthen the material once it has set.

The newly synthesized organically modified ceramic resins are found to mix with quartz filler to get uniform paste, which cures within 10-30 sec. into a hard solid when exposed to a visible light source at a wavelength of 440-480 nm. The cured solid composite is found to possess CS value 250-350 MPa, DTS value 40-60 MPa, FS 70-120 MPa, FM 7-10 GPa, WS < 40 mg/mm³, S < 7.5 mg/mm.

Development of GIC

Due to the inherent adhesion and sustained fluoride release GIC have advantages for specific clinical applications. It has also excellent intra oral durability and good appearance. Currently 100% of glass ionomers are imported into India resulting in a huge loss of foreign exchange. Every dentist, irrespective of their specialization uses at least one kit of glass ionomer (approx. Rs. 2000/-) per month for either luting or restorative or core build up applications. Assuming total number of dentists in India to be around 80000, the total kits likely being used in India per annum works out to be a whopping 9,60,000. The total existing market for glass ionomers therefore is around 192 crores. Therefore a huge market potential exists for the product in our country.

Therefore attempts were made for the development of GIC using indigenous technology. We have already developed an α - α unsaturated polyacid copolymer and a fluoroaluminosilicate glass powder which when mixed in equal proportions sets into a hard solid within a short time, the time depending on whether it is for luting, core build up or restorative applications. The powder (glass): liquid (copolymer) ratio also varies depending on the application. The copolymer and glass powder

have undergone exhaustive characterization studies. The GIC prepared from the above two materials have also been subjected to physico-chemical and cytotoxic evaluation. Currently the product is undergoing technology transfer to industry.

Development of a chemomechanical caries dissolving agent

As part of an industry sponsored project, we have developed a chemo mechanical caries dissolving agent which can eliminate conventional drilling procedures which involve considerable amount of pain and discomfort to the patient. This product has already completed all tests and is undergoing clinical evaluation.

Facilities available in Dental Products Lab for evaluation of dental materials

1. Micro computed tomography : X-ray microcomputed tomography (iCT) is a non-destructive 3D imaging technique that can be used to inspect the internal structures of small objects with high spatial resolution and unprecedented speed. iCT measures the content at each pixel which can be used to evaluate the volume of composites aided by the presence of radio opaque fillers. iCT can also be used to determine the void content and quantify changes in dimensionality such as polymerization shrinkage

2. Universal testing machine can be used for the evaluation of mechanical properties like compressive strength (CS), diametral tensile strength (DTS), flexural strength (FS), flexural modulus (FM) of composites, shear strength and tensile strength of adhesives

3. FT Raman and FTIR spectrometers can be used for measuring monomer conversion by functional group analysis. Recently, FT-Raman spectroscopy has also been used as a tool for characterization of polymer systems²⁶. FT Raman spectroscopy can be used to, to obtain structural information for opaque materials such as enamel, dentine and polymer composites²⁷

4. High pressure liquid chromatography: Purity and molecular weight of oligomers and polymers can be checked by HPLC assembled with GPC (gel permeation chromatography) column.

5. Dental thermal Cycler can be used for cycling dental materials thermally between 5°C to 55°C in order to simulate real life oral conditions.

6. Abbe refractometer can be used to measure the refractive index of oligomers and polymers. A sharp interface in refractometer during refractive index measurement is an indication of purity of the resin.

7. Vickers hardness tester can be used to measure the surface hardness (Vickers hardness number)

8. Three body wear tester can be used to compare the three body wear properties of different dental materials.

9. Biocompatibility Evaluation

Facilities exist in BMT wing to carry out biocompatibility studies of all dental materials as per ISO 7405 international standard procedures. Biocompatibility is the ability of a material to elicit an

appropriate biological response in a given application in the body. Whether a material is biocompatible is dependant on what physical function we demand from the material and what biological response we require from it. Today in the development of any material, we have to consider the biocompatible aspects in addition to strength, aesthetics and functional aspects. Initially in vitro cytotoxicity studies are carried out as per ISO 10993. After the cytotoxicity gets passed, in vivo toxicological evaluations are carried using small animal models. Finally pulp and dentine test in large animal will be carried out with the prior permission from CPCSEA and institute's animal ethics committee. Biomedical Technology Wing has the in-house facilities for all in vitro and in vivo toxicological evaluation as per international standards. The various materials developed in SCTIMST met all the requirements for biocompatibility as per international standards.

Conclusion

Dental Products Laboratory of SCTIMST has successfully developed and transferred the technologies of a series of aesthetic direct restorative dental materials such as chemical cure composite, visible light cure non radiopaque composite, visible light cure radiopaque composite (Restofill), a third generation two component bonding agent based on BisGMA (STEDBOND), a fifth generation single solution bonding agent (STEDBOND-S) and a caries dissolving agent. Out of these products, three are (Restofill, Stedbond and Stedbond –S) are marketed by a Chennai based company, Anabond Stedman Pharma Research (P) Ltd. They also marketed a nano composite under the trade name Restofill N Flo. The indigenous technology development is expected to make available and improve significantly the general public dental health at an affordable cost.

References

- Buonocore MG A simple method of increasing adhesion of acrylic filling materials to enamel surfaces. *J Dent Res* 1955., 35,849-53.
- Buonocore MG, Wileman W and Brudevold F A report on a resin composition capable of bonding to dentin. *J Dent Res* 1956. 35, 846-51
- Bowen RL Use of epoxy resins in restorative materials. *J Dent Res* 1956, 35,361–369.
- Bowen RL Properties of a silica-reinforced polymer for dental restorations. *J Am Dent Assoc*1963, 66, 57–64
- Joong-Gon Kim, Chan-Moon Chung Trifunctional methacrylate monomers and their photocured composites with reduced curing shrinkage,water sorption and water solubility,*Biomaterials* 2003,24,3845-51
- Hass K-H, Hybrid inorganic organic polymers based on organically modified Si-alkoxides, *Adv.Eng.Mater.*, 2000,2,(9),571-82
- Sheela MS, Tamare Selvy K, Kalliyana Krishnan V, and Pal SN, Studies on the synthesis of a methacrylate based dental restorative resin., *J. Appl. Polym. Sci.*, 1991.42, 561-573,
- Valiathan A., PalSN, Kalliyana KrishnanV., Mohanty M, Lal AV, Rathinam K, Jayabalan M, Usha K, and Manu S, Development and evaluation of BIS-GMA based composite dental restorative material, *J. Ind. Orthodont. Soc.*, 1992, 23(1,2), 1-9,
- Jessy KA, Fancy MA., Kalliyana Krishnan V, Aging studies of BIS-GMA based polymers.,*Polymer Science: Recent Advances.*, I.S.Bharadwaj (Ed).,Allied Publishers (Pub)., New Delhi, 1994. 589-595,
- Kalliyana krishnan V, Lizymol PP, Kumari TV, Tharun A. Rauf, Thomas MM, Development and Evaluation of a Single Solution Bonding Agent as a Dental Adhesive *Journal of Polymer Materials*, 2005,21, 145-152.
- Kalliyana Krishnan V, Lizymol PP, and Sindhu .P.Nair , Urethane tetramethacrylates: Novel substitutes as resin matrix for radiopaque dental composites *J. App. Polym. Sci.* 1999,74, 735-746,
- Lizymol PP, and Kalliyana Krishnan V, Synthesis and Characterisation of three Novel Urethane Tetramethacrylate Resins for Dental applications, *Proceedings of the XIV Kerala Science Congress* 2002, 29-31, January, Kochi.
- Lizymol PP. and Kalliyana Krishnan V. A study on the diluent effect on the properties of urethane based dental composites *J. Polymer Materials*, 2003,20, 59-66,
- Kalliyana krishnan V, Lizymol PP and Jacob K.Abraham Synthesis and Characterization of a Urethane Dimethacrylate Resin with Applications in Dentistry, *Journal of Polymer Materials*, 2004,21(2), 137-144
- Kalliyana Krishnan V, Prasanna AK, Roy Joseph, Shelf life studies of a visible light cured dental composite paste., *Macromolecules: Current trends.*, S.Venkitachalam (Ed).,Allied Publishers (Pub)., New Delhi., 1994,706-713.,
- Leny Mathew, Roy Joseph., Kalliyana Krishnan.V. Effect of amine activators on the properties of chemical curing dental composites, *J. Biomater. Applications.*, 1997,11(3), 349-359.,
- Valiathan, A, Pal SN, Roy Joseph, Kalliyana Krishnan V, Mira Mohanty, Lal.AV, Rathinam K, Development and evaluation of visible light cured dental restorative material, *J. Ind.Orthodont. Soc.*, 1995,26, 2, 66-71,
- Kalliyana Krishnan V, The effect of storage media upon the solvent uptake and solubility of a dental composite, *J. Ind. Orthodont..Soc.* 1996,27, 2, 55-57,
- Kalliyana Krishnan V, Bindhu DB, and Manjusha K Studies on marginal leakage associated with visible light cured dental composites *J. Biomater. Applications.*, 10(4), 348-359, 1996.
- Lizymol PP, Effects of Diluent Concentration upon the Properties of Organically Modified Ceramics Based Composites for Application in Dentistry *J Applied Polymer Science* 2004,94: 469-473
- Lizymol PP, Thermal studies: a comparison of the thermal properties of different oligomers by thermogravimetric techniques *J Applied Polymer Science* 2004, 93: 977-985,
- Lizymol PP and Kalliyana Krishnan V, Aging effects of dental restorative materials upon surface hardness communicated to *J.Polymer. Mater.*
- Okada K, Tosaki S, Horota K and Hume WR. Surface hardness change of restorative filling material stored in saliva. *Dent Mater*, 2001; 17:34-39
- Igor SM, Gomes MN, Alessandro DL and Leonardo ERF. Diametral tensile strength and Vickers hardness of a composite after storage in different solutions. *Journal of Oral Science*, 2007;49:61-66
- Alan DW. Glass-ionomer cement-origins,development and future. *Clinical Materials*, 1991:7:275-282
- Luis Eduardo Silva Soares, Rick Rocha, Airtton Abrahão Martin, Antonio L B Pinheiro and Marcelo Zampieri. Monomer conversion of composite dental resins photoactivated by a halogen lamp and a LED: a FT-Raman spectroscopy study. *Quim.Nova*, 2005;28(2) doi:10.1590/S0100-40422005000200012
- Xu J, Stangel I, Butler IS and Gilson DFR. An FT-Raman spectroscopic investigation of dentine and collagen surface modification by 2-hydroxy ethyl methacrylate. *J.Dent res*, 1997,76,596-601

***Scientist, Dental Products Laboratory, Biomedical Technology Wing, Sree Chitra Tirunal Institute for Medical Sciences and Technology, Poojappura, Thiruvananthapuram - 695 012**

Effect of selected food items on the tarnish and corrosion resistance of alloys used in dentistry

* Manikya Arabolu, * Navpreet Chhatwal, * Hima Bindu K.,
** K. Chandrasekharan Nair, *** Jaykar Shetty,*** G.Viswanath, **** Divya Hegde

Abstract

Context : Oral environment promotes tarnish and corrosion. The mouth is warm, moist and is continually subjected to fluctuations in pH because ingested foods have a wide range of pH. Metals when placed in the oral cavity undergo electrochemical changes and its exact nature against certain Indian food items is not explored.

Objectives: To evaluate the tarnish and corrosion resistance of the alloys viz. stainless steel, nickel chromium, cobalt chromium and nickel titanium when treated against the following media - boiled egg, mango pickle, lime pickle, garlic pickle, lime juice, cola drink, tooth paste, salt water and tamarind pulp.

Materials and methods: Nine wires of each alloy were taken and subjected to cold working. One wire of each alloy was pierced into a boiled egg. Wires were also dipped into the other media for one month continuously. Only half the length of the wire was dipped into each medium while the other half was used as control. After the experimental period, the wires were observed under stereomicroscope.

Results: Only stainless steel wires dipped in concentrated salt water and lime juice showed evidence of rusting while no change was observed on the other wires.

Conclusions: The alloys tested were safe to be used in the oral cavity. However stainless steel wrought wire clasps could be corroded on exposure to salt water and lime juice.

Tarnish is observed on metallic surfaces as a surface discoloration or as a slight loss or alteration of the surface finish or lustre. In the oral environment, tarnish often occurs from the formation of hard and soft deposits. The soft deposits are plaque and films composed mainly of microorganisms and mucin. Discolouration arises from pigment producing bacteria, drugs containing iron or mercury and adsorbed food debris. Although such deposits are the main cause of tarnish, surface discoloration may also occur on metal by the formation of thin films containing oxides, sulphides or chlorides. The latter phenomenon may be only a simple surface deposit and such a film may also be protective or it may be an early indication of corrosion. The disintegration of a metal by the action of corrosion may occur through the action of moisture, atmosphere, acid or alkaline solutions and certain chemicals. Tarnish is the forerunner of corrosion. The film that produces tarnish may in course of time accumulate elements or compounds that chemically attack the metallic surface.

Many of the Indian food stuff are severely acidic to alkaline. This causes drastic pH changes in the oral cavity, in a very short span of time there by making the environment conducive for the metals to corrode. For example, eggs and fish that are rich sources of protein contain significant amounts of sulphur. Various

sulphides, such as hydrogen or ammonium sulphide, corrode silver, copper, mercury and similar metals present in dental alloys. Also water, oxygen and chlorine ions are present in saliva and contribute to the corrosive action. Various acidic solutions such as phosphoric, acetic and lactic acids that are present in tamarind pulp, lime juice, pickles, soft drinks can promote corrosion. Indian food contains natural acidifying agents such as tamarind, pomegranate seeds, curd, fresh lime juice, home made sugar-cane and vinegars. Curing with salt also adds to acid level slightly. Pomegranate has ellagic acids; curd has lactic acid and has a pH level of 4.6 that drops to 4.4 as it gets sour. Tamarind has about 20% tartaric acid. Amchoor (dried raw tart mango) has oxalic, citric, maleic and succinic acids. Ripened fruits are high in tartaric and Maleic acids with a trace of citric acid. Limes have slightly lower pH level than lemons. Practically, both lime and lemon juices have approximately 5% citric acid. The pH level for lime is 2 and for lemons it is about 2.3. Homemade vinegars used in India have acetic acid ranging from 4% to 18%. Modern recipes use vinegars with 5% acetic acid (pH level of 2.4). Distilled white vinegar has a sharp acid taste. Two Tablespoons of Vinegar (5% acetic acid) is dispersed uniformly all through in one cup of pickle. Pickles are consumed in most of the Indian homes almost everyday. Mango and lime pickle have a pH of



Fig. 1: Specimens inserted into boiled egg



Fig. 2: Specimens dipped in mango pickle



Fig. 3: Specimens dipped in lime pickle



Fig. 4: Specimens dipped in garlic pickle



Fig. 5: Specimens dipped in lime water



Fig. 6: Specimens dipped in cola drink



Fig. 7: Specimens dipped in concentrated salt water



Fig. 8: Specimens dipped in tamarind water




Fig. 9: Rusting on the stainless steel wire dipped in lime juice compared with the control



Fig. 10: Rust on the stainless steel wire dipped in concentrated salt water compared with the control



5 while garlic pickle has a pH of 3.^{1,2,3,4} Concentrated salt water is used by people for gargling which again changes the pH of the oral cavity. Cola drink contains phosphoric acid. It is hypothesised that these food materials are capable of producing tarnish and corrosion to the dental alloys. But there is no documented evidence to prove this. Hence the present study was designed with the following objective to find out the effect of selected food items on stainless steel, nickel chromium, cobalt chromium and nickel titanium.

Methodology

The alloys used in the experiment were stainless steel, nickel chromium, cobalt chromium and nickel titanium. Nine samples of each alloy measuring 5 cm were made. Half the length of each wire was subjected to cold working by pliers. The different media that were used were: boiled egg (Fig 1), mango pickle (Fig 2), lime pickle (Fig 3), garlic pickle (Fig 4), lime juice (Fig 5), cola drink (Fig 6), salt water (Fig 7) and tamarind water (Fig 8). The cold worked side was then dipped into the different media. The other half of the wire served as control. The experiment was continued for a period of one month continuously which was equivalent to the consumption of 20 years. The egg and other media were changed on a daily basis. After the experiment, the dipped half of the wires were viewed under stereomicroscope and compared with the other half

of the wire which served as control.

Results and Discussion

No evidence of tarnish or corrosion was seen on nickel chromium, cobalt chromium and nickel titanium wires. But on stainless steel wires which were dipped into concentrated salt water (Fig. 9) and lime juice (Fig. 10) showed signs of rusting. Unlike the popular belief, alloys do not show signs of tarnish and corrosion against the above mentioned food items. However the stainless steel wire is vulnerable to salt water and lime juice. Patients may be advised not to use appliances and prostheses while taking salt water gargles. After consuming lime juice, patients may be advised to gargle with water to reduce the chances of tarnish and corrosion.

References

- 1) Anusavice K.J., Phillips' Science of Dental Materials, 11th edition 2003, India, Elsevier Publishers, pp-171-202
- 2) Neamat H. Abubakr et al, Effect of alcoholic and low pH soft drinks on fluoride release from compimer. J Esthet Dent 2000; 12:97-104
- 3) What effect does coca cola have on teeth.htm
- 4) Role of acids in Indian pickles how to acidify.htm

*** Post graduate students ** Professor and Head *** Professor **** Associate Professor, Department of Prosthodontics, A.E.C.S Maaruti College of Dental Sciences, Bangalore**

Anaphylaxis-A Fatal Medical Emergency

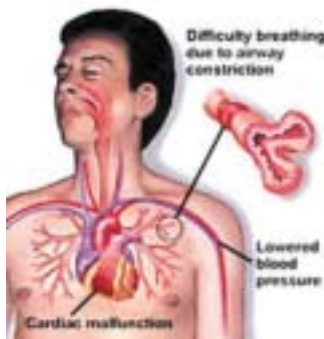
* Venugopalan P.P.

Allergy and Anaphylaxis are nightmares not only for dental doctors, but also for all healthcare providers. Very often the result will be fatal. Therefore it is of utmost important to know about the practical issues related to anaphylaxis and its clinical management.

What is anaphylaxis?

Anaphylaxis is a severe systemic allergic reaction characterized by multi system involvement, including skin, airway, vascular system and gastrointestinal tract.

In severe cases there may be complete airway obstruction, cardio vascular collapse and even death.



Types of Anaphylaxis

There are two types of reactions

- ❖ Classic anaphylaxis
- ❖ Anaphylactoid reactions

Classic forms – This is a hypersensitivity reaction mediated by Antibody immunoglobulins like IgE, IgG.

Anaphylactoid reactions – They are presented with similar clinical syndrome, but are not immune mediated.

How does it happen?

Prior sensitization to an allergen has invariably occurred, producing antigen-specific immunoglobulin. Subsequent re-exposure to this allergen provokes the anaphylactic reaction, as the inciting allergen bind to Antigen-specific IgE on basophils and mast cells. These cells release mediator like histamine, leukotrienes, prostaglandins, thormboxanes and bradykinis. These agents cause increased mucus membrane secretions, increased capillary permeability and fluid leak. It also produced decrease tone in vasculature and increased tone in bronchioles


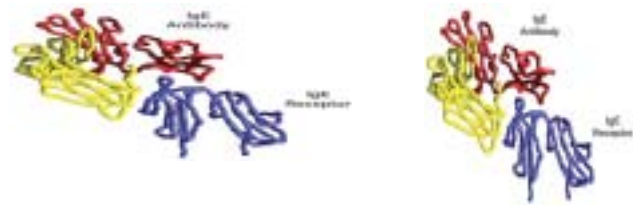
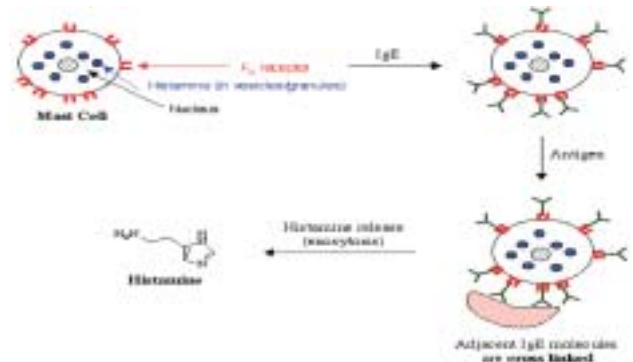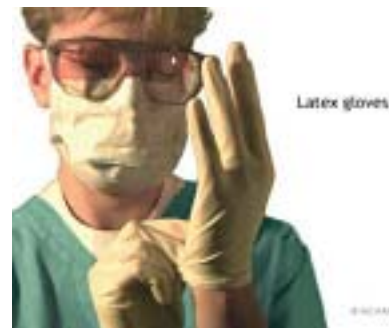


Fig –Mast cell bursting in anaphylaxis and releasing Histamine



What are the common Allergens?

- I. Drugs
 - a. Antibiotics
 - b. Aspirin
 - c. NSAID
 - d. IV contrast agent
- II. Glove, Bladder catheter



III. Stinging insects

- a. Hymenoptera (membrane winged insects)
- b. Ants
- c. Bees
- d. Wasps
- e. Yellow jackets



#ADAM

IV. Food

- a. Peanuts
- b. Tree-grown nuts
- c. Sea food
- d. Wheat



What about local Anesthetics?

Anaphylactic reaction following local anesthetics like Lignocaine is very rare. But the preservatives used in preparation may cause such reactions.

How will you recognize anaphylaxis?

Look for symptoms like

- H/o exposure to allergen [In some cases, there may not be a clear history of exposure]
- Hypotension
- Broncho spasm
- Upper airway obstruction
- Pulmonary edema
- Angio Odema
- Generalized edema
- Pruritus
- Rash
- Vomiting
- Diarrhea
- Abdominal pain



What are the conditions that mimic anaphylactic presentations?

- Anxiety / Panic disease
- Asthma
- Bronchospasm /Laryngeal edema due to inhalation of irritant gases
- Foreign body airway obstruction
- Hypovolemia
- Vasovagal episode
- Cardiogenic shock

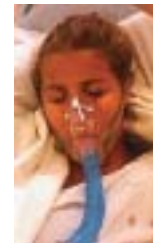Fainting and Anaphylaxis: clues, which may help you, tell the difference
(this guide is not perfect; you need an expert if in doubt.)

	Anaphylaxis	Fainting
Colour	Pink, typically	Pale, typically
Pulse	Fast, usually	Slow, usually
Blood pressure	Can remain low lying down	Normal when lying down
Other features which may be present	Nettlerash Swelling Difficulty breathing Tummy pain or diarrhoea	The person has probably fainted before. (Some people do faint, others don't)

Which lab test will help to diagnosis anaphylaxis?

In emergency situation no biochemical investigation are required to commence treatment.. Failure to identify and to appropriately treat anaphylaxis can be fatal.

How will you manage anaphylaxis? THE 4 STEPS!!



❖ **Step 1: Initial assessment and Management**

- Support ABC – Basic life support
 - Airway
 - Breathing
 - Circulation

Establish –

- o Intravenous Line (IV line is the life line)
- o O2 administration (Use high flow)
- o Monitor (Pulse, Blood Pressure, Respiration, EKG, SPO2)

Control airway with Endotracheal tube in severe airway obstruction

❖ **Step 2: Drugs**

What drug?

The drug of choice is Epinephrine in all cases with systemic reactions especially hypotension, airway swelling, breathing difficulty

(Histamine is the major culprit in anaphylaxis and Epinephrine is the physiological antidote to it)

Epinephrine –

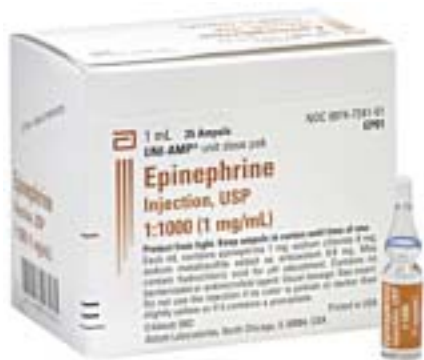Preparation – 1ml in 1 ampoule with 1 in 1000 dilution. That means 1ml = 1mg

Dose – 0.3 – 0.5mg ie 0.3 – 0.5ml intramuscular route (Lateral Thigh or Gluteus muscle or Deltoid)

Repeat in every 15 – 20minutes if there is no clinical improvement

Pediatrics dose – 0.01mg/kg

If anaphylaxis appears to be severe with immediate life threatening manifestation give intravenous Epinephrine



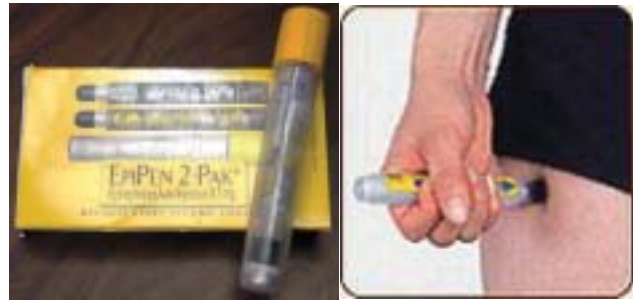How to give Intravenous Epinephrine?

Take 1ampoule Epinephrine and add 9cc of Normal Saline to make a solution of 1 in 10,000 dilution. Then administer 1 ml (0.1 mg) slowly over 5 minutes intravenously.

Assess the response and signs of systemic reaction. Repeat the 0.1 mg dose every 3-5 minutes until an adequate response in pulse and blood pressure is observed.

Alternatively set an IV infusion at rate of 1-4 microgram/ minute may prevent the need to repeat Epinephrine injections frequently.

EPIPEN- Preloaded self injectable epinephrine pens are available for those patients who have recurrent anaphylactic reactions.



❖ **Step 3: Aggressive fluid resuscitation**

What fluid ? How much?

Give isotonic crystalloid (Normal saline) if symptoms are present and do not respond rapidly to Epinephrine. A rapid infusion of 1-2 L or even 4 Liter may be needed initially

Special situation

1.Patient on Beta blockers – Poor responders to Epinephrine , may be required Glucagon.1-2 mg IV every 5 minutes . Ipratropium inhalation is also recommended.

2. Vasopressin - May be useful in severely hypotensive patients.

3.Angioedema – Hereditary angioedema is a deferential diagnosis of the anaphylaxis. Require C 1 esterase inhibitor replacement concentrate if available or Frozen Plasma may be used.

4. ACE (Angiotensin converting enzyme) inhibitor reactive angioedema is another deferential diagnosis, require early airway management.

What are the other drugs to support therapy ?

1. H1 blocker – Antihistamines (Eg – 25-50 mg of Diphenhydramine IV)

2. H2 blocker - Like Ranitidine 150 mg (Oral / IM /IV)

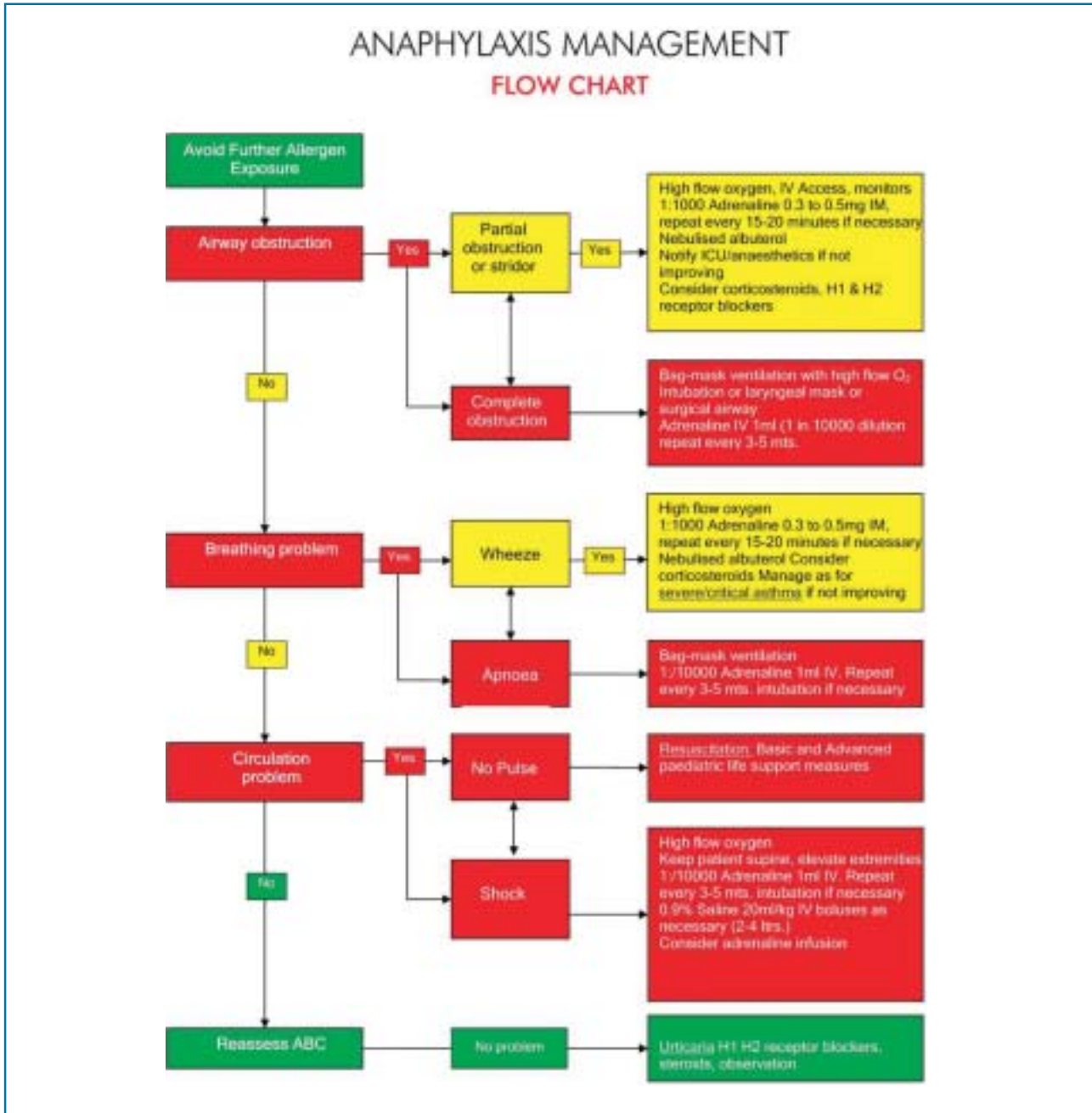
3.Inhaler Beta adrenergic agents - Give as inhaler

❖ Albuterol if bronchospasm is a major feature
❖ Ipratropium may be useful in patient on beta blockers

4. Corticosteroid - Infuse high dose of steroids early in the course of therapy. Beneficial efforts are delayed at least 4-6 hours

❖ **Step 4: Observation & Disposal**

Patient who responds to therapy require observation because symptoms may recur in some patients (up to 20 %) in 8 hours (Biphasic response) despite an intervening asymptomatic period.



A patient who remains symptom free for 4 hours after treatment may be discharged.

Conclusion

The management of anaphylaxis includes early recognition, anticipation of deterioration and aggressive support of airway, oxygenation & ventilation and circulation. Prompt, aggressive therapy may succeed even if cardiac arrest develops.

References:

1. Anaphylaxis. Circulation 2005;000:IV-143-IV-145. American Heart Association
2. Brian H.Rowe. Anaphylaxis and Acute allergic reactions 2004;247-252, Emergency Medicine-A comprehensive study guide; Sixth Edition. American College of Emergency Physicians
3. T.Paul Tran. Allergy, Hypersensitivity and Anaphylaxis 2006; 1818-1837. Rosen's Emergency Medicine –Concepts and Clinical Practice; Sixth edition.
4. www.Circulationaha.org

*** Chief, Emergency Medicine, Dy Director, MIMS Academy, Malabar Institute of Medical Sciences Ltd. P.O. Govindapuram, Calicut, Kerala – 673 016**

Peripheral cemento ossifying fibroma

* S. Sunil, ** Murasim M., ** Minu Mathew, **** Devi Gopakumar, ***** Antony George, ***** B. S. Sreenivasan

Abstract

Peripheral cemento ossifying fibroma (PCOF) is a non-neoplastic enlargement of the gingiva. The aetiology of PCOF though is unclear, trauma or local irritation such as dental plaque, calculus, ill-fitting dental appliances and poor-quality dental restorations are all known to precipitate the development of PCOF. Inflammatory hyperplasia originating in the superficial PDL is considered to be a factor in the histogenesis of the PCOF. Clinical differential diagnosis includes peripheral giant cell granuloma, pyogenic granuloma, fibroma and peripheral odontogenic fibroma. PCOF affects both genders but a higher predilection for females has been reported in the literature.

Conservative surgical excision must be followed by diligent curettage of the wound and root planing of adjacent teeth if recurrence is to be avoided. With simple removal the recurrence rate is greater than 20%. Malignant transformation has not been reported for this lesion.

In conclusion, a slowly growing soft tissue mass with speckled calcifications in the anterior oral cavity of children or young adults should raise the suspicion of a reactive gingival lesion such as PCOF.

Introduction

Peripheral ossifying fibroma (PCOF) is a reactive focal gingival overgrowth derived histogenetically from cells of the periodontal ligament and usually developing in response to local irritants. Although being reported to reach more than 6 cm, they are usually less than 1.5 cm in diameter, and the diagnosis can be made by clinical inspection and biopsy. Some authors have called it fibrous epulis, calcifying fibroblastic granuloma, or peripheral fibroma with calcification.

Case report

A thirty six year old male reported to our college with a nontender enlargement of interdental papilla of 11, 12 region of 1x1 cm, smooth, pink, of 1.5 yrs duration (Fig. 1). Radiographic investigation did not reveal any pathology. The lesion was excised and the histopathologic examination showed moderately collagenous connective tissue lined by hyperplastic stratified squamous epithelium. Endothelial lined vascular channels with extravasation of RBCs are noticed. Dense collection of chronic inflammatory cells are seen focally. Calcifications surrounded by hyalinized areas are noticed in a few areas deep in the connective tissue.

Discussion

By definition, the peripheral ossifying fibroma must be associated with gingival tissues, and the diagnosis cannot be used for lesions of other oral sites. The presence of teeth is not, however, required for the diagnosis, as periodontal ligament fibers remain within and above alveolar bone long after their associated teeth

have been extracted. Shepherd first reported this entity as alveolar exostosis in 1844. Because of its overwhelming incidence on the gingiva, the condition is associated with two other diseases, though not because they occur together. Instead, the three are associated with each other because they appear frequently on gingiva and they also begin with the letter “p”: pyogenic granuloma and peripheral giant cell granuloma. Some researchers believe peripheral ossifying fibromas to be related to pyogenic fibromas and, in some instances, are the result of a pyogenic granuloma which has undergone fibrosis and calcification.

It is a reactive focal gingival overgrowth derived histogenetically from cells of the periodontal ligament and usually developing in response to local irritants (plaque and calculus) on associated teeth; consists microscopically of a hyperplastic cellular fibrous stroma supporting deposits of bone, cementum, or dystrophic calcification. In addition to the peripheral giant cell granuloma, mesenchymal cells of the periodontal ligament are capable of producing another unique inflammatory hyperplasia, the peripheral ossifying fibroma, also referred to as the peripheral cementifying fibroma, depending on whether or not bone or cementum is seen microscopically. The pluripotential cells of the ligament have the apparent ability to transform or metaplastically alter into osteoblasts, cementoblasts or fibroblasts. This is a reactive lesion, not the peripheral counterpart of the intraosseous neoplasm called central cemento-ossifying fibroma.

An aggregated submucosal proliferation of primitive oval and bipolar mesenchymal cells is the hallmark of

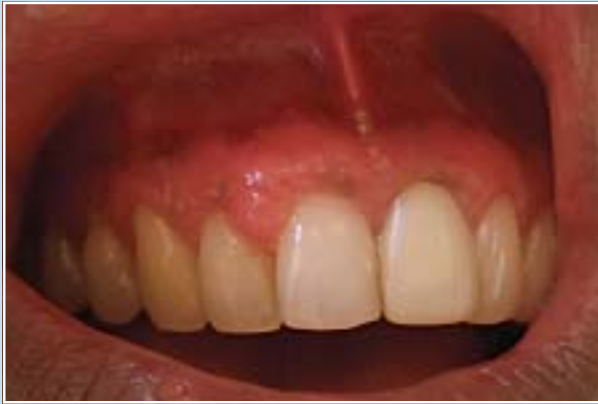

Fig. 1 Nontender enlargement of interdental papilla of 11, 12 region

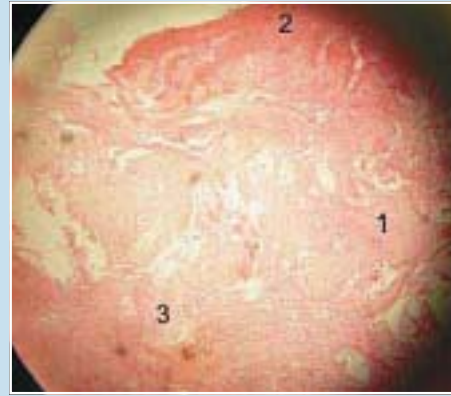


Fig. 2 Histopathology
1. Calcifying areas in the connective tissue 2. Epithelium, 3. Fibrous connective tissue

peripheral ossifying fibroma. The lesion may be very cellular or may be somewhat fibrotic, but scattered throughout are islands and trabeculae of woven or lamellar bone, usually with abundant osteoblastic rimming. Metaplastic bone may also be seen. The calcified tissues may have the dark-staining, acellular, rounded appearance of cementum, in which case the term peripheral cementifying fibroma has traditionally been used. Many examples show an admixture of bone and cementum, i.e. peripheral ossifying/cementifying fibroma, and early lesions may contain only small ovoid areas of dystrophic calcification. While the lesional stroma is similar to that of peripheral giant cell granuloma, the erythrocyte extravasation of the latter lesion is not a feature of peripheral ossifying fibroma and osteoclast-like cells are quite rare.

The lesional nidus is not encapsulated but is rather well demarcated from the surrounding fibrovascular stroma. Surrounding tissues are often edematous, with neovascularity and variable numbers of chronic and acute inflammatory cells. By way of differential diagnosis the exuberant callus so common to the long bones is almost never found at the surface of jawbones, hence, is not a serious diagnostic distinction from peripheral ossifying fibroma. Some gingival masses, however, contain large areas of classic pyogenic granuloma, irritation fibroma or peripheral giant cell granuloma, as well as peripheral ossifying fibroma. In such cases the pathologist usually chooses for the appropriate diagnosis the lesional type that predominates. Also, individual cells must be carefully examined for dysplastic changes in order to rule out osteoblastic osteosarcoma or juxtacortical osteosarcoma, but frequent mitotic figures of normal configuration are acceptable for the benign diagnosis, especially in lesions found in children.

The color of peripheral ossifying fibromas ranges from red to pink, and is frequently ulcerated. It can be sessile or pedunculated with the size usually being less than 2 cm. Weeks or months may pass by before it is seen and diagnosed.

There is a gender difference with 66% of the disease occurring in females. The prevalence of peripheral ossifying fibromas is highest around 10-19 years of age. It appears only on the gingiva, more often on the maxilla rather than the mandible, and is frequently found in the area around incisors and canines. The adjacent teeth are usually not affected.

Peripheral ossifying fibromas (PCOF) appear microscopically as a combination of a mineralized product and fibrous proliferation. The mineralized portion may be bone, cementum-like, or dystrophic calcifications. Additionally, highly developed bone or cementum is more likely to be present when the peripheral ossifying fibroma has existed for a longer period of time.

The aetiology of PCOF though is unclear, trauma or local irritation such as dental plaque, calculus, ill-fitting dental appliances and poor-quality dental restorations are all known to precipitate the development of PCOF. Inflammatory hyperplasia originating in the superficial PDL is considered to be a factor in the histogenesis of the PCOF. The peak incidence of PCOF is between the second and third decades.

Eversole and Rovin stated that the constant irritation present during exfoliation of the deciduous teeth and eruption of the permanent teeth may result in an increased incidence of reactive lesions which originate from the periodontal ligament.

Despite reports of Peripheral cemento ossifying fibroma (PCOF) in children with deciduous or mixed dentition, few data are available regarding the specific occurrence of this lesion involving the deciduous dentition. Hanemann et al reported the presence of PCOF in the anterior region of the maxilla of an 11-year-old boy with an evolution of 6 months, which appeared after orthodontic treatment. Pérez and Lopez reported the case of a 6-year-old boy with a 1-month history of this tumor located in the hard palate close to the palatine rugae, which appeared after exfoliation of tooth 61. In contrast, Kohli, Christian and Howell¹¹

reported the case of a 7-month-old infant in whom this lesion was observed in the anterior region of the lower alveolar margin associated with a neonatal tooth. In a clinical trial, Cuisia and Brannon analyzed 134 cases of PCOF in children ranging in age from 1 to 19 years, with a mean age of 14 years.

Gardner recommended that the term PCOF be used to describe a common, non-neoplastic lesion that shows histopathological characteristics of a fibrous cellularized stroma containing a variety of mineralized material, differentiating it from peripheral odontogenic fibroma which is characterized by odontogenic epithelium and dysplastic dentin. Histologically, PCOF shows a parakeratinized and hyperplastic epithelium and well-cellularized connective tissue containing mineralized components ranging from bone to cementum and, less frequently, dystrophic calcifications. Orkin and Aimadas emphasized the importance of histopathological examination to confirm the diagnosis of PCOF, which clinically resembles a pregnancy tumor, epulis fibrosa, inflammatory hyperplasia, or peripheral and central giant cell granuloma.

PCOF can show diffuse radiopaque calcification but not all lesions exhibit these radiographic characteristics. Most lesions are not associated with bone destruction. A case of severe destruction of adjacent bone structures has been reported in the literature, while discrete bone resorption under the crown of the affected tooth was observed in the present case. PCOF can cause erosion of alveolar bone and tooth separation and interfere with or delay tooth eruption.

Conservative surgical excision must be followed by

diligent curettage of the wound and root planing of adjacent teeth if recurrence is to be avoided. With simple removal the recurrence rate is greater than 20%. Malignant transformation has not been reported for this lesion.

In conclusion, a slowly growing soft tissue mass with speckled calcifications in the anterior oral cavity of children or young adults should raise the suspicion of a reactive gingival lesion such as PCOF.

References

1. Buchner A, Hansen LS. The histomorphologic spectrum of peripheral ossifying fibroma. *Oral Surg Oral Med Oral Pathol* 1987; 63:452–461
2. Hanemann JAC, Pereira AAC, Ribeiro Júnior NV, Oliveira DT. Peripheral ossifying fibroma in a child: report of case. *J Clin Pediatr Dent.* 2003;27:283–285.
3. Eversole LR, Rovin S. Reactive lesions of the gingiva. *J Oral Pathol.* 1972;1:30–38.
4. Kenney JN, Kaugars GE, Abbey LM. Comparison between the peripheral ossifying fibroma and peripheral odontogenic fibroma. *J Oral Maxillofac Surg.* 1989;47:378–382.
5. Gardner DG. The peripheral odontogenic fibroma: An attempt to classification. *Oral Surg Oral Med Oral Pathol.* 1982;54:40–48.
6. Buchner A. Peripheral odontogenic fibroma. *J Cranio Max Fac Surg* 1989; 17: 134–138.
7. R. Rajendran, B. Sivapathasundaram; Shafer's Textbook of Oral Pathology, 5 Edition.

*** Reader, ** Interne, *** Lecturer,
**** Sr.Lecturer, ***** Professor ,**

**Dept of Oral & Maxillofacial Pathology,
Mar Baselios Dental College, Kothamangalam**

IDA KCON 09
42nd Kerala State Dental Conference
Conducted under the flagship of IDA Kerala State
20, 21, 22 - November 09
HOTEL GATEWAY - (TAJ)
P.T. Usha Road, Calicut

Date:
20, 21, 22 November 2009

Venue:
Hotel Gateway - (TAJ)
P.T. Usha Road, Calicut

42nd Kerala State Dental Conference Highlights:

- Themed Conference.
- 1000 plus Dental surgeon's participating
- Pre-Conference courses in Dental Colleges
- Scientific sessions (paper/poster presentations)
- Fully Air conditioned Trade fair with all amenities. (Food courts etc)
- Grand Banquet

Special early bird prizes for Reception Committee Registrations (Before 15th April)
Register early and be a winner in the lucky dip - Exciting Prizes worth Rs. 50,000/-

Scientific program is the most important component and objective of any conference. In IDA KCONs we are trying to offer a basket of innovative pre conference courses to cater the different needs of delegates. The scientific workshops provide opportunities of learning for dentists both beginners and experienced alike. Pre conference courses are scheduled in the near by dental colleges.

Trade Fair
Hundred Air conditioned stalls with warm hospitality to Traders.
All the stalls are under the same roof with all other amenities needed for the traders.

Team Work - Treatment Possibilities

Check out the Registration form at - www.idakcon.org

Case report

Management of oral lichen planus

* Shilpashree S., ** Ipe Varghese, *** Shameena P.M., **** Sudha S., ***** Reshmi.G.Nair

Abstract

Lichen planus is a chronic non infectious inflammatory disease affecting skin, oral and genital mucosa. It is an immune-mediated disorder which also shows genetic predisposition. The malignant potential of this disease is controversial; however some researchers believe that about 1% of cases undergo malignant transformation. This has increased the need for early diagnosis and prompt treatment planning to reduce the morbidity associated with the disease. This article enumerates the current treatment modalities for oral lichen planus along with some of the newer drugs in vogue.

Another allergic disorder mimicking lichen planus is the lichenoid reaction. It should be carefully differentiated from Oral Lichen Planus (OLP) as the etiology associated with it could be contact with drugs or dental restorative materials and the treatment is to change the offending drug or the restoration.

Introduction

Lichen planus first described by Erasmus Wilson in 1869, is a chronic non infectious inflammatory disease affecting skin, oral and genital mucosa.¹ A number of factors have been implicated in the etiology of the disease including T-cell mediated immune disorder, genetic predisposition, association with stress/psychologic disorder,² extrahepatic manifestation of hepatitis-C virus infection etc.³

The overall prevalence of the lesion among Indians was 1.5% and 3.7% among those with mixed habits and 0.3% in non users of tobacco. The Relative risk for oral lichen planus was as high as (13.7%) in patients who smoked and chewed tobacco.⁴ Reported literature of date suggests that half of the patients with skin lesions have associated oral lesions & about 25% of patients present with oral lesions alone. The lesion affected 0.5-1% of general adult population.⁵ The potentiality of the lesion to undergo malignant transformation is still under review. However, literature suggests that 1% of cases undergo malignant transformation in 5yrs. The lesion shows a female predilection with the ratio being 1.4:1 and age of occurrence being more than 40 yrs though children and adult are also affected.¹ A similar lesion called lichenoid reaction also occurs in oral cavity but the etiology associated with it can be drugs, dental restoration like amalgam, composite etc.

Clinical features

The chief complaint of the patient in oral lichen planus is usually burning sensation and the most common site of occurrence is found to be posterior buccal mucosa followed by other sites including tongue, gingiva, retromolar area, vestibule, palate, floor of the mouth and lip.

Oral lesions are usually bilateral with varied pattern of appearance including atrophic, bullous, erosive, papular, plaque like or reticular. Of the above mentioned types atrophic and erosive forms are often sensitive or painful. The lesion has a characteristic clinical appearance presenting typically as radiating white or gray reticular patches with tiny white elevated dots at the intersection of these white lines which are called the Wickham's striae. These lesions are not persistent and may wax and wane over weeks or months. The lesions on gingiva present as desquamative gingivitis.

Skin lesions are associated with intense pruritis and may appear concomitantly with oral lesion and manifests as flat topped violaceous papules affecting flexor surfaces of wrist and forearm, inner surface of knees, thigh and trunk. Scalp, nail and conjunctival involvement also has been reported.

Differential diagnosis

This lesion should be differentiated from other white lesions occurring in the oral cavity like

- Leukoplakia which is seen as a white patch that cannot be attributed to any other cause except for the use of tobacco.
- Lichenoid reaction - occurs unilaterally and associated with a history of drug intake or seen adjacent to dental restorations like amalgam or composite.
- Candidiasis - confirmed with the help of candida smear.
- Lupus erythematosus - has a flaky and leathery appearance. No reticular pattern present.
- Ectopic geographic tongue- a wandering lesion associated with yellowish white scalloped border surrounding an erythematous area.

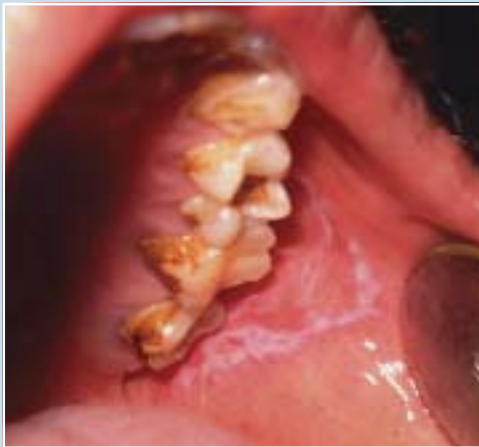

Fig. 1. Lichen Planus on Buccal Mucos

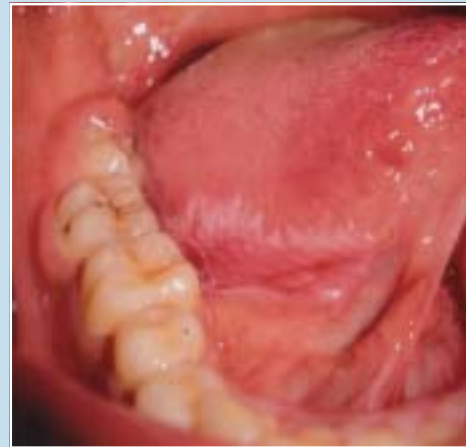

Fig. 2. Lichen Planus on Tongue

- Cheek bite/Linea alba - associated with history of trauma and usually seen at the level of occlusal plane of the molars and premolars.
- Erythema multiforme - Concentric ring like lesions with varying shades of erythema.

Management

Rationale for the treatment should include reassurance and providing relief for the patient & to improve the functioning as in eating, speaking etc and to prolong the time interval between exacerbations.

If the lesion is symptomatic then anti-fungals like Candid V6 oral rinse for 2wks are prescribed initially before commencing the treatment of OLP to rule out candidiasis.

First line of drugs used in the management of oral lichen planus includes Corticosteroids, which are the most predictable and successful drugs in the control of signs and symptoms of OLP. Because of the potential for side effects with this group of drugs, close collaboration with the patient's physicians is recommended before they are prescribed. Topical high potency corticosteroids like Betnesol (betamethasone) 0.5 mg/ml drops applied thrice daily with cotton swab or impregnated with gauge or triamcnenolone acetonide (Tess, kenacort) 0.1% to be applied twice or thrice daily can be prescribed. Discontinue when asymptomatic. Extensive erosive lesions on gingiva can be treated using occlusal splint as carriers for topical steroid. But long term use of topical steroid (for a period more than 2wks) may result in mucosal atrophy, secondary candidiasis and may also increase the potential for systemic absorption. Therefore concomitant prescribing of antifungal therapy along with topical steroid may be necessary. Systemic steroids are given for the treatment of severe exacerbations or for short period recalcitrant cases that fail to respond to topical steroid or if there is multisite involvement. Side effects of corticosteroids

include burning, itching, irritation, dryness, and secondary infection in the area of application. immunosuppressant drugs like topical Tacrolimus (Tacroz 0.1%) is applied by rubbing gently over the affected area can be used in severe persistent ulcerative lichen planus and the side effects include increased incidence of herpes simplex and zoster infection,⁶ however the use of Cyclosporine A which is also an immune suppressant remain controversial.

Other adjuvant drugs that can be used include systemic and local anti-inflammatory agents for local pain relief. In some cases concomitant topical anaesthetics, antifungal agents like topical Miconazole etc. can be prescribed. Topical retinoids like Tazrotene 0.1% gel are used in hyperkeratotic OLP⁷ and the side effects include dryness and transient burning sensation. Azathioprine is used in the treatment of erosive and generalized OLP by dermatologists for severe recalcitrant disease.⁷ Dapsone has been used in the treatment of erosive oral LP, especially those cases which do not respond to conventional steroids.⁷ Reports suggest that Glycyrrhizin is effective in treatment of OLP patients with chronic hepatitis C infection.⁸ Topical Hyaluronic acid 0.2% for every 4hr can also give some relief.⁹ Cryosurgery and carbon dioxide laser ablation have been suggested in the treatment of multicentric lesions of oral LP. Excision can be done for isolated plaques or nonhealing erosions but should not be the primary method of treatment as the inflammatory lesion may recur.¹⁰ Localised areas of erosive OLP showed complete disappearance with free soft tissue graft and did not recur during 3-5 yr follow up.⁷

Along with pharmacological management, strict maintenance of oral hygiene is recommended with nonabrasive dentrifices and avoidance of alcohol containing mouth washes to reduce the severity of symptoms.

Quiescent, asymptomatic reticular and plaque forms

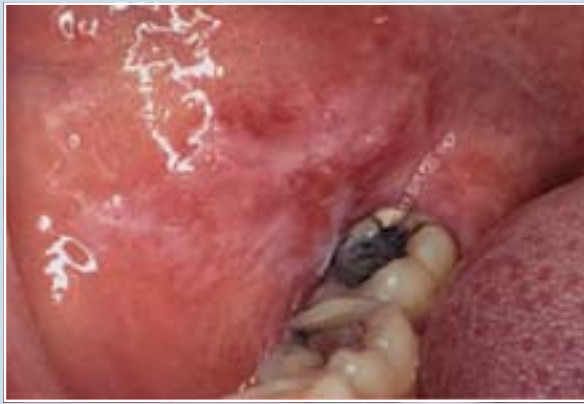

Fig. 3. Pre Treatment - Lichenoid reaction to amalgam restoration

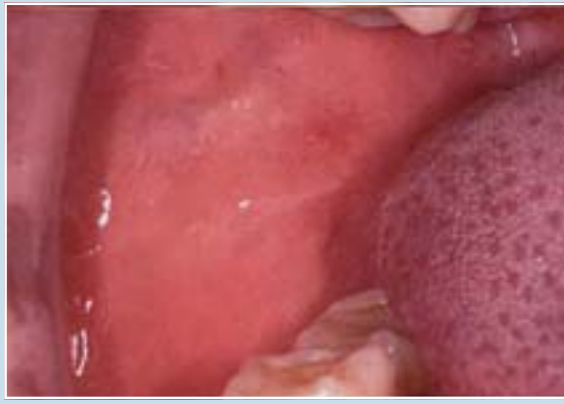

Fig. 4. Post treatment - Lichenoid reaction

do not warrant pharmacological intervention but erythematous and erosive forms are associated with high degree of morbidity. Treatment is mainly aimed at reducing the severity and length of these episodic outbreaks.

Lichenoid reaction

A lesion similar to lichen planus which occurs as an allergic reaction towards some drugs either by ingestion or contact with certain chemicals called lichenoid reaction is also seen in oral cavity. They have to be distinguished from idiopathic lichen planus (where cause is not known). This lesion is unilaterally occurring and seen in sites not typical of classic lichen planus, for eg. Palate.

Some of the drugs inducing such an effect are:

- Anti hypertensive drugs - Beta blockers, ACE inhibitors, Chlorothiazide
- Oral hypoglycemics - Chlorpropamide, Tolbutamide
- Non steroidal anti inflammatory drugs - Ibuprofen
- Pencillamine
- Tricyclic antidepressants
- Antimicrobials - Dapsone, Streptomycin, Tetracyclins.¹¹
- Antiparasitic drugs - Antimony compounds, Chloroquine
- Antiarthritic drugs - Aurothioglucose, Colloidal gold
- Anxiolytics - Lorazepam

Rationale for the therapy is to change the offending drug. Lichenoid reactions are sometimes seen due to contact sensitivity near amalgam and composite restorations. Then replacement of such restorations should be considered.

Conclusion

Lichen planus is therefore a manageable disease and

treatment is mainly aimed at reducing the morbidity associated with the lesion. Corticosteroids being the first drug of choice are used to treat and control the severity of lesions but a constant monitoring of the disease is required because of its supposedly premalignant nature. The clinician should also distinguish between lichen planus and lichenoid reaction, which is associated with drugs or a chemical where the treatment is to stop the offending drug.

References

1. Sugarman P. Oral Lichen Planus. emedicine Updated: Feb 22, 2007
2. L Manolache, Lichen Planus patients And Stressfull Events. J European Acad Dermatol Venerol 2008 vol 22 issue 4 pages 437-441
3. Pilli M. Oral lichen planus pathogenesis: a role for HCV specific cellular immune response. Hepatology 2002; 36(6): 1446-52.
4. Rajendran R. Oral lichen planus. J Oral Maxillofac Pathol 2005; 9: 3-5.
5. Shaffer's Diseases of Skin. Text Book Of Oral Pathology 6th edn Elsevier 2009 pg 799.
6. Current index of medical specialities CMP medical India private limited october 2006 pg 605.
7. Lodi G. Current controversies in oral lichen planus: Report of an international consensus meeting. Part 2: Clinical management and malignant transformation. Oral Surg Oral Med Oral Pathol Oral Radiol Endod 2005; 100: 164-78.
8. Nagao Y, Sata M. Effects of glycyrrhizin for oral lichen planus in patients with chronic hepatitis infection. J Gastroenterology 1996; 31(5): 691-695.
9. Nolan A. The efficacy of topical hyaluronic acid in the management of oral lichen planus. J Oral Pathol Med 2009; 38(3): 299-303.
10. Sumairi BI. Oral lichen planus and lichenoid reaction: etiopathogenesis, diagnosis, management and malignant transformation. J Oral Science 2007; 49(2): 89-106.
11. Abdolali M. A Review Of Drug Induced Oral Reaction. J Contemp Dent Practice 2002; 4: 10-31.

* P.G .Student, ** Principal, *** Prof & H.O.D,
**** Asst. Prof, ***** Senior lecturer, Dept. Oral
Pathology, Govt. Dental College, Kozhikode

Three rooted mandibular first molar with four canals

* Abhishek Parolia, ** Kundabala M., * Manuel S Thomas, * Mandakini Mohan, *** Neera Joshi,

Abstract

A mandibular first molar with two distal roots is an interesting example of anatomic variation. This paper describes case reports of mandibular first molar with three roots (one mesial and two distal) and four canals (two in mesial and one in each distobuccal and distolingual root). The canals were shaped with protaper rotary files and irrigated with 5.25% sodium hypochlorite, 0.2 %w/v of chlorhexidine gluconate and normal saline as the final irrigant. The canals were then obturated with gutta-percha and AH plus sealer. This case report presents an anatomic variation of internal morphology of the tooth and points out the importance of searching for additional canals.

Introduction

For root canal treatment to be successful, it is necessary to locate all root canals, debride them thoroughly and seal them completely with an inert root filling material. Unfilled canals remain a nidus for infection and can compromise treatment outcome. A clinician should be aware of the internal morphology of permanent teeth and the possible variations which may be encountered. Permanent first molar teeth are frequently affected by caries at an early age and may require root canal treatment for long-term retention. The morphology of both permanent first molars has been studied and it is accepted that the mesiobuccal root of maxillary first molars and the distal root of mandibular first molars often have more than one canal. In general, the second canal of the distal roots of mandibular first molars is more easily located and treated than the second canal in the mesiobuccal root of maxillary first molars which tends to be elusive.¹ Recent studies reported a higher incidence of second canals in distal roots of mandibular permanent first molar than earlier studies²⁻⁶ (Table 1). This could be due to better awareness of morphology amongst clinicians and to a change in the shape of access cavities to a more

rectangular form as compared with the earlier triangular shape recommended. One other reason could be its inherent higher distribution in certain populations. Studies amongst the Asian populations have shown a greater tendency for a second canal in the distal roots of mandibular first molars compared with other populations.⁷ This is also true with in laboratory studies (Table 1). The presence of two distal roots is rare but does occur. This additional root that can usually be found distolingually was first mentioned in literature by De Moore et al⁸ was called “radix entomolaris” (RE).⁹ An RE was found on the first, second and third mandibular molars, occurring least frequently on the second molar.⁹ Some studies reported a bilateral occurrence of the RE from 50% to 67%.^{10,11} The presence of three rooted mandibular first molar appears to be less than 3 % in African Americans,¹² about 3 % to 4.2% in caucasians,¹³ less than 5 % in Eurasians and Asians populations, and approximately 5 % to more than 30 % in mongoloid traits^{10,14} (Table 2).

The present report describes a case which has undergone root canal treatment in mandibular first molar with three roots (one mesial, two distal that is distobuccal and an additional distolingual (radix entomolaris -type I) and four canals (two mesial and two distal).

Table 1 Incidence of two canals in distal root of mandibular first molar

Author/ Year	% of canals	Population group
Skidmore and Bjorndal (1971)	28.9	Caucasians
Vertucci and Williams(1974)	30	Caucasians
Yew and Chan (1993)	31.5	Chinese
Zaatar et al (1997)	29.9	Middle East
Gulabivala et al (2001)	20	Burmese
Gulabivala et al (2002)	33.4	Thai
Sen et al (2004)	46	Turkish

Table.2 Prevalence of three rooted mandibular first molars- survey of available studies

Author/year	% of total	Population group
Taylor (1899)	3.4	United Kingdom
Tratman (1938)	5.8	Chinese
Tratman (1938)	0.2	Indians
Skidmore and Bjorndal (1972)	2.2	Caucasians
Yones et al (1990)	2.92	Saudi
Loh (1990)	7.9	Chinese (Singapore)
Yew and Chan (1993)	21.5	Chinese
Sperber and Moreau (1998)	3.0	Senegalese
Gulabivala et al (2001)	10.1	Burmese

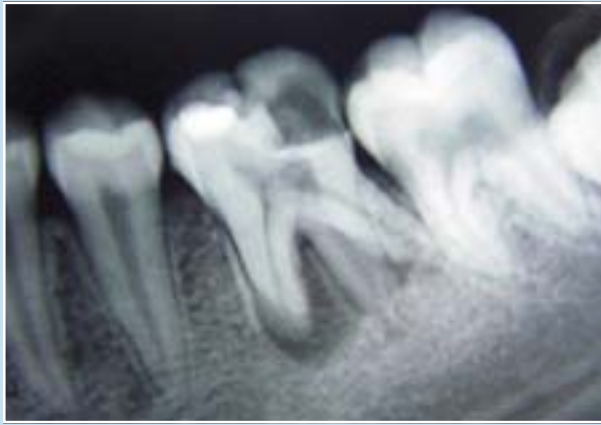

Fig. 1a. Diagnostic radiograph; an additional distal root was presented

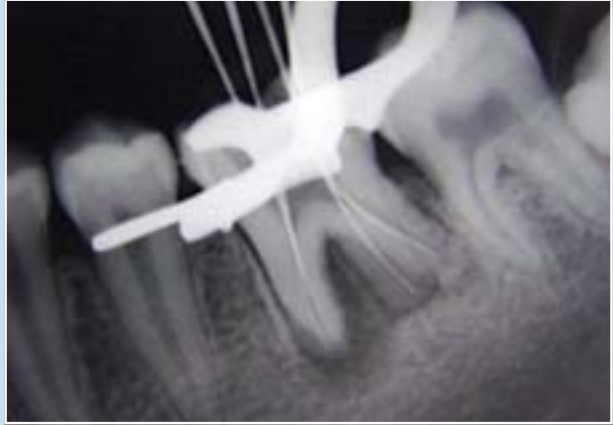

Fig. 1b. An initial radiograph for working length determination

Case 1

A 35 year old male patient was reported to the Department of Conservative Dentistry and Endodontics, Manipal College of Dental Sciences, Mangalore, India with a complaint of pain on chewing in right lower back tooth. On clinical examination there was gross decay in mandibular right first permanent molar (#46). Tooth showed negative response on vitality testing, and was tender on percussion. Intra oral periapical radiograph revealed the presence of periapical radiolucency around both mesial and distal roots. This radiograph also showed that the tooth had an additional distolingual root (Fig.1a). Diagnosis of symptomatic apical periodontitis was made and root canal treatment was recommended. Local anesthesia (inferior alveolar nerve block) was performed. The tooth was isolated by a rubber dam, and then the access cavity was prepared with distolingual extension to provide proper access to distolingual canal. After finding orifices of the canal, a radiograph was taken to determine the working length of the canals with two instruments in mesial root and two instruments in the distal roots (Fig. 1b). Shaping and cleaning was performed using rotary pro-taper files (DENTSPLY, Maillefer, Swiss made CH-1338 Ballaigues) in crown down manner. Apical preparation was done till size F3 protaper file (master apical file). The canals were irrigated with 5.25% sodium hypochlorite, 0.2%w/v chlorhexidine gluconate (Vishal Dentocare PVT, LTD India) during instrumentation and finally with normal saline. The canals were then dried with paper points, master cone selection radiograph was taken (Fig.1c), and obturated with laterally condensed gutta percha (DENTSPLY, Maillefer, Swiss made CH-1338 Ballaigues) and AH plus sealer (DENTSPLY DeTrey GmbH, Germany) (Fig.1d). Post endodontic restoration was placed and patient was recalled for follow up and full coverage crown.

Discussion

The internal anatomy of tooth is not always similar. A great number of variations could occur in number of roots and their shape. Most dentists are used to treating normal roots with similar traits; as a result, many failures can occur. However it must be noticed that abnormalities are rare, but it is possible that a patient referred may have one of these rare anatomic variations. The above case report reminds us that during each procedure clinician must expect variations, which may affect the treatment outcome. This case report has described mandibular first permanent molar with one mesial root and two distal roots (distobuccal and distolingual). The mesial root had two canals (mesiobuccal and mesiolingual) and two distal roots with one canal each. One of the variations that can occur in mandibular first molars is radix entomolaris.⁹ RE is a supernumerary distolingual root with various occurrences in different populations ranging from 3% of the African population¹² to more than 30% of the mongoloid population.¹⁴ The etiology behind the formation of RE is still unclear. In dysmorphic supernumerary roots, its formation could be related to external factors during odontogenesis or presence of an atavistic gene or polygenetic system.⁸ According to Quackenbush,¹⁵ the extra root occurred unilaterally in approximately 40% of all cases and predominantly on the right side. This is also likely to be true, because we found both these cases on the right side. The incidence of first mandibular molars with three distal roots is unknown. In cases of a mandibular first molar with two distal roots, the distolingual root is smaller than the distobuccal root and is usually curved.¹⁶ But in these present cases both distolingual roots were straight (type-I radix entomolaris).⁸ In most right mandibular molar with two distal roots, a clinician should always check for an additional canal specially in distobuccal root. There

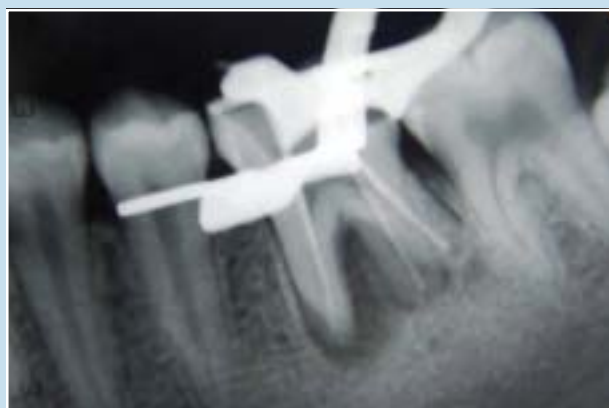

Fig. 1c. Master cone selection

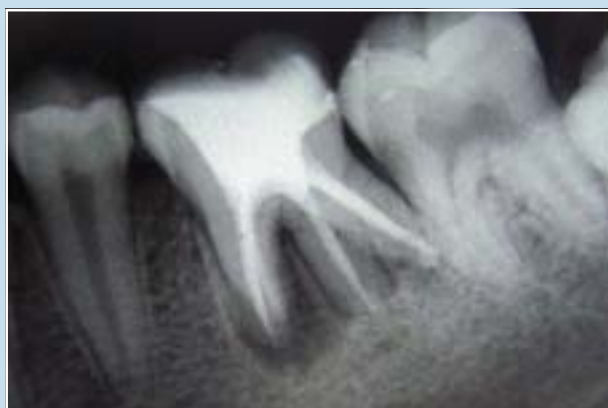

Fig. 1d. The final radiograph; all four canals obturated

are various methods to locate additional canals, these are as follows-

1. Knowledge of law of symmetry and law of orifice location¹⁷
2. Tactile sensation with hand instrument
3. Using various instruments like endodontic explorer, path finder, DG 16 probe and micro-opener
4. Champagne effect-bubbles produced by remaining pulp tissue in the canal, while using sodium hypochlorite in pulp chamber
5. Introral periapical radiograph
6. Digital radiography
7. Using fiber-optic illumination dental endoscopy and orascopy
8. Using surgical loupes
9. Using Operating microscope
10. Micro Computed Tomography
11. Visualization endograph using Ruddle's solution
12. Magnetic Resonance Microscopy

In the present case there was single canal both in distobuccal and distolingual root.

Conclusion

The high frequency of a fourth canals in mandibular first molars makes it essential to anticipate and find all canals during molar root canal treatment. The possibility of an extra root should also be considered and looked for carefully. Proper angulation and interpretation of radiographs help to identify chamber and root anatomy. In the case of an RE the conventional triangular opening cavity must be modified to a trapezoidal form in order to better locate and access the distolingually located orifice of the additional root.

References

1. Hartwell G, Bellizzi R. Clinical investigation of in vivo endodontically treated mandibular and maxillary molars. *J Endod* 1982; 8:555-7.
2. Al Nazhan S. Incidence of fourth canal in root canal treated mandibular first molars in a Saudi Arabian sub-population. *Intl Endod J* 1999; 32: 49-52.
3. Gulabivala K, Aung TH, Alavi A, Ng YL. Root and canal morphology of Burmese mandibular molars. *Int Endod J* 2001; 34:359-70.
4. Wasti F, Shearer AC, Wilson NHF. Root canal systems of the mandibular and maxillary first permanent molar teeth of south Asian Pakistanis. *Int Endod J* 2001; 34:263-6.
5. Gulabivala K, Opananon A, Ng YL, Alavi A. Root and canal morphology of Thai mandibular molars. *Int Endod J* 2002; 35:56-62.
6. Sert S, Aslanalp V, Tanalp J. Investigation of the root canal configurations of mandibular permanent teeth in the Turkish population. *Int Endod J* 2004; 37: 494-9.
7. Pattanshetti N, Gaidhane M and Al Kandari A. M. Root and canal morphology of the mesiobuccal and distal roots of permanent first molars in a Kuwait population – a clinical study. *Int Endod J* 2008; 41:755-762.
8. De Moore RJ, Deroose CA, Calberson FL. The radix entomolaris in mandibular first molar: an endodontic challenge. *Int Endod J* 2004; 37:789-99.
9. Calberson FL, De Moore RJ, Deroose CA. The radix entomolaris and paramolaris: clinical approach in endodontics. *J Endod* 2007; 33:58-63.
10. Yew SC, Chan K. A retrospective study of endodontically treated mandibular first molars in Chinese population. *J Endod* 1993; 19:471-3.
11. Steelman R. Incidence of an accessory distal root on mandibular first permanent molars in Hispanic children. *ASDC J Dent Child* 1986; 53:122-3.
12. Sperber GH, Moreau JL. Study of the number of roots and canals in Senegalese first permanent mandibular molars. *Int Endod J* 1998; 31:117-22.
13. Curzon ME. Three rooted lower molars in man and their racial distribution. *Br. Dent J* 1973; 52:181-3.
14. Walker RT, Quackenbush LE. Three rooted lower first permanent molars in Hong Kong Chinese. *Br. Dent J* 1985; 159:298-9.
15. Quackenbush LE. Mandibular molar with three distal root canals. *Dent traumatol* 1986; 2: 48-9.
16. Weine FS. Access cavity preparation and initiating treatment. In: Weine FS, ed *Endodontic Therapy*, 3rd edn. St. Louis, MO, USA: The C. V. Mosby Company 1982, 207-55.
17. Krasner P, Rankow H. Anatomy of pulp chamber floor. *J Endod* 2003;30(1):5-16.

* Assistant Professor, ** Professor and Head, * Assistant Professor, * Assistant Professor, *** Specialist Resident, Department of Conservative Dentistry and Endodontics, Manipal College Dental Sciences, Mangalore

Case Report

Myiasis

* Anjana Ravindran, ** Joseph Edward

Abstract

Myiasis involves invasion of vital tissue of humans or other mammals by fly larvae. The eggs deposited by the flies hatch into larvae, which burrows deep into tissue and destroy it. It is an uncommon clinical condition, being more prevalent in underdeveloped countries and hot climate regions. There is a higher risk of infestation in individuals with poor hygienic conditions, suppurative oral lesions, senility, mouth breathing during sleep, alcoholism, paralysis. This article presents a case of oral myiasis associated with squamous cell carcinoma of lower lip. The patient's management was debridement of larvae, antiseptics, and general care. Our case illustrates the need of educating people about good hygiene and proper sanitation in tropical countries

Introduction

German entomologist Fritz Zumpt defined myiasis as "an infestation of live human and vertebrate animals with dipterous larvae which feed on the host's dead or living tissue, liquid body substances or ingested food."¹ Two different classifications of myiasis can be adopted. The classical classification describes myiasis by the infected area of the host. According to ICD-10 Myiasis (B87) is classified into²

- Cutaneous myiasis (B87.0)
- Wound myiasis (B87.1)
- Ocular myiasis (B87.2)
- Nasopharyngeal myiasis (B87.3)
- Aural myiasis (B87.4)
- Myiasis of other sites (genitourinary & intestinal) (B87.8)
- Myiasis unspecified (B87.9)

The other classification based on the relationship between the host and the parasite can be described as obligatory, facultative or accidental.³ The eggs deposited by the flies hatch into larvae, which burrows deep into tissue and destroy it. It is an uncommon clinical condition, being more prevalent in underdeveloped countries and hot climate regions. There is a higher risk of infestation in individuals with poor hygienic conditions, suppurative oral lesions, senility, mouth breathing during sleep, alcoholism, paralysis. This article presents a case of oral myiasis associated with squamous cell carcinoma of lower lip.

Case report

An eighty-two year old male patient reported to our out-patient department with long standing ulcer and blood stained discharge from his lower lip (Fig 1). He complained of worms crawling out of the ulcer since 2 days. Medical history revealed Carcinoma tongue

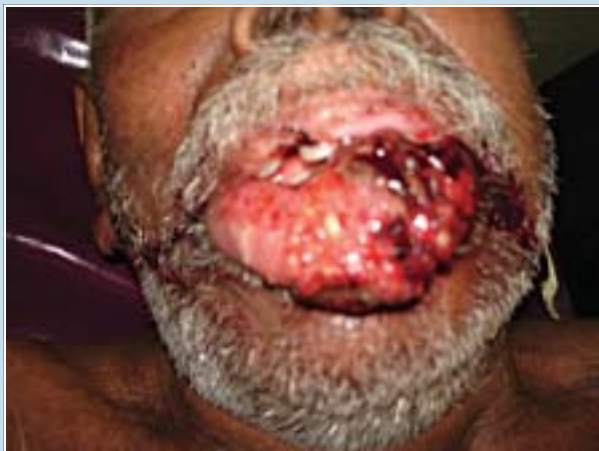

Fig. 1. Ulcer of the lower lip

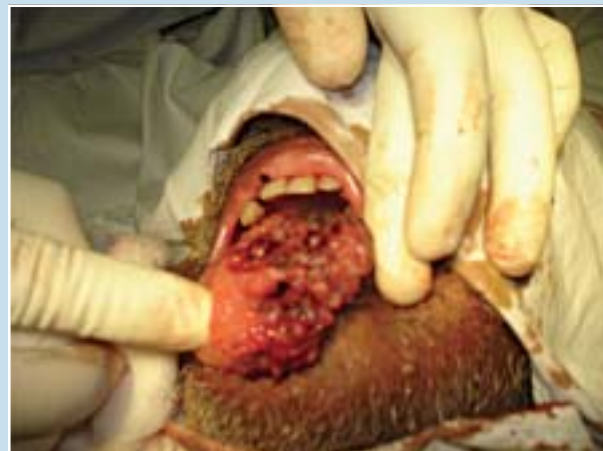

Fig. 2. Larvae in the necrotic slough

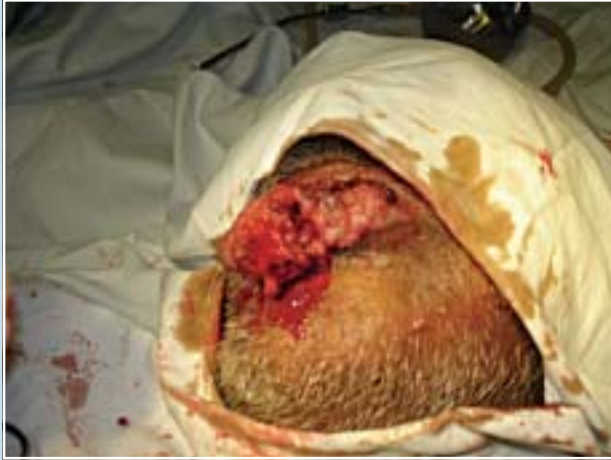

Fig. 3: Erythematous surrounding area

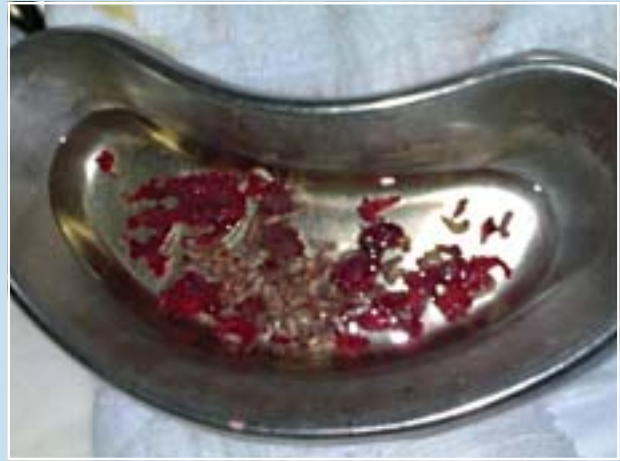


Fig. 4: Collected Larvae

(lateral margin) and partial glossectomy done 4 years back. On examining ulcer on lower lip, dozens of larvae were present in a necrotic slough (Fig 2). The surrounding area was erythematous and swollen (Fig 3). Intra oral examination revealed poor oral hygiene. Under local anesthesia the area was thoroughly explored. The larvae were found infiltrating deep tissues from lower lip to the region of symphysis on both sides. Initial debridement of larvae was done with turpentine oil. They were removed one by one with the help of tweezers (Fig 4). Each measured 8mm in length. Invasive curettage and soft tissue debridement was done along with turpentine wash. Antibiotic therapy was started. Patient was administered cephalosporins and metronidazole. The following day on examination larvae were found burrowing deeper planes in the mental foramen region. The ulcer was irrigated with turpentine and saline, about 20-25 larvae were removed. This procedure was continued for 1 more day and the ulcer was completely debrided of larvae. Soft tissues removed at time of debridement were sent for histopathological examination, report came as squamous cell carcinoma. Patient was not willing for further surgical intervention so he was referred to Regional Cancer Center for further treatment. He was followed up, after 5 months he died due to systemic complications and metastasis.

Discussion

Myiasis manifests as erythematous swelling, which often pulsates because of the movement of the larvae. The tissue becomes inflamed with or without ulceration and necrosis. Treatment of myiasis involves local and systemic measures. Local measures include application of larvicidal agents like turpentine, ether, chloroform, kerosene, ethyl chloride, butazolidine, creosote etc.⁴ Ulcerations or gingival burrows must be surgically explored, often multiple times to ensure adequate

debridement. Systemic measures include general care of patient and the use of broad spectrum antibiotics to prevent secondary infections.⁵ Shinohara et al⁶ and Osorio et al⁷ proposed the use of ivermectin, a macrolide antibiotic that is activated by gamma-amino butyric acid liberation, leading to parasites' death and their spontaneous elimination by washing out the larvae, thus avoiding mechanical removal and achieving lower morbidity.

Conclusion

Our case illustrates the need of educating people about good hygiene and proper sanitation in tropical countries. Infected patients should be exposed to relevant intervention as early as possible to prevent complications.

References

1. Zumpt F. *Myiasis in Man and Animals in the Old World*. London: Butterworths; 1965: 267
2. www.who.int/classifications/apps/icd/icd10online/?gb85.htm+b86
3. John, David and Petri, William. *Markell and Voge's Medical Parasitology: 9th Edition*. Missouri: Saunders Elsevier, 2006. p. 328-334.
4. Bozzo, L., Lima, I.A., de Almacida, O.S. *et al*. Oral myiasis caused by sarcophagidae in an extraction wound. *Oral Surg Oral Med Oral Pathol Oral Radiol Endod*. 1992; 74, 733-735
5. Baskaran M, Jagan Kumar B, Geeverghese A. Cutaneous myiasis of face. *J Oral Maxillofac Pathol* 2007; 11:70-2
6. Shinohara EH, Martini MZ, Oliveira Neto HG, Takahashi A (2004) Oral myiasis treated with ivermectin: case report. *Braz Dent J* 15, 79-81
7. Osorio J, Moncada L, Molano A, Valderrama S, Gualtero S, Franco-Paredes C (2006) Role of ivermectin in the treatment of severe orbital myiasis due to *Cochliomyia hominivorax*. *Clin Infect Dis* 43, e57-59

* BDS Student, ** Professor & Head, Department of Oral and Maxillofacial Surgery, Azeezia College of Dental Sciences & Research, Kollam

Case Report

Rehabilitation of advanced endo-perio lesions

* Hegde Deepak Divakar, ** Moksha Nayak, *** Rajesh Shetty

Abstract

This article describes the management of a patient presenting with a combined endo-perio lesion that was apparently treated adequately. The treatment was more complicated due to the chronicity of the lesion and attachment loss. The diagnosis of a true combined lesion allowed for a sequential treatment plan of endodontic therapy, root biomodification and periapical surgery with graft placement and splinting with use of adhesive technology for the restoration of functional and esthetic demands of the patient.

Introduction

A true combined lesion may be perplexing issue as it is indistinguishable from a primary endodontic and secondary periodontal condition and are treated initially as primary endodontic and secondary periodontal condition.¹

The prognosis of a true combined lesion is often poor when periodontal lesions are severe with extensive loss of attachment and resulting tooth mobility. Tooth stabilization and splinting have been done since ancient civilization to decrease tooth mobility, replace missing teeth, improve form and function and esthetics.² This case report illustrates an example of rehabilitating a tooth with an advanced endo-perio lesion.³

Case report

A 47 year old male patient reported to the Department Of Conservative Dentistry and Endodontics with the chief complaint of discolouration and mobility in upper front teeth (Fig-1). Dental history revealed a traumatic episode 20 years back. Patient had noticed a soft tissue swelling with pain 2 years back which subsided subsequently. Medical history revealed a fasting blood sugar of 190mg/dl and a habit of chronic smoking. Clinical examination revealed a discoloured tooth with reference to 21 with grade-3 mobility and no swelling. There was no draining sinus tract. Probing elucidated a pocket depth of 10 mm on the proximo-mesial aspect of 21. Pulp sensibility tests showed a negative response on 21. There was mild discomfort on vertical percussion. Radiographic examination revealed loss of lamina dura with angular bone loss on the mesial aspect and a well differentiated periapical radiolucency measuring around 1cm. After investigations a final diagnosis of a true combined endo-perio lesion was made.

Treatment objectives - Treatment goals were to resolve the endodontic pathology, control severe periodontitis and stabilize the mobile tooth with esthetic correction.

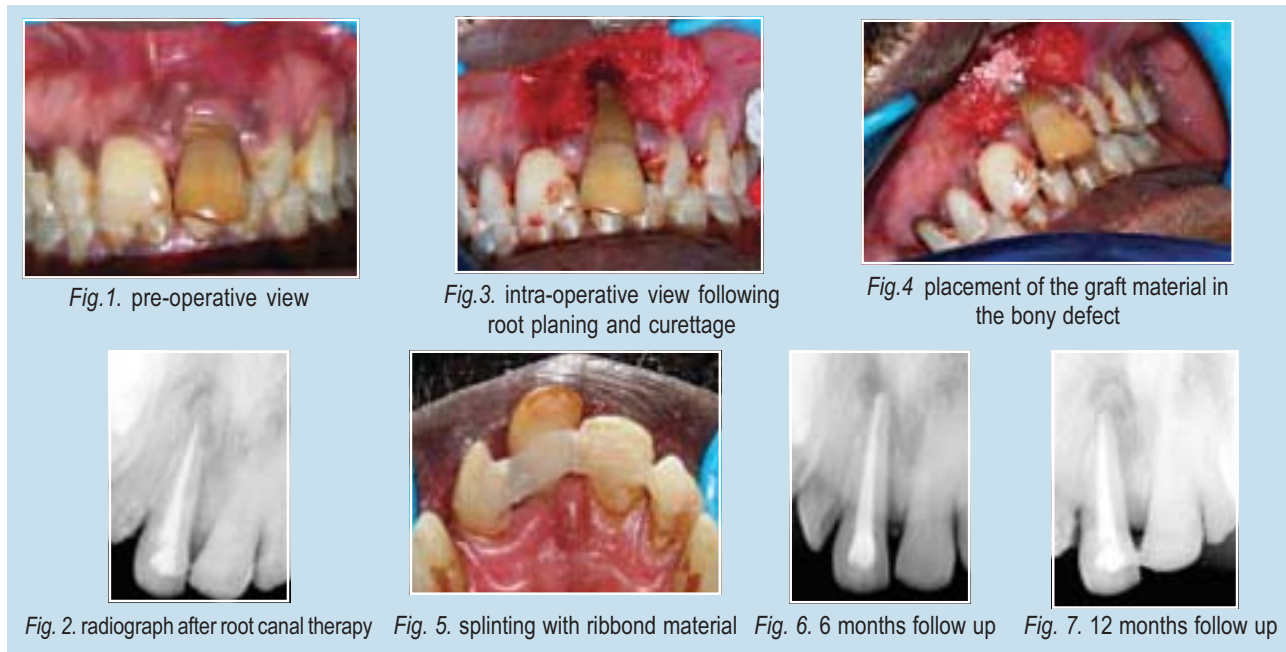
Treatment plan - The treatment plan included endodontic therapy with surgical intervention for the

periapical pathology and bone graft placement in the defect, root planning and curettage, splinting with ribbon material and composite veneer on 21.

Treatment progress - The treatment commenced with routine root canal therapy on 21 (Fig-2). The patient received general scaling of full mouth and root planing on 21. After achieving a stable periodontal status endodontic surgery was done. An esthetic papilla based flap was used for surgical approach. On reflection, dehiscence of the marginal bone was observed with calculus on the root surface of 21. Thorough root planing was accomplished followed by curettage of the periapical pathology (Fig-3). A combination of bioactive glass and hydroxyapatite bone graft (Grabio Glascera, Dorthom Medi Dents, India) was used to fill the bony defect (Fig-4). The root surface was treated with a solution of doxycycline and the flap was reapproximated and periodontal pack applied over the surgical area. The tooth was kept out of occlusion and patient advised to be on soft diet. After a week of uneventful healing the patient was scheduled for splinting. The lingual surfaces of the upper anterior teeth were acid etched and a woven polyethylene fiber splint (Ribbond®, Expodent, U.S.A) soaked in bonding agent was carefully adapted to the lingual fossa, covered by flowable composite and light cured (Fig-5). A direct composite veneer restoration was done on 21. The patient was scheduled for periodic checkup and radiographic evaluation at regular intervals (Fig. 6, 7).

Discussion

Establishing an accurate diagnosis is the first step to success in any therapy. The pathogenesis of a true-combined lesion is identical to the pathogenesis of primary endodontic and periodontal lesions.⁴ These independent lesions—the periapical lesion originating from the necrotic pulp and the periodontal lesion progressing apically eventually merge. These lesions are often indistinguishable from an advanced primary endodontic lesion with secondary periodontal involvement and/or a primary periodontal lesion with secondary endodontic involvement.²



Before the commencement of any kind of advanced restorative work to treat a perio-endo lesion extraction of the tooth should be considered as an alternative. The prognosis of the tooth should be considered carefully. Considerations include whether there is a functional need for the tooth or if it is possible to provide an adequate root filling (i.e. negotiable canals are present). Other important considerations are whether the tooth is restorable after the lesion has been treated, and patient suitability for lengthy, costly, invasive treatment with a need for high patient motivation. If any of these factors are deemed negative extraction is the treatment of choice. Dental implants are an alternative but are not advisable in patients with systemic complications like diabetes.

True-combined lesions are treated initially as for primary endodontic lesions with secondary periodontal involvement. Periodontal surgical procedures are almost always called for. Root amputation, hemisection or separation may allow the root configuration to be changed sufficiently for part of the root structure to be saved. Prior to surgery, palliative periodontal therapy should be completed and root canal treatment carried out on the roots to be saved.⁵ The prognosis of an affected tooth can also be improved by increasing bony support which can be achieved by bone grafting and guided tissue regeneration.^{6,7} This is due to the most critical determinant of prognosis being a loss of periodontal support. These advanced treatment plans are based on responses to conventional periodontal and endodontic treatment over an extended time period.

Periodontal splinting can be done with fixed partial dentures, orthodontic wires or tooth coloured resin filling materials. Recently strong flexible polyethylene fiber embedded splints have become available which are bonded to the teeth with adhesive technology.⁸ The result is strong, durable and esthetic splint. Splinting for

periodontal conditions in some cases can be maintained indefinitely for tooth stability.⁹

Conclusion

The decision to maintain or extract a gravely compromised tooth is a challenging task, especially today, with the access to the potential of replacing the tooth with a dental implant-based restoration. The clinical cases selected for this article demonstrate that in some clinical situations, the decision may be to attempt salvaging the tooth using a multidisciplinary team approach.

References

1. Walker MR. The pathogenesis and treatment of endo-perio lesions. CPD Dentistry 2001; 2(3):91-5.
2. Strassler HE, Haeri A, Gultz JP. New generation bonded reinforcing materials for anterior periodontal tooth stabilization and splinting. Dent Clin N Am 1999;43:105-24.
3. Lin YTJ, Kuo SC, Auyeung. The use of a resin bonded fixed splint in periodontally compromised mandibular anterior teeth: A case report. Int J Periodontics Restorative Dent 2005;25:385-91.
4. Jenkins WMM, Allan CJ. Guide to Periodontics. 3rd Edn. Wright 1994; 146-52.
5. Whyman R A. Endodontic-periodontic lesions management. Part 2; New Zealand Dent J 1988; 85: 109-11.
6. Zubery Y, Kozlovsky A. Two approaches to the treatment of true combined periodontal-endodontal lesions. J Endod 1993; 19: 414-416.
7. Tseng C *et al*; A new approach to the treatment of true-combined endodontic - periodontic lesions by guided tissue regeneration technique. J Endod 1996; 22: 693-6.
8. Strassler HE, Serio CL. Esthetic considerations when splinting with fiber reinforced composites. Dent Clin N Am 2007; 51:507-24.
9. Ritter AV. Talking with patients' periodontal splinting. J Esthet Dent 2004;14:329-30.

* PG Student, ** Principal and Head of Department, *** Associate Professor, Department of Conservative Dentistry and Endodontics, KVG Dental College, Sullia

Case report

Prosthetic rehabilitation of facial defect with silicone prosthesis

* Manju V., ** Anil Mathew, ***P.C. Jacob, **** Vinod P. Nair

Abstract

When maxillofacial ablative surgery is done, involving aesthetic areas of the face resulting in removal of significant quantities of tissue due to cancer, often plastic surgery is not able to recuperate the extensive area removed. In such cases rehabilitation with silicone prosthesis restore the esthetics & allow them to confidently face the society.

This 48 year old male patient is a case of recurrent maxillary adenoid cystic carcinoma. Initially prosthetic rehabilitation was done with silicone four years back. Due to recurrence of left para pharyngeal mass, prosthesis needed to be re-fabricated with reduced weight, even though the extension was more.

The various steps involved in prosthesis fabrication are impression procedure, sculpting, making mold and processing and staining silicone.

Introduction

Surgical reconstruction yields the best result when the tissue is malformed or misplaced, whereas prosthetic reconstruction yields the best result when the tissue is absent. Removal of an organ not only cause unaesthetic look but also there is a loss of function and has a psychological effect on the patient. Sometimes plastic surgery may not be able to build up the extensive area removed and moreover a long oncological observation period is sometimes necessary before any restorative plastic surgery can be performed. So prosthesis should be given as soon as possible for the appearance / esthetics and psychological wellbeing of the patient.

Case history

This 48 year old gentle man suffered from recurrent maxillary adenoid cystic carcinoma .He reported to head and neck institute of Amrita first in 2004.He underwent wide excision, reconstruction with rectus abdominus flap. Also he underwent orbital floor reconstruction with free radial forearm flap.

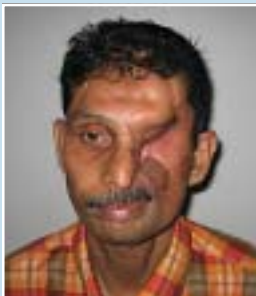After completing surgical procedures patient reported to the maxillofacial prosthetic clinic for restoration of defect with silicone prosthesis

Impression procedure and sculpting

Impression of the face was made with alginate and reinforced with plaster of paris. After getting the cast, sculpting done with utmost care. The edges of the wax pattern were thinned to merge with the remaining soft tissue. The portion of the wax that represented the palpebral fissure was re-contoured to form a smooth convex surface. A prefabricated eye shell whose shade matched with the contra lateral eye was selected. The position of the iris was determined with the help of landmarks making the patient look straight. Final impression of the defect made with light viscosity poly vinyl siloxane and supported with plaster of paris. Wax pattern obtained were properly adapted to the master cast.

Try in of wax pattern

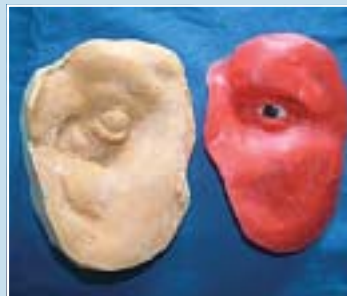The wax pattern was placed into the patients face to



Initial pre-operative



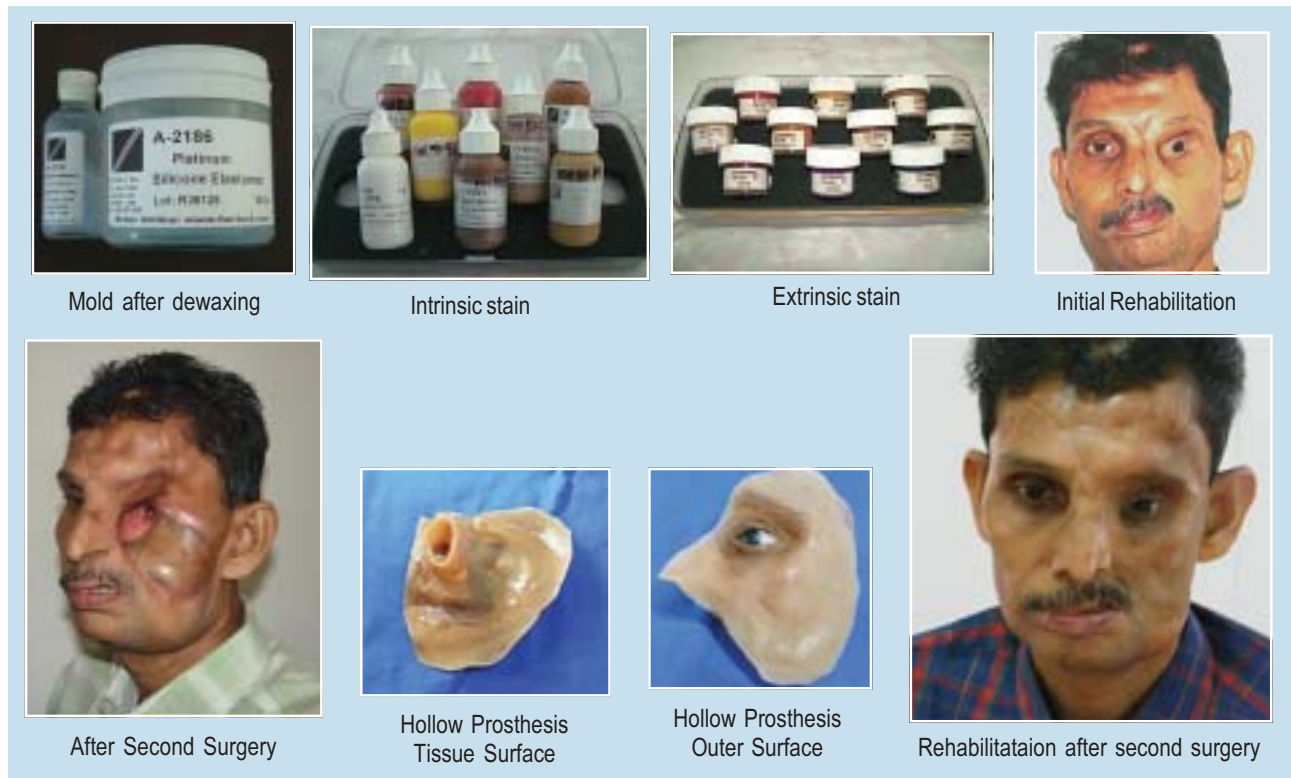Final Impression



Master Caste and Wax Pattern



Mold after dewaxing



check for proper contour and bulk. Necessary modifications were done until the soft tissue contour and the palpebral fissure resembled the patient's natural eye. Once the soft tissue and location of iris were satisfactory the pattern was removed and flasking done.

Processing and staining silicon

Invest the wax pattern with the master cast in the lower half of the flask and the counter part is poured in plaster of paris. After dewaxing ;while opening the flask care should be taken to secure the eyeshell firmly to one compartment of the flask. Room temperature vulcanization silicone (Factor II .com) was packed into the mould by mixing plastinum silicone elastomer and cross linker in 10 : 1 ratio after adding intrinsic stains. Intrinsic stain can be selected from patients basic skin colour. After curing recover the prosthesis, borders thinned to merge with the remaining soft tissues.

Then extrinsic staining was done to match the skin colour. Eye brows and eye lashes are attached using patients own hair. These steps make sure that the prosthesis restored the anatomy as normal as possible and helped him to confidently face the society

Refabrication of prosthesis following recurrence of tumour

The patient was on follow up and tumour recurred after three years. FNAC was done from the recurrent mass in 2007 and was reported as poorly differentiated Adenoid cystic carcinoma. The microscopy revealed lymphatic and peri-neural invasion and infiltration of

attached bone and skeletal muscle. So he had to undergo an extensive surgery which resulted in an all-embracing disfigurement.

Hollow prosthesis fabrication

Now the anaplastologist had a prodigious task. But the basics steps remain the same. The tissue surface of the prosthesis had to be made hollow in order to reduce the weight even though the extension of the prosthesis was more. For this the deep parts of the defect in the master cast were blocked out with plaster of paris before making the wax pattern.

The clinical follow up demonstrated how this type of prosthetic rehabilitation may be employed as a valid response to the psychological- functional need of the patient by giving an acceptable aesthetic recovery.

Certain properties of prosthetic materials are very important to achieve clinical success and patient acceptance especially in these type of cases.. These properties include colour stability, ease of fabrication, dimensional stability, edge strength .surface texture etc. Medical grade silicone is the best choice for getting aesthetic and functional outcome that restore the self esteem and confidence.

Bibliography

1. Buemer J, Curtis T A. Maxillofacial Rehabilitation; p. 431-49.
2. Taylor T Clinical Maxillofacial Prosthetics; p. 233-76.
3. Laney W R. Maxillofacial Prosthetics; p. 279-306.

*** Reader, ** Professor and Head, ***Former Professor and HOD, ****Chief technician, Dept. of Prosthodontics, Amrita Institute of Medical Sciences, Kochi, Kerala.**

Soft tissue management during second stage implant surgery

* Dipen Shah, ** Dilip Nayak, *** Ashitha Upoor

Abstract

In the 21st century the rationale of implant placement has extended from function to optimal esthetics and soft tissue health. Two stage implant protocol has the additional advantage of managing the soft tissues during second stage surgery. There are certain guidelines which may be helpful during the second stage surgery to achieve the satisfactory aesthetic outcome. This article describes various techniques to achieve maximum esthetics and preservation of tissue following second stage implant surgery.

Introduction

To achieve satisfactory aesthetic results, it is essential to obtain peri-implant soft tissue that is harmonious with the adjacent tissues in color, form, and contour.¹ However the soft tissue that closely surrounds the implant collar is delicate in nature and clinicians are required to handle the peri-implant soft tissues with exceptional care and mastering the techniques of manipulating the delicate peri-implant soft tissue architecture in the aesthetic zone is therefore considered mandatory.²

There are various soft tissue manipulation techniques that can be performed throughout the various stages of implant treatment. However, the second stage surgery provides a golden opportunity to the clinician to correct the soft tissue abnormalities in terms of esthetics and mucogingival considerations along with achieving its main objective of attaching the healing abutment or provisional restoration to the implant. One such routinely performed technique is buccally positioned envelope flap technique which provides excellent esthetics to the implant site which has been described in these case reports.

Case presentation

A 4.5 mm diameter implant (Frialit-2, Dentsply) was placed in the anterior maxillary area. During the reevaluation after 3 months mild tissue volume deficiency was noted on buccal side (Fig. 1). Decision was taken to use buccally positioned envelope flap technique, designed by Hyman Smukler and colleagues,^{3,4} during the second stage implant surgery to correct the deficiency.

Technique

A horizontal incision was given on the crest with no. 15C blade between the palatal line angles of the adjacent teeth. Intrasulcular incisions were placed on each adjacent tooth and vertical releasing incisions were avoided. A

full-thickness envelope flap was raised buccally using the periosteal elevator till the buccal portion of the cover screw was visible (Fig. 2). A semilunar palatal incision was placed on the palatal portion of the cover screw to fully expose the implant platform and enable proper seating of the healing abutment. The healing abutment was connected to the implant and the flap was stabilized in its buccal position by the healing abutment (Fig. 3). Two simple interrupted sutures were placed one at each papilla. (Fig. 4)

After suturing no. 15C blade was used to design the buccal gingival scallop and to draw the proposed buccal gingival margin at a more coronal level than on the adjacent teeth. This was done to obtain an excess of buccal tissue, as certain degree of apical recession is normally expected.⁵ Post surgical instruction was given to the patient and he was recalled after 7 days for suture removal.

The tissue was allowed to heal and stabilize for 3 months after which the permanent restoration was given to the patient. As shown the restoration shows excellent emergence profile of the restoration and correction of the buccal defect. This technique has incorporated excellent buccal gingival contour to the area.

(Fig. 6) is a showing a similar case with slight buccal ridge atrophy. So the same approach was utilized as it is indicated in esthetic areas. (Fig. 7) shows the improved buccal contour after suturing.

Discussion

Esthetics has emerged as significant criteria in defining the success of dental implants. Therefore considerable attention should be given to the techniques that manipulate the tissue for the desirable esthetic outcome. Buccally positioned enveloped flap is one such technique which can be performed in day to day implant practice.

Buccally positioned envelope flap technique is a brilliant attempt to idealize the peri-implant soft tissue

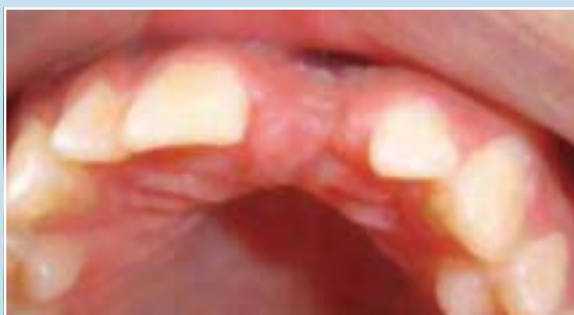

Fig. 1. Mild tissue atrophy can be observed on the buccal side of the edentulous ridge

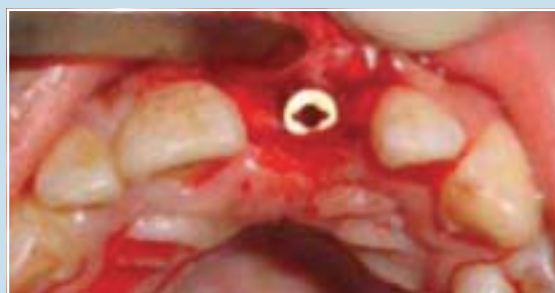

Fig. 2. Crestal incision was given between the palatal line angles of adjacent teeth and flap is reflected. A further semilunar incision was given to expose the implant head on palatal side

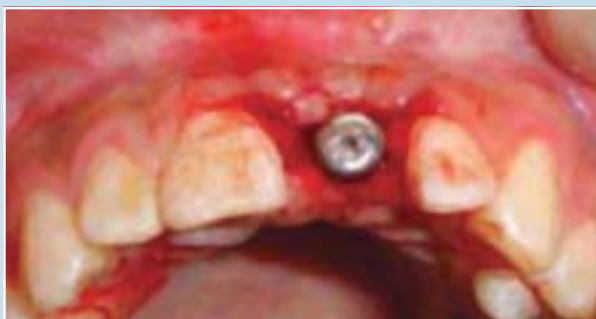

Fig. 3. Flap was stabilized on the buccal side at more coronal position with the help of healing abutment

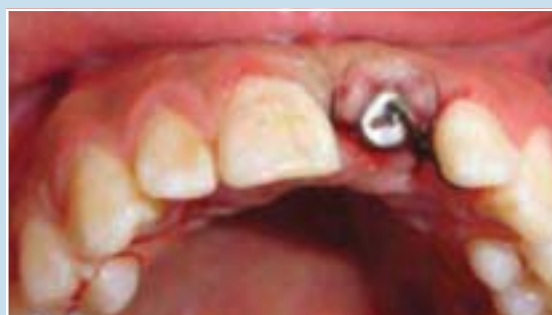

Fig. 4. Simple interrupted sutures were used and buccal flap was scalloped

profiles surgically. It is best indicated for single implants in the aesthetic zone, even though it can be used for multiple implants. It is also indicated when there is mild tissue volume deficiency on buccal side which is often encountered around an implant.

For this technique to succeed, it is important to evaluate preoperatively the amount of buccal keratinized tissue available. If the area has a lack of buccal gingival tissue, there is a risk of further reducing the tissue. Under this circumstance, either select a different approach (i.e., apically positioned flap) or augment the keratinized tissue (i.e., free gingival graft) before proceeding with the buccally positioned envelope flap.

The advantages of this technique include, establishment of good buccal contour, improved emergence profile of implant crown and better accessibility which enables confirmation of the correct seating of the abutment. However, there are certain disadvantages which suggest that this technique should be used following thorough diagnosis. These include increase in the peri-implant probing depth and increase in marginal bone loss.

The second stage implant surgery can also be performed by various other techniques. Broadly these techniques can be classified as tissue punch technique (flapless technique), flap techniques and various graft techniques.

Tissue punch technique, originally described by Dr. P-I. Brånemark⁶ entails excising a circular area of the keratinized mucosa on top of the implant cover screw either with B.P. blade or dedicated tissue punch. Advantages of this approach are minimal surgical trauma and post operative discomfort, no suturing, and immediate post operative maintenance by patient. There are certain important drawbacks associated which includes loss of 3-4 mm band of keratinized tissue, inability to correct any soft and hard tissue discrepancies and implant-bone interface is not visible.

Flap techniques include apically positioned flap technique and buccally positioned flap technique which is presented in this article. The biological price of this more invasive flap approach is counterbalanced by several advantages: it provides better access to the implant site, enabling confirmation of the correct seating of the abutment; the soft tissues can be properly thinned, reducing future probing depth; and the keratinized tissue can be preserved or even augmented. Preference should be given to apically positioned flap whenever there is lack of sufficient attached mucosa.

Whenever the peri-implant tissues are deficit in terms of tissue volume, gingival keratinization, or both, soft tissue grafting procedures should be considered. As far as possible, adequate peri-implant keratinized tissue should be obtained by adjacent sites by using pedicle

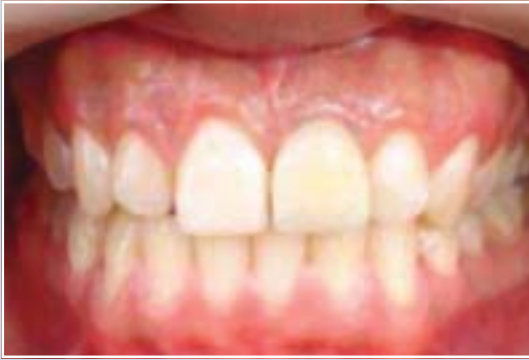

Fig. 5. Final restoration was given after 3 months. Correction of tissue atrophy can be observed.

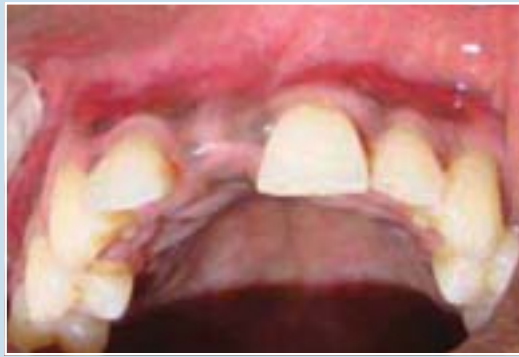

Fig. 6. Mild tissue volume deficiency on the buccal side of the edentulous area can be observed compared to adjacent areas.

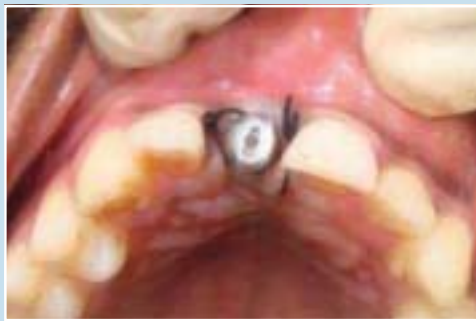

Fig. 7. Buccally positioned envelope flap technique was used. Improvement in buccal contour can be observed.

flaps.⁷ If the surrounding anatomy does not favor the sculpting of a pedicle flap, the alternative methods like free gingival graft,⁸ modified roll technique⁹ or connective tissue graft should be considered.¹⁰

Waiting period after second stage surgery

It is recommended that consideration should be given to the healing period after any soft tissue manipulation occurred, as oral soft tissues require an ample time to heal and mend. A three-month waiting period for the soft tissue to stabilize is recommended before selecting the final abutment or making the final impression after the second-stage surgery.¹¹

Conclusion

Although there is always less emphasis given to the second stage implant surgery, it provides an excellent opportunity to the clinician to correct esthetic appearance and mucogingival problems. Buccal positioned envelope flap technique is simple technique which can be utilized in day to day clinical practice to idealize the soft tissue morphology. Clinician should choose the uncovering technique that enables the optimal esthetics and soft tissue health.

References

1. Croll BM. Emergence profiles in natural tooth contour. Part I: Photographic observations. *J Prosthet Dent* 1989(62): 374-379.
2. Berman GR, Rapley JW, Hallmoon WW, et al. The periimplant sulcus. *Int J Oral Maxillofac Implants* 1993(8): 273-280.
3. Smukler, H., Castellucci, F., & Capri, D. The role of the implant housing in obtaining aesthetics: Generation of peri-implant gingivae and papillae. Part 1. *Practical Procedures and Aesthetic Dentistry* 2003 (15), 141-149.
4. Smukler, H., Castellucci, F., & Capri, D.T. The role of the implant housing in obtaining aesthetics. Part 2. Customizing the peri-implant soft tissue. *Practical Procedures and Aesthetic Dentistry* 2003 (15), 487-490.
5. Grunder, U. Stability of the mucosal topography around single tooth implants and adjacent teeth: One-year results. *International Journal of Periodontics and Restorative Dentistry* 2000 (20): 11-17
6. Garber, D.A., & Belser, U.C. Restoration-driven implant placement with restoration-generated site development. *Compendium of Continuing Education in Dentistry* 1995 (16), 796, 798-802, 804.
7. Moy, P.K., Weinlaender, M., & Kenney, E.B. Soft-tissue modifications of surgical techniques for placement and uncovering of osseointegrated implants. *Dental Clinics of North America* 1989 (33), 665-681.
8. Sullivan, H.C., & Atkins, J.H. Free autogenous gingival grafts. 1. Principles of successful grafting. *Periodontics* 1968 (6), 5-13.
9. Abrams, L. Augmentation of the deformed residual edentulous ridge for fixed prosthesis. *Compendium of Continuing Education in Dentistry* 1980 (1), 205-214
10. Langer, B., & Calagna L. The subepithelial connective tissue graft. *Journal of Prosthetic Dentistry* 1980 (44), 363-367.
11. Small PN and Tarnow DP. Gingival recession around implants: A 1-year longitudinal prospective study. *Int J Oral Maxillofacial and Implants* 2000(15): 527-532

* P G Student, ** Professor and Assoc. Dean, *** Professor and HOD, Department of Periodontics, Manipal College of Dental Sciences, Mangalore.

* Kalwa Pavankumar

Forensic Odontology

Forensic Odontology (which is also called forensic dentistry or bite mark evidence expertise) mainly involves the identification of an assailant by comparing a record of their dentition (set of teeth) with a record of a bite mark left on a victim. Forensic odontologists are highly experienced, specially trained dentists who use their expertise to help identify unknown remains and trace bite marks to a specific individual. They are board-certified specialists who deal primarily with bite mark evidence. Forensic odontologists or forensic dentists are typically called in to:

- ♦ Identify human remains that cannot be identified using fingerprints or other means
- ♦ Identify bodies in mass fatalities, such as plane crashes and natural disasters
- ♦ Determine the source of bite mark injuries, in cases of assault or suspected abuse
- ♦ Estimate the age of skeletal remains
- ♦ Testify in cases of dental malpractice

The forensic odontologist may be called in by police officers, the medical examiner or the coroner. In death cases, the forensic odontologist attends the autopsy and takes photographs, cranial measurements, dental impressions and x-rays from the remains. These exemplars are then compared to those of known missing individuals. If a match can be made, the remains can be identified. In cases where bite marks are found on the body of a victim or suspected perpetrator, or on food, chewing gum or another item, the forensic odontologist uses the same procedure to determine the source of the bite marks.

The forensic odontologist then writes a detailed report explaining what was done and what conclusions can be made. The forensic odontologist must be prepared to explain the process and justify the findings in court.

Working Conditions

1. Forensic odontologists usually work as regular dentists much of the time, performing forensic examinations as needed at the request of local law enforcement or the medical examiner.
2. In death cases, the forensic odontologist may go to the crime or disaster scene. Otherwise, the measurements and x-rays are taken as part of the autopsy.
3. Since crimes and disasters can happen at any time, a forensic odontologist “on call” must be ready to work long hours, day or night, on holidays and on

weekends.

4. The work is highly detailed, demands extremely fine motor skills and requires extraordinary precision and accuracy. Complex equipment, including computers, microscopes and other technologies, may be used in the identification process.

5. Forensic Odontology requires attention to detail and the ability to work patiently to complete a lengthy process step-by-step without rushing.

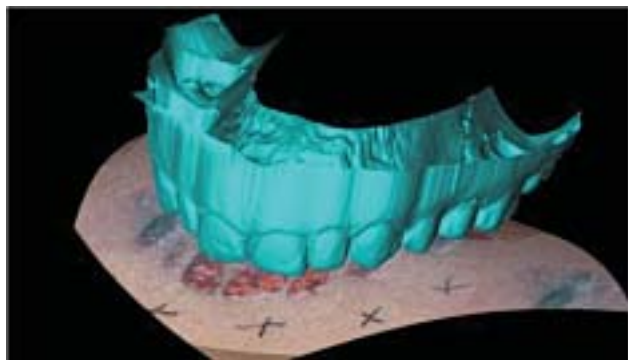
6. Accurate and complete records must be kept, and the forensic odontologist must be able to make conclusions based solely on the physical evidence available.

How forensic dentistry works

Forensic dentists are either called by medical examiners or police investigators. There’s a movement underway to set up emergency call-out procedures in many jurisdictions. What has happened is that someone has discovered a bite mark while conducting an autopsy or viewing the body at a crime scene. While the bite mark can be photographed or even excised from the decedent, it’s better to let the forensic dentist get there as soon as possible. One of the first things they’ll do is obtain a saliva sample from the bite. This, of course, can be done by others, but a forensic dentist can make sure sample extraction doesn’t affect quality of the bite mark. Next, the forensic dentist will take photographs. This is a technique shared by all experts, and it’s fairly important to get the lighting, color, and camera angle right. Next, the forensic dentist makes multiple impressions, casts, or molds of the bitemark, and has access to a variety of materials in which to choose the right gum, rubber, plastic, or powder to make a cast. Once a suspect is apprehended, the forensic dentist makes one or more impressions of the suspect’s teeth, comparing them to the recorded bite marks, and if called to testify, renders an opinion of the probability of a match. Courts have upheld the constitutionality of involuntarily taking a dental impression from a suspect, as they have for most biological specimens from suspects. Bitemarks also change or become distorted when the posture of the victim changes, so the forensic dentist might be able to assist with determination of how the perpetrator moved the body.

Identification by teeth

Teeth are highly resistant to destruction and decomposition, so dental identification can be made under extreme circumstances. All dental records are based on a universal numbering system, and contain an



amazing amount of information. For example, they note: fillings, extractions, surface structure/root configuration, adjacent teeth, twisted/tilted teeth. Antemortem / Postmortem match determines identity.

Bite mark analysis

Forensic odontologists may also work backwards matching the bite marks on objects found at a scene to a suspect. They develop the skill of comparing dental impressions taken from a person's mouth to bite-mark impressions on the skin (or possibly the bones) of a victim. Police investigators have always noticed that at some crime scenes, criminals seem to leave their bite impressions on food products, chewing gum, or more commonly on the skin of their victims, especially in cases of battery, rape, child abuse, and homicide.

The physical characteristics of both the bite mark wound and the suspect's teeth include: the distance from cuspid to cuspid, the shape of the mouth arch, the evidence of a tooth out of alignment, teeth width and thickness, spacing between teeth, missing teeth, the curves of biting edges, unique dentistry, wear patterns such as chips or grinding.

There are seven (7) types of bite marks which can be classified by four (4) degrees of impression:

1. Hemorrhage - small bleeding spot
 2. Abrasion - undamaging mark on skin
 3. Contusion - ruptured blood vessel, bruise
 4. Laceration - punctured or torn skin
 5. Incision - neat puncture of skin
 6. Avulsion - removal of skin
 7. Artifact - bitten-off piece of body
1. Clearly defined - significant pressure
 2. Obviously defined - first-degree pressure
 3. Quite noticeable - violent pressure
 4. Lacerated - skin violently torn from body

Time elapsed since death

Dentistry, distinct from forensic pathology, has little to offer, but if death has occurred, the teeth of a corpse may take on a distinctive purplish pink colour that is due to accumulation of blood breakdown products in the dentinal tubules. It appears to take from 7 to 14 days before discoloration becomes apparent so this may give some gross indication of time of death.

Comparison with previous records

Final identification will have to rely on previously produced ante mortem dental records. It then becomes a relatively simple procedure to compare the

information derived in the post-mortem situation with that present in the ante mortem records. The identification techniques are applicable to death of a single individual but also are extremely important after a mass disaster, in which there may be severe mutilation or burning of bodies, particularly in a high speed air disaster, when severe disintegration of bodies may occur. In most air disasters, 60% to 70% of all individuals are identified solely or partly through dental evidence. Forensic dentistry is the single most important technique of identification in these circumstances, and accurate dental records made and retained by the dental practitioner may be crucial in these procedures.

Bites in other materials

Criminals may, from time to time, leave their dental signature in bitten apples, chocolate, cheese, or other foods left at the scene of a crime. There are cases in which assailants have bound victims with adhesive tape and torn off section of the tape with their teeth, leaving identifiable bite marks on the tape. The same principles of analysis apply as in the case of tissue bites, but bites in artificial substances of foods can often yield more information because of the lack of distortion of the material and its ability to make a good impression of the biting edges of the teeth. In all types of bites, it is important that, before the materials are handled, swabs are taken to test for possible salivary contamination because this step may reveal the blood group of the biter. If the saliva contains intraoral cellular material DNA analysis may be possible.

Lip prints

The use of lip prints for human identification was first suggested in 1950 and research was carried out on lip prints in the 1960s and early 1970s, resuming in the last few years. Although lip print identification has been utilized in court in isolated cases more research needs to be conducted in this field with regard to confirmation of uniqueness, and the collection and interpretation of evidence.


Forensic Dentist may play a major role in identification of those individuals who cannot be identified. Recent tragedies and past and present situations have increased awareness concerning the importance of forensic dentistry in identification of victims. Forensic dentistry is not yet fully introduced into the dental curriculum as a subject. Hundreds of cases are seen every year relating to identification problems and bite mark analysis. Dentistry has an important role in the recognition of abuse among persons of all ages. Dentists have a major role to play in keeping accurate dental records and providing all necessary information so that legal authorities may recognize malpractice, negligence, fraud or abuse, and identify unknown humans. Last but not the least forensic dentistry is an important science and must be treated as such.

**Assistant Professor, Department of Periodontics,
 Navodaya Dental College & Hospital,
 Navodaya Nagar, Raichur -584103**

Research Findings

* Bindu R. Nayar

Wiping out tooth infections: cool plasma packs heat against biofilms



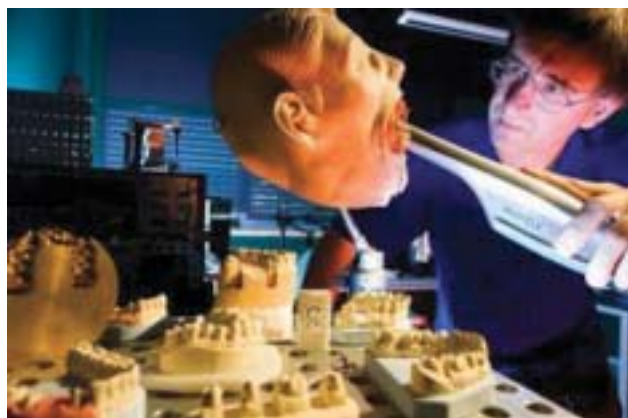Science Daily June 15 2009

Though it looks like a tiny purple blow torch, a pencil sized plume of plasma on the tip of a small probe remains at room temperature as it swiftly dismantles tough bacterial colonies deep inside a human tooth. Researchers looking for new ways to safely fight tenacious biofilm infections in patients and it could revolutionize many facets of medicine.

Jiang et al . Nanosecond Pulsed Plasma Dental Probe. Plasma Processes and polymers June 2009

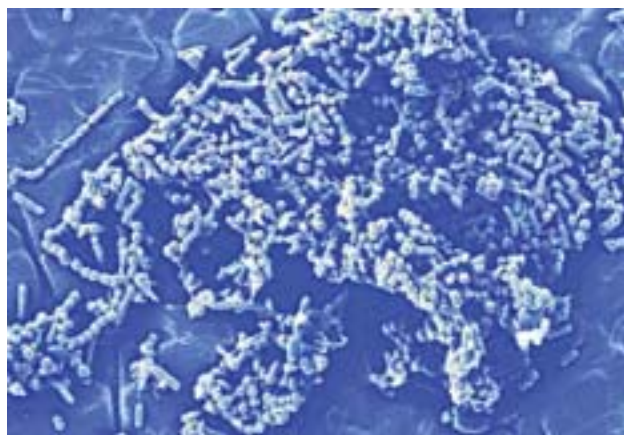
Dentures: 3D digital images of tooth contours may replace plaster models

Science Daily (June 15 2009):



Using current technology, dental technicians can only make dentures using a bite impression. The silicone template for this plaster model is made by the dentist, in a procedure which is unpleasant for the patient. In the future a 3D digitizer will provide the teeth contours without a plaster model.

Toward a rosetta stone for microbes' secret language



Science Daily (Dec 2007)

Scientists are on the verge of decoding the special chemical language that bacteria use to “talk” to each other. The achievement could lead to new treatments for antibiotic resistant bacteria. Disease causing bacteria use this language to decide when to infect a person or their host. Decoding the structure and function of compounds involved in this elaborate signaling process known as “quorum sensing” could lead to new medicines to block the signals and prevent infections. N Acylated Homoserine lactone (AHL) analogues that are effective against a broad range of bacteria types, including those that cause disease in humans. These compounds are the most potent synthetic modulators of quorum sensing.

Nanotechnology may increase longevity of dental fillings

Tooth coloured fillings may be attractive than silver ones but the bonds between the white filling and the tooth quickly age and degrade. New nanotechnology technique will extend the fillings longevity. The imperfect adhesive leaves spaces inside the collagen that are not properly infiltrated with resin leading to the bond's failure. The crystals called hydroxyl apatite bond when proteins and mineral interact. Calcium phosphate a mineral that is the primary component of dentin, enamel and bone. The crystals should lock the minerals into the hybrid layer and prevent it from degrading. Guided tissue remineralization will create a delivery system to apply the crystals to the hybrid layer after the acid etching process. So these crystals will provide the strength to save the bonds. So goal is to repair the cavity on its own.

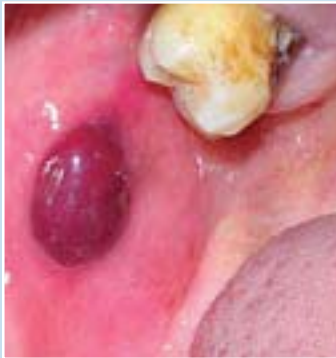*** Professor, Dept of Periodontics,
Government Dental College, Thiruvananthapuram

Diagnose

Diagnose the following cases

* Rani Mol P, ** Girija .K.L., *** Tinky Bose, **** Anita Balan

Case 1



Intra oral photograph of a 54 year old patient following an impression procedure.

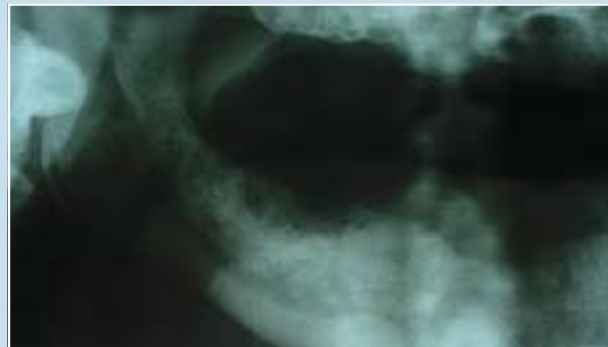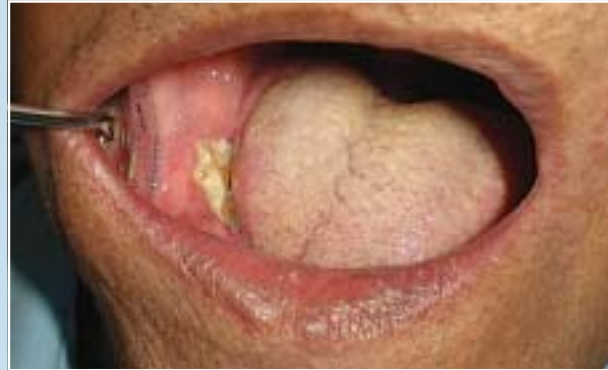A 54 year old male patient reported to the OPD of Dental College, Thiruvananthapuram, with a red colored swelling on right buccal mucosa of one day duration. An impression was taken the previous day for replacement of missing teeth, following which he noticed it. The size of the swelling was about 2x3 cm in size. There is no pain associated with the swelling. However he did experience a mild discomfort.

- 1 Identify this lesion.
- 2 What are the probable differential diagnoses?

Answers - 1

1. Angina Bullosa Hemorrhagica (Traumatic Oral Hemorrhagic Tenositis, Recurrent Oral Hemorrhagic Tenositis, Stomatopompholyx Hemorrhagica)
It is a benign sub epithelial blister filled with blood. It may occur idiosyncratically or due to some local causes like trauma or consumption of hot food or systemic causes like steroid inhalation and diabetes. Some hereditary factors like fragility of mucosa or capillary vessel abnormality can contribute to this lesion. No definite treatment is needed. Reassurance should be given to the patient and symptomatic treatment like chlorhexidine mouth rinse (12-20%) or ascorbic acid (200 mg BD) should be given.
2. Differential diagnosis
Mucous membrane pemphigoid
Linear Ig A disease
Dermatitis herpetiformis
Bullous lichen planus
Thrombocytopenia

Case 2



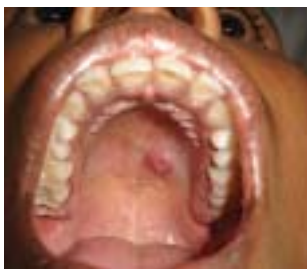67 year old male patient reported to the Oral Medicine Department with pain and swelling of lower jaw on right side of 2 weeks duration. He had undergone radiotherapy for carcinoma of his right buccal mucosa two years duration. On intraoral examination a white discoloration was noted on the edentulous ridge on the molar region. It gave a gritty feeling on probing. Panoramic radiograph shows irregular bone loss in the molar region. What is the most probable diagnosis?

Answer - 2
Osteoradionecrosis

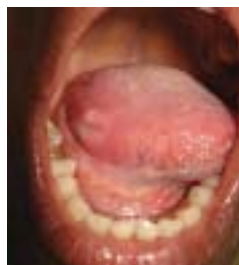* PG student, ** Lecturer Trainee, *** Assistant Professor, **** Prof and HOD, Dept of Oral Medicine and Radiology, Government Dental College, Thiruvananthapuram

* Rani Mol P, ** Anita Balan

1. 21 yr old female presented with a painless swelling of size 1.5 X 2 cm on the palate of 7 months duration. It was firm in consistency. There were no significant radiographic findings. All the teeth in the upper left quadrant were vital. The most probable diagnosis is:



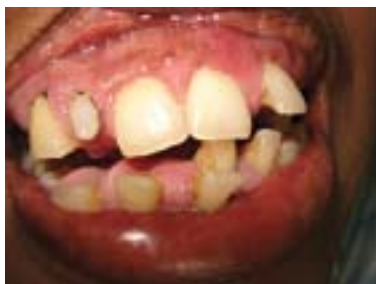- a) Periapical abscess b) Haemangioma
c) Osteoma d) Minor salivary gland neoplasm



2. A middle aged male patient reported with an ulcer of 1 month's duration on the right lateral border of the tongue. The base of the ulcer was not indurated. The provisional diagnosis is:

- a) Traumatic ulcer
b) Aphthous ulcer
c) Carcinomatous ulcer d) Ruptured mucocoele

3. The photograph shows the anterior gingiva of a 54 year old female. There was no bleeding on probing and the consistency was firm. She is under treatment for hypertension. She was not diabetic and had no other ailments. There was no related family history. The condition is most likely to be:



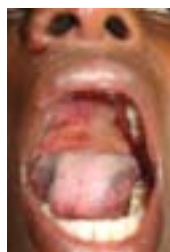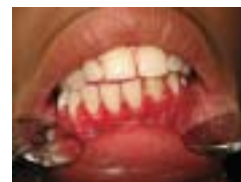- a) Inflammatory gingivitis
b) Drug induced gingival enlargement
c) Familial fibromatosis gingivae
d) Granuloma Gravidarum

4. Aphthous ulcers are commonly seen in the following syndromes except:

- a) FAPA syndrome b) Sweet syndrome
c) Behcets syndrome d) Clouston's syndrome

5. Desquamative gingivitis is associated with the following conditions except:

- a) Linear IgA disease
b) Bullous Pemphigoid
c) Psoriasis
d) Cicatricial Pemphigoid

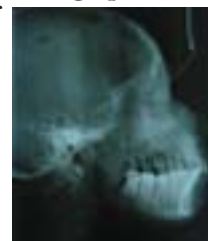

6. This patient presented with diffuse ulcers only on the right side of the palate and face. She had history of fever 4 days prior to noticing the lesions. The probable diagnosis is:

- a) Erythema Multiforme
b) Lupus Erythematosus
c) Herpes Zoster
d) Pemphigus erythematosus

7. Multiple osteolytic lesions seen on radiographs of the skull is a characteristic feature of the following conditions except:

- a) Metastatic Carcinoma
b) Multiple Myeloma
c) Fibrous dysplasia
d) Langerhans cell histiocytosis

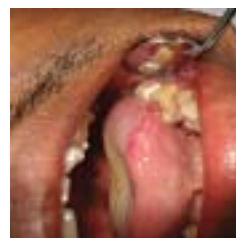
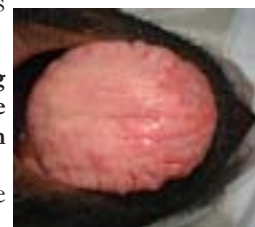
8. Aphthous fever is:

- a) A viral infection which only very rarely affects man
b) A form of major Aphthae
c) Is characterized by Herpetiform Aphthae
d) Is characterized by Aphthous of Oropharynx

9. Which of the following syndromes presents with the characteristic feature seen in this picture:

- a) Van der Woude 's Syndrome
b) Melkersen Rosenthal Syndrome
c) Bloom's Syndrome d) Pierre Robin Syndrome



10. This patient presented with an ulceration of multiple areas of the oral mucosa especially on the left lateral aspect of the tongue and palate, 2 days following root canal treatment. He had experienced severe discomfort during the procedure following spillage of an irrigant. The condition could be:

- a) Traumatic ulcer b) Herpetic stomatitis
c) Chemical burn d) Bednar's Aphthae

1. d; 2. a; 3. b; 4. d; 5. c; 6. c; 7. c; 8. a; 9. b; 10. c

ANSWERS

*Postgraduate Student, **Professor & Head,
Dept. Oral Medicine & Radiology,
Govt. Dental College, Trivandrum.

PADMA BHUSHAN BRIGADIER Dr. ANIL KOHLI RE-ELECTED AS PRESIDENT, DENTAL COUNCIL OF INDIA

Padma Bhushan Brigadier Dr. Anil Kohli who has been elected as President, Dental Council of India for the 2nd term in the General Body Meeting held on 18th & 19th July, 2009 at New Delhi.
Dr. Anil Kohli, Mob: 09873177700, anilkohli2003@hotmail.com

Other Office bearers of DCI :

Dr. C. Bhasker Rao,
 Vice President,
 Mob: 09845254308, bhaskerrao@hotmail.com

Executive Members

Dr. R.K. Srivastava
 Tel: 022 23061438 022 2361924
 rakeshsrivastava789@hotmail.com

Dr. Dibyendu Majumdar
 Mob: 09331035537
 tom_mie001@yahoo.co.in

Dr. S.M. Balaji
 Mob: 09841033359, smbalaji@eth.net

Dr. Pradeep Chandra Shetty
 Mob: 09844034763
 drpradeepshetty9@yahoo.co.in

Dr. Mahesh Verma
 Mob: 09443348530
 doptima@vsnl.com

Dr. Rahul Hegde
 Mob: 09820007575
 raihegde123@indiatimes.com

Secretary
Maj. Gen. (Retd.) Dr. P. N. Awasthi



*Padma Bhushan Brigadier
 Dr. Anil Kohli*



Renewal Regulations of Kerala Dental Council

It was our long cherished need to have a change to the yearly renewal of Dental Council Registration. As per the regulation issued by DCI with the approval of Govt. of India, the KDC resolved to implement the regulation regarding the renewal of registration for five years with an option to renew yearly also with effect from April 2009. It was also resolved to implement the following fee structure with effect from 01-04-2009

Accreditation of CDE Programs

Considering the regulations framed by DCI the State Dental Council is in the move to frame separate guidelines for accreditation and conduct of CDE Programs and will come out with the same in the coming months. In order to promote the CDE Programs the KDC in its Budget proposal has allocated Rs. One Lakh fifty thousand which will be distributed as financial aid for the conducting of CDE Programs in Govt. Dental Colleges and IDA State Branch and for the programs conducted directly by Kerala Dental Council.

Dr. Mathew Joseph
 President, Kerala Dental Council

S/No	Type of Registration	Revised Fee
1.	Permanent Registration	Rs. 2000/-
2.	Duplicate of Registration Certificate PermanentRenewal/ Additional Qualification	Rs. 3000/- Same as the fee for original renewal/additional certificate
3.	Good Standing for sending Certificate/Attestation/Verification	Rs. 2000/- (Rs. 5000/- by fax directly to foreign countries)
4.	Renewal Fee (for 5years) (for 1year)	Rs.500/- Rs.100/-
5.	Fine for late renewal	Rs.100/- per year
6.	Re-registration fee after 5 years	Rs. 2000/-
7.	Attestation/Verification for sending by fax	Rs. 2000/- (Rs. 5000/- directly to foreign countries)
8.	For additional Qualification	Rs. 500/-
9.	No Objection Certificate	Rs. 1000/-
10.	Change of Name	Rs. 1000/-
11.	Searching Fee	Rs. 200/-
12.	Fee for Revised Certificate	Same as the fee for Original Certificate
13.	Recognition Certificate	Rs. 500/-

BEST DOCTOR AWARD



Dr. N.O. Varghese, Principal, Govt. Dental College, Trivandrum has been adjudged as the 'Best Doctor-2009'. He is a member of the Dental council of India.



Dr. M.K. Mangalam, Joint Director (General) of Medical Education winner of special award under Health Administration and Management Category. Award was given by Smt. P.K. Sreemathi Teacher, Hon'ble Health Minister, Govt. of Kerala.

Secretary's Report and Association News



Secretary's Message

My dear fellow Members,

Greetings from IDA Secretariat. We held a handful of programmes for the last three Months. We were able to conduct the Students Conference "Occlusion 09" and the "No Tobacco Day" observation in the right vision and attitude. On behalf of IDA Kerala State I congratulate the student committee chairman Dr. C K Ranjith, organizing chairman Dr. Abdul Razak, organizing secretary Dr Mohammed Sameer, Dr. Rajesh Ravi, Dr. Lalappan K Joseph and the members of IDA Malappuram Branch for making the Students Conference a memorable one. I must place on record to all the Dental Colleges who had participated in this mega event. The world No tobacco Day was observed by IDA Kerala State on 31st May at Thunchen Paramba Tirur with Occlusion 09. IDA CDH wing is also in the full swing of activities. A great news to hear from the office is that we were able to achieve a slot in the school health card issued by Govt of Kerala. Congratulations to our State President and the CDH wing Dr. Anil G for this achievement.

At present we are facing certain burning issues which are not directly under the control of state office. Regarding DRS registration we are committed to sort out the issue with the Govt of Kerala and DRS. The proceedings are underway hoping for a positive outcome. Please take note that the concession for affiliation fee for joining IMAGE will be over by 31st Sept. It is very sad to note that members are not utilizing these opportunities "It has been the habit of humankind to wait until the eleventh hour to spiritually commit ourselves to those problems we know all along to be of the greatest urgency". The attitude of last minute implementation has to be changed. It is very painful to hear from the Directorate of Radiation Safety that less than 10 members only has applied for DRS registration. So our chance of getting a relief in the registration fee is getting narrowed. I appeal all the members to consider these matters with due importance so that we can expect a positive outcome. Only four months are left for our State Conference. Set aside all your other engagements and be ready to march towards Calicut.

REPORT OF ACTIVITIES

Third State Executive Committee Meeting:-

The meeting was held on 11-05-08 at IMA Hall Tellicherry hosted by IDA Tellicherry Branch.

Dr. Antony Thomas Secretary, IDA Kerala State collared the president Dr. KN Pratap Kumar and the president called the meeting to order. A one minute silence was observed by the house to condole the sad demise of late Dr Radha C.P of IDA Pathanamthitta Branch and Dr. Balachandran's mother.

IDA Tellicherry Branch President Dr. Aneesh Sebastian welcomed the gathering. Dr. KN Pratap Kumar in his opening remarks expressed his heart felt appreciation to all the Presidents and Secretaries of local branches for carrying out various activities of branches. He opined that value based evaluation is an ability. Ability without right attitude is a waste. He congratulated IDA Trivandrum Branch and Kerala Dental Council for conducting the state level CDE in a befitting manner. He specially praised the efforts of CDH wing and IDA Mavelikara Branch for organizing the Dentist's Day in a memorable way and congratulated CDH convener Dr. Anil.G. He outlined the progress of Sradha, the hepatitis immunization programme, Prabudtha Keralam, the free Oral Cancer Detection campaign and the meeting of IDA with

IMAGE officials. He congratulated Dr. Sreekumar Nambiar for releasing the news letter of HOPE the voice of HOPE and mentioned the systematic monthly reporting of IDA Kochi, Central Kerala Kottayam, Malabar, North Malabar and Pathanamthitta. He specially mentioned the reporting format and the activities of IDA Kochi. He also congratulated Dr. K. Nandakumar for the timely release of the KDJ. He expressed satisfaction in the proceedings of DD Sports, Occlusion-09, Flash-09 and thanked Dr. Vinod, Dr. Ranjith, Dr. Sameer & Dr. KN Thomas.

The special feature of the meeting was the lighting of the traditional lamp by the President, and State officials. There was a cake cutting to celebrate the silver wedding of State President and birthday of Dr. Santhosh Sreedhar and other birth day boys in the executive committee

Reports by Secretary

Hon. Secretary Dr. Antony Thomas presented the report for the months of February, March & April 09. He expressed satisfaction in the all round activities of many local branches and congratulated IDA Malabar and Kochi for their achievement in the



Executive Committee Meeting at Tellicherry



Executive Members at the Meeting

membership drive. He congratulated IDA Mavelikkara branch and the state CDH convener Dr. Anil G and the Co-ordinator Dr. Dileep Varghese Jacob for conducting the Dentist's day in befitting manner. He also mentioned the efforts put in by IDA Trivandrum branch for organizing the state level CDE in an exemplary manner .He also recognized Dr. Raveendranath, Dr. Oommen George, Dr Samuel.K. Ninan, Dr. Sony Thomas, Dr. Shibu Rajagopal, Dr. Jaibin George and Dr. Benny Augustin for helping the state office for booking stalls for the 42nd KSDC during the National Conference at Nagpur. The efforts of CDH wing in implementing Prabudha Keralam and Sradha the hepatitis immunization programe had a special mention by the Secretary. He mentioned the systematic reporting of IDA Kochi, Pathanamthitta, North Malabar, Malabar, Central Kerala Kottayam, Attingal, Nedumbaserry, Kottarakara, Mavelikkara, Malappuram &Malanadu branches.

KDJ

The 2nd issue of the KDJ for the year 2008-09 was released by president Dr. KN Pratap Kumar by handing over a copy to past National President Dr. MC Mohan. Hon. Editor Dr. K Nandakumar appealed all local branches to distribute the journals in time to the members.

CDE

The CDE convenor Dr. O.V Sanal presented the report of the CDE. He congratulated IDA Trivandrum branch for hosting the 1st state level CDE. He informed that the 2nd, 3rd and 4th CDE programs will be conducted at Pariyaram Dental college, Karunagapally and Alleppy respectively. He handed over a cheque of Rs. 10000/- to the State Secretary as the local branch share from CDE programmes.

2nd state Level CDE

The second state level CDE Programme was organized jointly by IDA Kerala State and SPIK on 14th June 09at Medical Education Hall Academy of Medical Sciences Pariyaram ,Kannur.

Dentist's Day & CDH Report

CDH convener Dr. Anil G presented the report of the Dentist'sDay. He requested all branches to participate in the hepatitis immunization programme "Sradha". The vaccines are available for low cost and reminded to use this occasion for a comprehensive immunization to the doctors as well as the dental auxiliaries. It was also decided to host a meeting of CDH

representatives of local branches at Kochi along with the sports meet to make aware of the activities done for the public to the Chief Minister, Health Minister, Chief Secretary and the Health secretary. Dr. Shibu Rajagopal suggested to include the CDE representatives from local branches to the said programme. The house accepted this proposal. The house appreciated the team of doctors who conducted orthognathic surgery at Govt. Medical College Alleppy.

Prabudtha Keralam

Prabudtha Keralam" the Free Oral Cancer Detection Programme was conducted as a week long programme prior to the No Tobacco day. The publicity of the programme has done through the electronic and print media. A sticker was sent to all members to be pasted at the clinic for the public information.

IDA- School TC &Health Record

IDA Kerala State is very proud to report that we were able to achieve a slot in the school health card issued by Govt of Kerala. Congratulations to our State President and the CDH wing- Dr Anil G for this achievement

Oral Hygiene Day

The Co-ordinator of the programme Dr. Santhosh Sreedhar informed that the day will be celebrated on 1st August at Payyannur.

IDA IMAGE

Hon secretary Dr. Antony Thomas detailed about the meeting with IMAGE officials and IDA at Trivandrum. He urged the members to join the scheme before 30th Sept or else the affiliation fee will be Rs 5000/ instead of Rs 3000/- .

Awards Committee

In absentia of the award committee chairman Dr. Alias Thomas, secretary informed that the award committee guidelines were sent to all local branch secretaries. He mentioned the contributions of Dr. Mathew Joseph, Dr. Baby K Antony and Dr. Eapen Thomas for framing the guidelines and added that certain additions regarding the student's awards were included in the revised guidelines.

Cultural Committee

The committee chairman Dr. KN Thomas was invited to spoke



'No-Tobacco Observation Day' at Tirur hosted by Malappuram Branch



Kerala Dental Student's Programme "Occlusion 09"

about the plans. He informed that an award for the local branches for the best cultural activities is under consideration . The criteria for the selection will be based on the number of cultural activities, Onam celebrations & New Year celebrations.

Sports Committee

The committee chairman Dr. Vinod Mathew spoke about the state level sports day decided to hold on 9th August 09. The venue will be DD Retreat Kochi. The games included are shuttle badminton and Table Tennis.

41st KSDC

The audited accounts of the 41st KSDC were presented by the organizing chairman Dr. Jaibin George. The accounts were passed. A cheque for Rs. 60000/- was handed over to the Hon. State secretary. The accounts were passed, proposed by Dr. Vijayasankaren and seconded by Dr. MC Mohan. It was decided to speed up the delivery of the lucky dip prize of the conference to the winner.

42nd KSDC

Conference secretary Dr. Oommen George and the organizing chairman Dr. Viswanath was invited to brief about the proceedings. Dr. Viswanath detailed with a power point presentation about the conference. 34 RC registrations from IDA Nedumbaserry was handed over to Dr. Oommen George by 1st VP Dr. Jaibin George.

43rd KSDC

Dr. CK Ashokan was invited to present the report. He said that the COC was formed and moving at a good pace. IDA Malappuram the host branch then distributed mango fruits to the house as a token of love. The tentative dates are 26th, 27th & 28th Nov 2010.

No Tobacco Day & Student Conference

IDA Kerala State observed No Tobacco Day and conducted Students Conference "Occlusion -09" at Thunjan Paramba , Tirur on 31st May -09

IDA HOPE

The secretary Dr. Nizaro Siyo presented the report of the scheme. He said that 4 branches are yet to forward the renewal. Two cases were recently received. He invited for suggestions for any change in the case sheet format.

News from Kerala Dental Council

KDC President Dr. Mathew Joseph announced that from next year onwards KDC registrations can be done in once in 5 years and the details will be notified. He stressed the need of 20 points/year for CDE accreditation.

Dr. Antony Thomas

Hon: Secretary IDA Kerala State.

Report of "Occlusion '09 - Keral Dental Student's Conference 2009" and "No-Tobacco Observation Day" held in conjunction on 31st of May, 2009 at Tunjanparamba, Tirur hosted by IDA, Malappuram Branch.

IDA, Malappuram Branch very successfully hosted two IDA, Kerala State programmes jointly, which were held on the 31st of May, 2009 at the scenic and culturally charismatic Tunjanparamba, the birth place of the Father of the Malayalam Alphabet, Tunchathezhuthachan. The Kerala Dental Student's Conference and "No-Tobacco Observation Day" were organized with equal fervour and pomp. Both the programmes were well attended with over 400 registered delegates.

The official programmes began at 10.30 am with the arrival of the guests. Dr. Pratapkumar.K.N, IDA, Kerala State, presided over the meeting. The gathering was then welcomed by IDA, Malappuram Branch President, Dr. Mohammed Sameer.P.T. Dr. Pratapkumar then delivered the presidential address. Mr. Abdul Samad Samadani.M.P, inaugurated the "No-Tobacco Observation Day" and delighted the crowd with his oratorical prowess. Dr. Anil.G, IDA, Kerala State CDH Convenor, then explained the programmes that IDA, Kerala State has undertaken with relevance to anti-tobacco activities. Dr. Ashokan.C.K, IDA, Kerala State IPP, was then called upon to take the No-Tobacco Oath, which was followed by all in the crowd. Dr. Simy Mathew was awarded by Dr. Pratapkumar, the Dr. Shiny Francis Memorial Trophy, instituted by IDA, Malappuram Branch in memory of Late Dr. Shiny Francis, who was an active member, for the best essay by a lady dentist/student on the topic "Tobacco Related Oral Lesions".

Dr. Anthony Thomas, IDA, Kerala State Hon. Secretary, addressed the gathering after which he inaugurated the "IDA Approved Tobacco Cessation Clinic". Dr. Abdul Razak, Chairman, Organising Committee of Occlusion '09, talked about the Student's

Conference programmes. Occlusion '09 was formally inaugurated by Mr. C. Radhakrishnan, eminent litterateur. The official meeting concluded with the delivery of the Vote of Thanks by Dr. Rajesh Raveendranathan, IDA, Malappuram Branch, Hon. Secretary. This was followed by a sumptuous lunch.

The cultural competitions then began with a bang, a 12 piece Chendamelam. The students very actively participated in the literary, arts, scientific sessions and cultural competitions. The events were essay writing (English and Malayalam), debate, water colour painting, pencil sketch, clay modeling, scientific paper presentations, poster presentations, table clinics, solo song, group song (eastern and western), group dance, mime and fashion show. All were keenly contested.

Royal Dental College, Chalissery ran away with the Overall Championship followed closely by Amrita School of Dentistry, Kochi, Azzezia College of Dental Sciences, Kollam and MES Dental College, Perintalmanna. The prizes were given away at a valedictory function led by the effervescent Dr. Ranjith.C.K, Student's Committee Chairman, IDA, Kerala State. He invited various dignitaries onto the stage. He then asked Dr. Praveen (Vachakaraja) to deliver a magnificent extempore speech. He called upon the awardees who were given certificates and trophies by various members of the Indian Dental Association. Finally, Dr. Pratapkumar, thanked one and all for making the day a huge success. The day was over with a delicious dinner.

Dr. Abdul Razak **Dr Mohammad Sameer PT** **Dr Anil G**
Org:Chairman Org: Secretary CDH Convenor

CDH NEWS



Greetings to all my beloved IDA members in this monsoon season.

Its my pleasure to convey that the cdh programmes are progressing very swiftly under the guidance of our state president Dr.K.N. Pratapkumar. I thank all branch office bearers for the smooth conduction of the cdh activities in their branches.

There is a grand achievement in the history of IDA where in we (Kerala Branch) have been included as a part of the health card given by National Rural Health Mission 2009 under the Central Govt. This is a proud achievement of all the ida members of Kerala State.

CDH programs conducted to date

1. Prebudha Keralam – CDH project for early Cancer detection and awareness of oral cancer to the Electronic and Print Media. Through this we could serve the poor and needy
2. No Tobacco Day was held at Thunjan Parampu hosted by IDA Malappuram Branch on 31st May 2009 which was inaugurate by Mr.Abdul Samad Samaddani who was the chief guest. Mr. C Radha Krishnan was the guest of honour.
3. An elocution competition for high school students was conducted by Ida Pathanamthitta Branch on 21st June 2009. Around 100 students from 25 schools in and around pathanamthitta participated in this programme. We will try to get this competition for students as a state level programme in this term.
4. Hepatitis Vaccination – 3 doses of this vaccination is available for only Rs. 100. 5 branches have already availed this



facility which are Mavelikara, Malappuram, Wayanad, Pathanamthitta and Kochi.

2 Dental colleges have also availed this facility.

Dr. Anil G, CDH Convener inaugurated this programme in Kochi

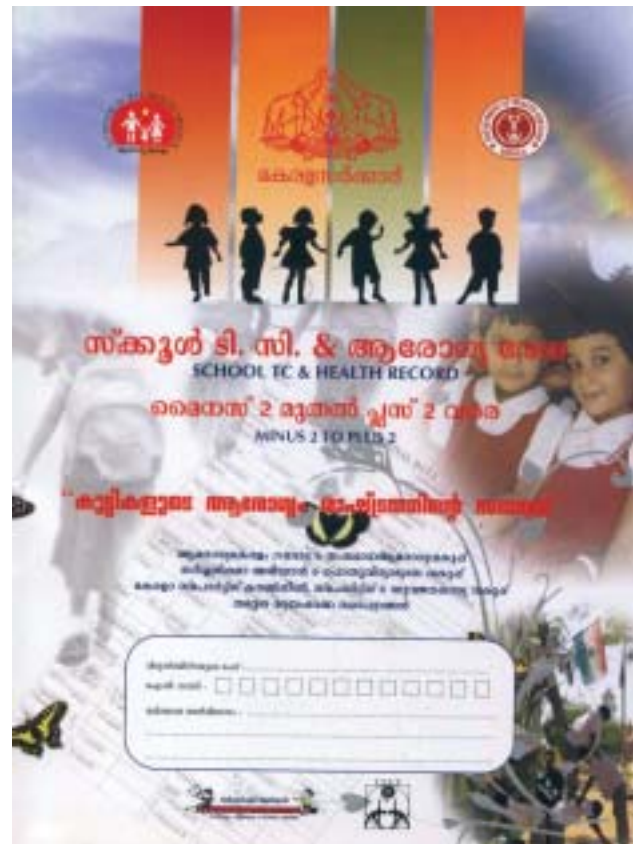
All members and their staff can use this facility before this term ends.

Branch CDH and CDE convenors training programme will be held at Kochi on 9th August 2009.

My sincere thanks to the state president Dr. K N Pratap Kumar, Hon. Secretary Dr. Antony Thomas and State Editor Dr. K. Nanda Kumar and all the office bearers of the state and the branch and all the members of Ida Kerala for their whole hearted support and guidance in the CDH activities.

JAI IDA,

Dr. Anil G
CDH Convener
Kerala State



Health card issued to students of classes under National Rural Health Mission (NRHM)

“IDA – HOPE” – A Report

(Indian Dental Association Kerala state - Help Offered to Professionals in Emergencies.)
Present Position of the Scheme

IDA HOPE is a sub committee of IDA Kerala state. It was formed by combining the SSS & PPS of IDA Kerala state on 2/9/07. Founder Membership was open till 31/1/08 so that any member who was not the member of either PPS/ SSS could join with the same benefits. It has 1429 Active members as on date. Out of which 102 joined this year. This is approximately about 65 % of our IDA State membership, which show the acceptance of the present scheme. IDA Hope has made its presence in all the 27 local branches of IDA Kerala State.



Presently 9 cases pending in the court of law. 2 cases were settled in court in our favor. The incidents which has gone to the above legal proceedings occurred as

- Post Extraction Pain / Dry Socket.
- Post Extraction Bleeding
- Post Extraction Infection / Trismus
- Removal of Lower third Molar Causing Fracture of Mandible (2 Cases)
- Wrong Tooth Extraction
- Post Filling Pain
- Full Denture Not Satisfactory
- Orthodontic result Not Satisfactory
- Orthodontic Brackets Breakage / Multiple Non Attending Appointments.
- Anesthetic complication in Orthognathic surgery / Death of the Patient.

Also provided legal advice in few cases in the initial stage of the dispute, there by avoided court cases. Do write the Detail of Clinical Findings, Diagnosis, the treatment options advised, treatment given etc and Medical / Dental / Allergy History (even if no history – note that) in the case paper, even if not relevant to the present procedure. This will help us to defend in majority of the cases.

In an event of medico legal case

- **Never panic**
 - **Explain to the patient/relatives in polite manner that we have done the procedure for the best interest of them. Complications very rarely occur and are part of the life, which we never wish to happen.**
 - **Be firm, but don't agitate them.**
 - **False justification will lead to trouble. Now day's patients are well aware of the treatment procedures.**
 - **Inform the IDA HOPE representative of your branch & IDA HOPE secretary.**
 - **Sent the following to the secretary within a week on receipt of the notice.**
 - Your Name, IDA Hope No:
 - Copy of the notice received
 - Copy of the case sheet
 - Detailed version of the case with your explanation
- Do not sent any reply of your own or through any advocate with out the permission of the scheme office.**

All cases were well managed by our team with the help of our advocates especially Adv. Shyam Padman. My sincere thanks to Dr. Viswanath & Adv. Shyam Padman in providing the legal helps to the necessary members in time.

Dr. Raju Kurien of IDA Kodungalloor Branch who was the

founder member in both the schemes expired in a car accident was the 1st beneficiary of the scheme.

His family was given a sum of Rs. 126000/- (one lakh twenty six thousand) in addition to 74000/- given from SSS fund.

Dr. Raju K S of Attingal Branch was the next beneficiary His family was given a sum of Rs.265000/- (Two lakh sixty five thousand)

Present Office Bearers.

Dr. Viswanath - Cemmad (Chairman)
Dr. Nandakumar - Mallappally (Vice Chairman 1. Legal Cell)
Dr. SreeKumar Nambiar - Payyannur (Vice Chairman 2. Social Security Cell)

Dr. Nizaro Siyo - Thamarassery (Secretary)
Dr. Madavankutty - Thamarassery (Jt Secretary)
Dr. Alexander Korah - Thamarassery (Treasurer)
Dr. Mathew Joseph - Mundakayam (Internal Auditor)

The Office and Address of the Scheme shall be that of the Secretary of the scheme.

You are always welcome to contact me at the address below for any query / details etc.

Dr. Nizaro Siyo,
Secretary – IDA HOPE,
Siyos Dental Clinic,
Thamarassery, Calicut (Dt) 673573.
Phone: Mobile 9447122972 During Day time,
Residence 0495.2222972

Objectives of the Scheme

- Indemnity insurance and legal aid to the members.
- Financial compensation to the families of the unfortunate member in the case of Death/Permanent Physical disability.



- Medico-legal awareness/education.
- Encourage Promote and Popularize ethical treatment amongst Dentists.

Membership

- Member from any local branch of IDA Kerala State with a valid DCI registration
- Membership is co terminus with the membership of IDA Kerala State.
- Founder Members
- **Members of the old SSS & PPS schemes. (Members joined till 31st January 2008).**
- Ordinary Members
- **New members joined the scheme following the merger of the schemes. After 31st January 2008.**

Admission Formalities- New members

- Copy of Certificate/Passport for proof of age.
- Degree certificate.
- Copy of DCI registration certificate
- Two passport size photographs (1.In Application form, 2 For the Certificate)
- Application Form (To be endorsed by the branch representative or the secretary for proof of branch membership)
- DD for admission fees drawn in favor of IDA Hope Payable at Thamarassery.

Admission Fees for New Members

- 35 years or lower – 1500/-
- Above 35 Up to 40 – 2500/-
- Above 40 Up to 45 – 3500/-
- Above 45 Up to 50 – 4500/-

New Membership closes at the age of 50

The management committee shall be the final authority to accept/deny all the applications.

Membership Contributions Founder members

- Initial year's subscription - Rs. 1500/-
- Five year is calculated from the year they have joined PPS.
- Yearly depreciation by Rs.100/- for the next 4 years in the absence of any claims.
- The subscription amount stabilizes at Rs. 200/- for the following years.
- Members in SSS (Life) has been waived from one years payment in 2008 renewal

Membership Contributions Ordinary Members

- Initial year's subscription - As per admission fee.
- Yearly depreciation by Rs.100/- From Rs 1500/- for the next 5 years in the absence of any claims.
- The subscription amount stabilizes at Rs. 200/- for the following years.

Membership Contributions - Fraternity contribution

Payment of fraternity contribution @ of Rs. 200/- is mandatory along with the next year's renewal in the event of death of any member.

Membership Renewal

- ✍ The membership renewal period is between 1st - 31st March every year at local branch level and it should reach state office by April 15th. Reminder Intimation (This News letter) will be sent to members in February. Non-receipt of reminders is not a reason for non-renewal and can result in termination of membership.

- ✍ Table with the list of members and their renewal amount, status etc will be sent to the representatives by the end of

February. You may contact your representative to know your amount

- ✍ Renewal after the 1st set (April 15th) will be fined Rs.100/-, and the period from 1st April to date of renewal will not be covered by the scheme.

- ✍ The membership will be terminated if not renewed before the end of the year.

- Receipts will be issued by local branch Representative. 1st page counter foil is for the member and 2nd page counter foil along with payment should reach the state office before April 15th.

- The receipt book with the 3rd counter foil to be returned before the end of the financial year for auditing

Membership Rights and Obligations

- In the event of death of a member of at least 12 months membership the nominee/legal heirs will be paid an amount = Rs. 200 X No. Of active members in the scheme.

- In case of death due to accidents a benevolent contribution is paid as soon as membership is realized from the scheme office.

- In the event of Permanent physical disability other than due to old age which has forced him stop his dental profession, a member of at least 6 months membership, he/she will be paid a benevolent contribution - Rs. 200000/-

- In the case of permanent disability due to accident a benevolent contribution is paid as soon as membership is realized from the scheme office and if death does not occur within 6 months.

- The Professional indemnity coverage of the member will commence one month after the acceptance of membership.

- The maximum liability that will be borne by the scheme shall be Rs. 200000/-

- Continuous membership is obtained on timely renewal. (Before March 31st)

- The members shall maintain proper records and adopt standard protocols and safe dental practices as recommended by the scheme from time to time.

Membership Disqualification & Termination

- The membership shall terminate upon:

1. **Death.**
2. **Resignation.**
3. **Non-renewal or Non-payment of dues.**
4. **Ceasing to be a member of IDA.**
5. **Non-renewal of council registration.**
6. **Unsound mind.**
7. **Indulging in activities detrimental to the Scheme**
8. **Found to have provided falsified information.**
9. **If convicted for Immoral conduct / activities.**
10. **Expulsion or Disciplinary action.**

Membership Revival

If a membership is terminated due to any reason

- The member shall be considered for a re-admission to the scheme with the same fee structure as that of a new member.

- Readmission, any exemptions /concessions on re-admission shall be at sole discretion of the management committee /General Body.

The membership shall be revived by 2/3rd majority of the Managing committee or by the concurrence of the General body upon:

- **Full settlement of arrears**
- **Payment of re-admission fees**

STATE LEVEL CDE PROGRAMME

Dear Members,

I am very much happy to inform you all that almost all the branches are doing excellent work for conducting the inter branch as well as intra branch CDE programmes. Special mention needed the branches like central Kerala North Malabar, Kochi, Alleppey & Malabar Branch. About reporting of branches to state CDE wing, only some branches are doing properly. I request all the CDE representatives and secretaries has to send the CDE report as early as possible.

For the last six month state CDE wing conducted to state CDE programmes. The first State CDE programmes of IDA Kerala State for the year 2008-09 was held at Trivandrum on 22nd February 2009. The faculty was Dr. Sharath Shetty. The programme was hosted by IDA Trivandrum branch. Total number of 204 registered participants attended the programme. It was a joint venture of ID A Kerala State & Kerala Dental Council.

The second state CDE programme was held at Pariyaram Dental College on 14th June 2009.

Thanking you,



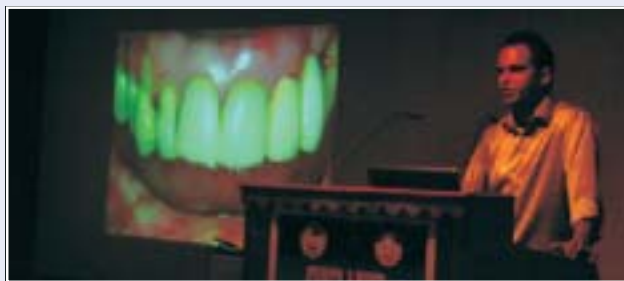Dr. O.V. Sanal
C.D.E. Convenor, IDA Kerala State

Indian Dental Association Kerala State in association with society of Periodontists and Implantologists of Kerala (SPIK) organized State Level Continuing Dental Education Programme on Interdisciplinary Periodontics on 14 th June 2009 at Medical Education Hall, Academy of Medical Sciences, Pariyaram, Kannur. The inaugural function began at 10,00am. Principal, Pariyaram Dental College, Dr.C.V. Pradeep welcomed the dignitaries and the delegates. President-IDA Kerala State Dr.Prathap Kumar.K.N. delivered the Presidential Address. Chairman, Kerala State Co-operative Hospital Complex Sri. T.K. Govindan Master inaugurated the CDE programme by lighting the lamp in a traditional manner.



President -SPIK Dr. Raju Kurian Ninan, Hon Secretary-IDA Kerala State Dr. Antony Thomas, CDE Convenor Dr. O.V. Sanal offered felicitations. Secretary-SPIK Dr. Santhosh Sreedhar proposed vote of thanks.

The Scientific Programme began at 10.30 am. There were 3 faculties and 2 moderators for this CDE Programme.



Dr. Chetan Hegde, Professor, Dept of Prosthodontics A.B. Shetty Memorial Institute of Dental Sciences, Mangalore, delivered lecture about Prosthodontic-Perio Interrelationship.



Dr. Vinod Krishnan, Associate Professor Dept of Orthodontics, Rajas Dental College and Hospital Vadakangulam spoke in detail on the topic Ortho-Perio Inter Relationship.



Dr. C.V. Pradeep, Principal, Professor and Head. Dept. of Conservative Dentistry and Endodontics a brief about Endo-Perio Interrelationship.



After the lecture there was an interactive session. The moderators of this CDE programme were Dr. K. Nanda Kumar Principal Professor and Head. Dept. of Periodontics, Azeeziya Dental College & Hospital, Kollam and Dr. C.K. Ashokan Professor and Head. Dept. of Periodontics, Pariyaram Dental College.



The entire programme was well appreciated by all the delegates which was sponsored by Colgate Palmolive India Ltd.

IDA THISSUR BRANCH

5th General Body at Hotel Thrissur Towers on 18.4.09. Discuss about the letters from the offices. CDE, CDH, HOPE and accounts presented by the respective representatives. CD presentation of soft tissue management and suturing. 32 members attended the meeting.

5th Executive meeting on 29.4.09 at Hotel Ammu Regency. Discuss about the 3rd State executive meeting at Thalassery. Discuss about the 6th General body to be conducted at Hotel Thrissur Towers on 9.5.09 with CDE by Dr. Joseph Paul on Cosmetic dentistry. Decided to give Rs. 5000/- each to pain and palliative care society Thrissur and Wadakanchery. 11 members attended the meetings.

6th General body on 9.5.09 with CDE by Dr. Dr. Joseph Paul on Cosmetic dentistry at Hotel Thrissur Towers. Decided to conduct a family meet on 23.05.09. GB decided to give Rs. 5000/- each to pain and palliative care society Thrissur and Wadakanchery. CDE, CDH, HOPE and Accounts presented by the respective representatives. 32 members attended the meeting.

7th General Body and second family meet on 23.05.09 at Hotel Dass Continental. General Body decided to conduct 8th



General Body on 6.6.09 with CDE on Million Dollor Smile by Dr. Thomas Paul. Variety entertainments by the family members and a professional orchestra. 35 members and family attended the meeting

IDA NORTH MALABAR BRANCH

Two Day CDE Programme:-

We have conducted a Two Day CDE Programme on Oral Surgery on 23rd and 28th June 2009. The first day programme was conducted at Hotel Mascot Beach Resort, Kannur. Dr. Jithesh Vasudev was the faculty and the topic was "Complications of Minor Oral Surgical Procedures". The second day programme was conducted at Hotel Sky Palace, Kannur. The faculties were Dr. Ravvendran Nair and Dr. Sony Jacob

CDH ACTIVITIES:- Free Dental Clinic:-

ADOPTION OF INSTITUTES:-

Adoption Programme at Amala Bhavan

An Adoption programme was conducted on 1-1-2009 at Amala Bhavan, Chovva, Kannur. Dr. Muhammed Shaheer, President IDA-NMB, Dr. C.K. Ashokan, IPP, Kerala State and many other members attended the function.

Adoption Programme at St Francis Bhalabhavan

An Adoption programme was conducted on 1-2-2009 at St Francis Balabhavan, Thottada, Kannur. Dr. C. Roopesh and Dr. Azeem were attended.

Cleft Lip and Cleft Palate Camp

A cleft lip and cleft palate screening camp was conducted on 29-03-2009 at Akkiparamba U.P. School, Taliparamba, Kannur. Dr. Sony Jacob, Oral Surgeon and Dr. Tradip Jaypal, Orthodontist examined the patients. President Dr. Mohd Shaheer, President, Dr. Anil Thunoli, Secretary, Dr. Roopesh CDH, Convenor, Dr. Dinesh Nambiar, Dr. O.V. Sanal, Dr. P.K. Anil Kumar, IPP, Dr. Ajay Nair were attended the camp. 15 children were selected for complete treatment with reduced treatment charges at Pariyaram Dental College.

Treatment Programme:- A treatment programme was conducted on 11-1-2009 for the selected patients of 'AMALA BHAVAN' at our free dental clinic at Amala Bhavan. Dr. P.K. Anil Kumar, Dr. Dinesh Nambiar, Dr. Sumitha Vishwanath, Dr. Shyba Vinayaraj and Dr. Ajay Nair attended.

A treatment programme was conducted on 15-2-2009 at Amala Bhavan free dental clinic for inmates of St. Francis Balabhavan. Dr. Roopesh and Dr. Ranjith attended. A treatment camp was conducted in our free dental clinic at Amala Bhavan,



Chovva. Around 20 inmates from Prathyasha Bhavan were taken the treatment. Dr. Sumitha Vihwanath, Dr. P.K. Anil Kumar, Dr. C. Roopesh and Dr. Anil Thunoli attended the camp.

Dentists' Day 2009

On 6-3-2009

As a part of Dentists' Day celebration President and many members donated our blood to blood bank of Kannur H.Q. Hospital. We have also donated free food for more than 150 poor patients admitted in the hospital

On 7-3-2009

On 7-3-2009 we have conducted a family get together at hotel Mascot Beach Resort, Kannur. President honoured Dr. C.K. Ashokan, IPP, Kerala, Dr. P.K. Anil Kumar, IPP, North Malabar, Dr. Anil Thunoli, Hon. Secretary, Dr. Dinesh Nambiar, Editor, Dr. Ajay Nair CDH, Conv 2007-08 who had won IDA National awards last year. Branch also honoured Dr. C.V. Pradeep, the recipient of 'best clinician-academician award by IDA Kerala state on Dentists Day 2009. IDA North Malabar branch formed its **Ladies Wing** on same day. This was followed by entertainment programmes.

Family Tour Programme:-

Family tour programme was conducted on 23rd and 24th May 2009. The families were taken to a Resort in Kalpatta, Wayanad. We have arranged a Banquet on 23rd night. On 24th we visited Pookuttu Lake. We have also arranged Boat journey for family.

IDA KOCHI BRANCH

IDA Kochi: Be it the hot summer days or a heavy monsoon shower, IDA Kochi was indeed rocking with a whole lot of programs. In addition to the executive committee meeting, class on practice management, monthly meeting, free dental clinic, state CDE wing recognized CDE program on All Ceramics at Dentcare lab, we had an innovative program on the World No Tobacco Day, with a road-march flagged off by Justice Narayana Kurup and had a host of activities at Oberon mall ranging from smile contest, painting competition, non stop talk on anti tobacco, myths and facts in dentistry, games and entertainment. Glamour, Style and publicity was never compromised in this Indian Dental Association program with Surya TV, Club FM and seven newspaper along with AIR reporting on the program.

Though the month of May accounted for a large number of programs, we never hibernated. June was one step ahead. We had Executive committee meeting, Staff Training Program, Hepatitis B Vaccination Program, State CDE wing recognized CDE Program on Basic Life Support Course, IDA Kochi Library Inauguration, Monthly Meeting, Scientific Talk by Dr. George Jacob, IDA Kochi Dental Service Rates Charts, IDA Kochi Website updating, Free Dental Clinic, Branch Activity report for the month of May being released, GCDS building construction-structural drawing being made, BIDA being sent to all the members, Principal Office Bearers Meet, IDA Kochi news bulletin to members, IDA Kochi activities being updated on IDA Kerala State webpage, Membership and Address List finalized, June Branch Activity Report to Office bearers etc. Secretary's office

was indeed busy.

Visits by State Dignitaries – IDA Kerala State President-Dr. K.N. Pratap Kumar for inauguration of the CDE program on BLS course and IDA Kochi Library, and State CDH Convener Dr. Anil G for the Hepatitis B Vaccination Programme and Staff Training Program were highlights and occasions for IDA Kochi members to honor, appreciate and thank these State dignitaries.

IDA Kochi will host the State Dental Doctors Sports meet, State CDE & CDH conveners meet and State CDE program on Oral Cancer on the 9th of August 2009 at D.D. Retreat, Thammanam. We welcome all the members of IDA for this grand program.



IDA KODUNGALLUR BRANCH

Ist STATE EXECUTIVE MEETING on 1st February, 2009 at Hotel Grand, Vallanchery was attended by Dr. Cyril, Dr. Tennison Chacko, Dr. Shahab Mohammed and Dr. Pradeeksh

IInd GENERAL BODY MEETING: It was held at IMA Hall, Kodungallur on 20.02.09. Activities for Dentist Day Celebration were worked out.

CDH PROGRAMME: A dental health camp was conducted at S.N. Vidya Bhavan Senior Secondary School, Chentrapinny on 19th and 20th February. Oral health check-up was conducted by a team of 10 of our members. More than 1000 students were examined during the two day camp.

Ist BRANCH CDE PROGRAMME: The first branch CDE Programme was conducted at I.M.A. Hall, Kodungallur on 20.2.09. The speaker Dr. Sunil Mohammed (M.D.S. Pedo) enlightened the audience on 'Pulp Therapy in Paediatric Patients'.

IInd BRANCH CDE PROGRAMME: The Second CDE Programme was a one day trip to the Dentcare Dental Lab, Muvattupuzha on the 8th March 2009. There was an interesting talk on 'Metal free Ceramics' by Dr. Eldho Koshi, Prosthodontist, Calicut Dental College. There was a demonstration on crown cutting, impression techniques and cementation. Other members visited the Dentcare Dental Lab.

IIIrd BRANCH CDE PROGRAMME: The Class was conducted at Hotel Chand V, Moonupeedika. The faculty was Dr. Anish Babu who gave a lecture on 'Complete Trainer System.'

IIIrd GENERAL BODY MEETING: It was held at Hotel Chand V, Moonupeedika on 19.03.09 and was well attended

by our members.

DENTIST DAY CELEBRATION: Our Senior Member, Dr. Tony Augustine was honoured at the Dentist Day celebration. Our President, Dr. Shahab Mohammed attended the State Level Dentist Day Celebration at Mavelikkara and received the 'Most Promising Dentist Award' from the State.

'Oral hygiene awareness' leaflets were distributed to primary school students of 2 nearby schools.

IInd EXECUTIVE MEETING: Held on Hotel Kallada, Kodungallur on 27 March 2009

SRADDHA: It was decided to vaccinate our branch members for hepatitis B.

GROUP INSURANCE PROGRAMME: It was decided to take a group insurance against accidents for all members.

CDH PROGRAMME: The next CDH camp is to be conducted in association with Y'smen's Club, Mala on 19/04/2009



IDA PALAKKAD BRANCH

The 3rd CDE was held on the 10th of May at Palakkad. Dr. Sharafuddin gave us a wonderful talk on the topic "Oral white lesions and Ulcers".

On 31st May we celebrated "Anti Tobacco day". Most of the members had a strong opinion that such harmful materials should be done away with in the society. Smoking, tobacco chewing, alcohol, etc are commonly used not only by the lower income group but also by the middle and upper income ones. The meeting concluded with a talk on "Oral cancers" by Maj Gen. Dr. P. Subhash (VSM), Oncologist.

Our forth coming events are State executive meeting, Family Tour, and more CDE's.

Dr. Noorulameen would be representing our branch in the sports meet to be hold at Ernakulam in August 2009.



IDA MALANADU BRANCH

CDE PROGRAM

The CDE Program of IDA Malanadu Branch was on 30/06/09, Tuesday at Amritha Hotel Mekkadambu. After the silent prayer Dr. Jayan Jacob Mathew welcomed all. Secretary Dr. Jaymon K. Alias presented the reports and was duly passed. In his Presidential address Dr. Jose Paul mentioned about the Dental Doctors Sports Meet and about the needs of Orthodontics class for the General Practitioners. Dr. Byju Paul Kurian introduced the Faculty. Dr.P.S. Dinesh took a detailed class and discussions about the Basic Guidelines in Orthodontics for the general practitioners. After the discussion Dr. Arun Babu Proposed the vote of thanks. Then the meeting is adjourned for fellowship and Dinner. 51 members attended the seminar. The CDE Program is fully sponsored by Colgate Palmolive India Ltd.

CDE PROGRAM :

IDA Malanadu Branch CDE Program was on May 10th, Sunday 9.30 am at Mar Baselios Dental College, Kothamangalam. After the prayer song Dr. Giju George welcomed all. In his Presidential address Dr. Jose Paul mentioned about the care to be taken during the Oral Surgical Procedures. Dr. Varghese Mani took a detailed class and discussions about the minor oral surgical procedure. Dr. Sankar Vinod took a class about the impaction procedures. After the discussion there was video presentation and hands on workshop also. Secretary Dr. Jaymon K. Alias proposed the vote of thanks. Then the seminar is adjourned for food. 46 members attended the seminar. The program is fully Sponsored by Colgate Palmolive India Ltd.

DENTAL CAMP & SEMINAR:

IDA Malanadu Branch in association with Deepika Children's leage Junior wing Kottayam Region conducted a dental camp and seminar during their individual development seminar on May 12th Tuesday. The Seminar was at Nirmala Public School Pizhaku - Pala. Dr. Benny Augustine took the class and distributed toothpaste for the participants. 180 students participated in the camp.

FREE COMPLETE DENTURE DELIVERY PROGRAM :

IDA Malanadu Branch Free Complete Denture Delivery Program was on May 17th Sunday 11.00 am at Urban Bank Auditorium, Muvattupuzha. After the silent prayer song Dr. Marilyn Alias

welcomed all. In his Presidential address Dr. Jose Paul thanked the doctors for their support for the program. Muvattupuzha Municipal Chairperson Smt. Mary George Thottam inaugurated the program by delivering the first denture. IDA Kerala State President Dr. Pratap Kumar and State Secretary Dr. Antony Thomas felicitated for the program. Branch Secretary Dr. Jaymon K. Alias proposed the vote of thanks. 100 complete Dentures were delivered during the program freely. The denture delivered patients their relatives and doctors also present during the function.

INTER BRANCH FAMILY TOUR

IDA Malanadu Branch in Association with IDA Nedumbassery Branch Conducted an Inter Branch Family Tour to Silver Storm Water Theme Park Athirappilly on May 17th Sunday. IDA Kerala State President Dr. Pratap Kumar, State Secretary Dr. Antony Thomas, State President Elect Dr. Samuel K. Ninan, State first vice President Dr. Jaibin George, Both Branch members and their family members also attended the Tour program. All of them enjoyed all the rides in the water theme park with their families. After the Rain Dance and Ganamela the program is adjourned for fellowship and dinner. All together 115 participants for the combined family Tour Program.



IDA WAYANAD BRANCH

06.03.2009: Free dental check up was organised at WMO School Muttill. 600 students were examined and oral hygiene classes were taken by Dr. Poji Menacherry, Dr. Renjith C.K, Dr. Bijoy Oommen, Dr. George Abraham, Dr. Noushad and Dr. Shanavas.

26.04.2009 : 2nd Executive meeting held at Kannur. President Dr. Damodaran, Secretary Dr. Sajith P.C, Dr. Poji Menacherry and Dr. Renjith C.K attended the meeting.

03.05.2009 : Free denture programme distributed 58 complete dentures to poor patients. All the members whole heartily participated and many of the members conducted by doing 2 dentures. TPV Surendran, State Secretary, QPMPA was the chief guest. State CDH Chairman Dr. Anil H was guest of honour. Organised 22 members with family participated.

07.07.2009 ; 4th executive meeting held at Hotel Resort Sulthan Bathery. Hepatitis vaccination given to all members, family and clinic assistants. 200 vaccines were distributed.

17.05.2009 : CDE Programme on emergencies in dental offices taken by Dr. Adarsh.S.Indra, Asst. Professor Coorgh Institute of Dental Sciences, Virajpetta. 25 members were present.

31.05.2009 ; **No Tobacco Day**

A poster design was petition for school children conducted

the topic given was ill effects of tobacco. The posters were displayed at Bus stands at Mananthavady, Sulthan Bathery and Kalpetta. Cash prizes were given to the winners of the contest.

06.06.2009 ; Third executive meeting held at IMA Hall at Mananthavady discussed about Hepatitis vaccination, sports Day, ACDEP Programmes. All the executive members was present.

28.06.2009 ; Wydent sports day was conducted. Indoor games competition in thutter Budni, Table Tennis, Caroms, Chess and a variety of party games conducted.

**IDA PATHANAMTHITTA BRANCH**

Two **EXECUTIVE COMMITTEE MEETINGS** were held on 07/05/2009 and 24/06/2009 at Govt. Guest House Pathanamthitta & Jaycee Hall, Omalloor. The second executive has hosted by Dr. Sujith PR.

CDE REPORTS: Two CDEs were conducted. First CDE on the topic "**STERILIZATION PROTOCOL & CHAIR SIDE ASSISTANCE**" by Dr. Muraleekrishnan M was held Govt Guest House, Pathanamthitta on 10/05/2009 which was attended by 34 members. Second CDE on "**BIO-FUNCTIONAL PROSTHETIC SYSTEM**" by Dr. Abby Abraham was held at Dent Care Dental Lab; Muvathupuzha on 07/06/2009 which was attended by 30 members. Other than CDEs; the branch conducted **STAFF TRAINING PROGRAMME** at Govt Guest House, Pathanamthitta on 10/05/2009 consisting of a class in **FRONT OFFICE MANAGEMENT** taken by renowned Jaycee trainer Mr. Lal Varghese & **DENTAL MATERIALS MANAGEMENT** by members of 3M group.

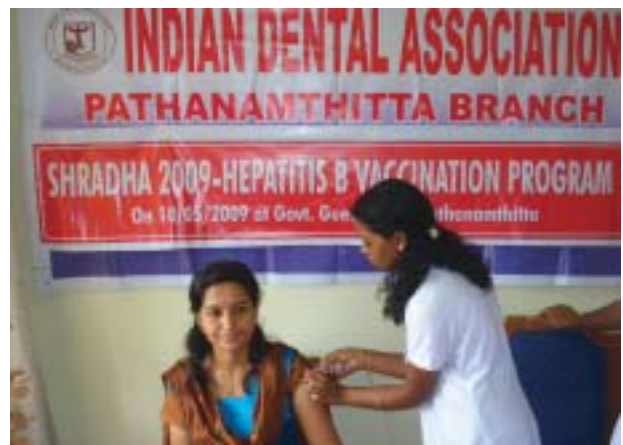CDH REPORTS: SHRADHA 2009: As part of the Hepatitis B Immunization programme of IDA Kerala State, the branch made arrangements for the immunization of its members and staff on 10/05/2009 at Govt Guest House, Pathanamthitta and also decided to have members get the second dose at the clinic of Dr. Thomas Varghese on 10/06/2009. **ORPHANAGE ADOPTION PROGRAMME** was done at Diyva Karunya Ashram, Ranny coordinated by Dr. Jacob Korah and attended by the Dr. Thomas Varghese & Dr. Gigu Zakariah Philip on 31/05/2009. Treatments & donations were given to the inmates of the Ashram. **DENTAL AWARENESS CAMP** was taken for students of Govt. UP School, Panaially PO, Omalloor on 19/06/2009, attended by Dr. Gigu Zakariah Philip, Dr. Sujith PR & Dr. Rajesh V wherein Dr. Rajesh V took the Awareness class for the students and the dental check up was done by Dr. Gigu Zakariah Philip & Dr. Sujith PR. This programme was done in coordination with the JCI Omalloor. Note books & pencils were distributed to the students of the school. **ANTI TOBACCO AWARENESS PROGRAMME** was

conducted at St. George High School, Eravalloor, near Konny on 30/06/2009 under the coordination of Dr. Rajesh V, coordinator of Kaniyu 2009. A seminar on the ill effects of using tobacco in its different forms was taken. Film exhibition based on this year's WHO theme was done for the students by Dr. Johnykutty Jacob. After the class the students made a collective pledge not to use any form of addictive substances in any form either as gutka, Pan Masala etc.

FIRST EDITION OF BRANCH JOURNAL-XTRACT 2009 was released by state president Dr. KN Prathap Kumar during the 3rd State Executive on 24/04/2009.

President & members of our branch attended the funeral service of Dr. Radha CP who expired on 14/04/2009

ATTENDING STATE PROGRAMMES: President Dr. Thomas Varghese, Dr. Gigu Zakariah Philip, Dr. Jacob Korah, Dr. Rajesh V, Dr. Johnykutty Jacob & Dr. Ralu Varghese had attended the 3rd State Executive Committee Meeting.



IDA NEDUMBASSERY BRANCH

Activities for the period from 10th April to 10th June 2009

18th April 2009

4th Executive meeting. It was attended by 13 members

2) 03 May 2009 :

A training program for dentists and also for the auxiliaries was held at Dentcare Dental Lab Muvatupuzha

3) 17th May 2009:

A combined family get together and picnic by IDA Nedumbassery and IDA Malanad was held at Silver Storm Water theme park, Athirampilly. It was also attended by the state president, Dr K N Pratap Kumar, Hon. state Sec Dr Antony Thomas and President Elect Dr Samuel K Ninan.

4) CDH Activities: Screening camps were held at our adopted projects and treatment required was carried out at the respective dental clinics.

5) Summer camp 18th May to 21st May

The ladies wing of IDA Nedumbassery (Queensland) along with MASTHI conducted 4 day camp for the children. It was attended by around 35 kids.

6) June 6th 2009: The 5th Exe meeting of IDA Nedumbassery was held on 6th June 2009. It was attended by 12 members.

7) State Executive meeting: 6 of our members attended the state executive meeting held at Thalassery.



IDA CENTRAL KERALA BRANCH

3rd Executive Committee Meeting

3rd executive committee meeting was held on 26th March at Kottayam Club at 7.30 pm. Meeting was well attended.th

Dental Check up Camp

A dental check up camp was conducted along with the rotary club of Eratupetta in the rotary hall on 5th April

Dental Treatment Camp

A free dental treatment camp was conducted along with the rotary club of Eratupetta in the rotary hall on 5th April. 52 patients were given free treatment.

Dental Awareness Class

A dental awareness class was taken for the public at the rotary hall of Rotary club of Eratupetta on 5th April.

3rd Family Get together

3rd family get together was held on 19th April at Backwater Resorts Kumarakom. It was a well attended function. Members used the swimming pool. Games and competition was held for children.

Dental Awareness Camp

A dental awareness class was conducted along with St Gregorious Dental College at the tribal colony at Chinnaparakydy on 26th April.

Oral Cancer Detection Camp

Oral cancer detection camp was conducted along with St Gregorious Dental College at the tribal colony at Chinnaparakydy on 26th April.

Dental Checkup Camp

A Free dental check up camp was held on 25th April along with Lions club of Eratupetta Central.

Dental Treatment Camp

A free dental treatment camp was held on 25th April along with Lions club of Eratupetta Central. 78 patients were given free treatment.

Dental Awareness Class

A dental awareness class was taken for the public on 25th April along with Lions club of Eratupetta.



IDA TRIVANDRUM BRANCH**Phoenix MDS entrance coaching programme**

Indian Dental Association Trivandrum branch in association with **Oral Care foundation** has started an unique programme for the MDS aspirants **Phoenix MDS entrance coaching programme**. The inauguration of the programme was conducted at IDA Hall, Trivandrum on May 1st 2009. President IDA Trivandrum branch did the inauguration by lighting of the lamp. Dr M P Vinoth spoke on the occasion. Cash award was given to Dr Varun, student of last year coaching programme for securing 2nd rank in Kerala MDS entrance exam.

The programme includes lectures as well as model test and post test exams which is conducted under guidance of eminent faculties. All subjects are covered and in depth discussion of theory and MCQs are done in the class. The classes are conducted at IDA Hall, Trivandrum on every Sunday, Second Saturday and public holidays. The timing of the class is from 9.30-5 pm.

2nd Inter Dental College Cricket Tournament

The Second Inter Dental College Cricket Tournament Hosted by the IDA Trivandrum Branch involving colleges in and around Trivandrum was held on the 13th and 14th of June 2009 at Chandrashekar Nair Stadium, Trivandrum.

Teams from PMS Dental College, Noorul Islam Dental College, Rajas Dental College, Azezzia Dental College, Sri Mookambhika Dental College and Sri Sankara Dental College participated.

In the finals, the defending champions Rajas Dental College defeated Sri Sankara Dental College to retain the championship.

**IDA TIRUVALLA BRANCH****Installation of IDA Thiruvalla Branch for the year 2008-2009**

Installation Ceremony of newly formed IDA Thiruvalla Branch was held at Contour Resort Convention centre, Changanacherry on 7/12/2008 at 7 pm. The meeting was honored by the presence of the chief guest Hon. Minister Adv. Mathew T. Thomas. Dr K.N Pratap Kumar President Kerala State IDA, Dr Antony Thomas Hon. Secretary of Kerala State IDA were among the dignitaries. Mr. Jacob Vanchipalam Municipal Chairman Thiruvalla released our souvenir after the installation ceremony. Dr K.N Pratap Kumar installed the President Dr. Thomas Eapen. Dr. Samuel K. Ninan President Elect IDA Kerala State felicitated the new team. Dr Binoy Mathews N. Hon Secretary of IDA Thiruvalla proposed the vote of thanks. The meeting was followed by cultural programs by the student members of IDA Thiruvalla Branch, fellowship & dinner.

First Executive Meeting

The first executive meeting of IDA Thiruvalla Branch was held on 12/12/2008 at Travancore Club Thiruvalla.

Family Get Together

The first family get together after the installation of IDA Thiruvalla Branch was conducted at Travancore Club Auditorium Thiruvalla on 17/01/2009 followed by various activities by our members, games for children, fellowship and dinner. 48 members attended the function.

Second Executive Meeting

Second Executive Meeting was held on 17/02/2009 at Travancore club Thiruvalla.

First CDE Program

First CDE Program was conducted on 29/03/2009. Our First CDE Program was inaugurated by Dr Shaji K Jose (Dental Council Of India Member) at Hotel Dynasty Thiruvalla - The topic was "PREP" - An Interdisciplinary Approach.

by a team of 3 faculties from Coorg Institute Of Dental Sciences Dr. P.L Rupesh Dr. M.A. Kuttappa Dr. M. Anil 52 Members attended the program.





Kerala Dental Journal

INFORMATION FOR AUTHORS

All correspondence may please be sent to the following address :
 Dr. K. Nandakumar, Hony. Editor, Kerala Dental Journal,
 Neelambikam, Attukal, Manacaud, Trivandrum - 695 009
 Tel: 0471-2459235 / Cell: 09447066100 / e-mail: editorkdj@gmail.com

GUIDELINES

Manuscripts: Articles should be type written on one side of A4 size (21x28cm) White paper in double spacing with a sufficient margin. One Original and two high quality xerox copies should be submitted. The author's name is to be written only on the original copy and not on the two xerox copies. **In addition to the printed version, a CD containing the article file also should be submitted compulsorily.** Use a clear and concise reporting style. KDJ reserves the right to edit, manuscript, to accommodate space and style requirements. Authors are advised to retain a copy for the reference.

Title Page: Title page should include the title of the article and the name, degrees, positions, professional affiliations of each author. The corresponding authors, telephone, e-mail address, fax and complete mailing address must be given.

Abstract: An abstract of the article not exceeding 200 words should be included with abbreviated title for the page head use. Abstract should state the purpose of the study, investigations, basic procedures and the main findings.

Tables: Tables should be self explanatory, numbered in roman numbers, according to the order in the text and type on separate sheets of paper like legends for illustrations.

Illustrations: Illustrations should be clearly numbered and legends should be typed on a separate sheet of paper, while each figure should be referred to the text. Good black and white glossy photographs or drawings drawn in black Indian ink on drawing paper should be provided. **Colour photographs will be published as per availability of funds. It will incur printing cost. Otherwise the cost of printing will be at the expense of authors and charges will be advanced by KDJ at the time of receipt of accepted manuscripts.** Photographs of X-rays should be sent and not the original X-rays. Prints should be clear and glossy. On the back of each print in the upper right corner, write lightly the figure number and author's name;

indicate top of the photograph with an arrow of word 'Top'. Slides and X-ray photographs should be identified similarly.

Reference: Reference should be selective and keyed in numerical order to the text in Vancouver Style (not alphabetical). Type them double spaced on a separate sheet of paper. Journal references must include author's names, article title, journal name, volume number, page number and year. Book reference must include author's or editor's names, chapter title, book title, edition number, publisher, year and page numbers.

Copy right: Submission of manuscripts implied that the work described has and not been published before (except in the form of an abstract or as part of published lectures, review or thesis) and it is not under consideration for publication elsewhere, and if accepted, it will not be published elsewhere in the same form, in either the same or another language without the comment of copyright holders. The copyright covers the exclusive rights of reproduction and distribution, photographic reprints, video cassettes and such other similar things. The views/opinions expressed by the authors are their own. The journal bears no responsibility what so ever.

The editors and publishers can accept no legal responsibility for any errors, omissions or opinions expressed by authors. The publisher makes no warranty, for expression implied with respect to the material contained therein. The journal is edited and published under the directions of the editorial board who reserve the right to reject any material without giving explanations. All communications should be addressed to the Editor. No responsibility will be taken for undelivered issues due to circumstances beyond the control of the publishers.

Books for review: Books and monographs will be reviewed based on their relevance to KDJ readers. Books should be sent to the Editor and will become property of KDJ.

Return of articles: Unaccepted articles will be returned to the authors only if sufficient postage is enclosed with the manuscripts.



Kerala Dental Journal

INDIAN DENTAL ASSOCIATION, KERALA STATE BRANCH



KDJ

SUBSCRIPTION FORM

To get copies of Kerala Dental Journal (KDJ), annual subscription fee:

**Subscription Rates: Free distribution for all the members of the Indian Dental Association Kerala State
 Rs. 500 per issue, Rs. 2000 for 1 Year (4 issues), Rs. 3500 for 2 years (8 issues),
 Rs. 5000 for 3 years (12 issues).**

Name

Address

Place: District:

State: Pin Code:

Tel. No. E-mail:

Kindly find here with enclosed cheque / Demand Draft No..... dated:.....
 of..... Bank for Rs..... in favour of **Kerala Dental Journal** payable at **Trivandrum**
 (please write above particulars behind the Cheque/D.D.)

All correspondence may please be sent to the following address :
Dr. K. Nandakumar, Hony. Editor, Kerala Dental Journal Neelambikam, Attukal, Manacaud, Trivandrum, Kerala - 695 009
 Phone: 0471-2459235 / Cell: 09447066100 / e-mail: editorkdj@gmail.com

LIST OF DENTAL COLLEGES IN KERALA

1. Govt. Dental College, (Trivandrum) Medical Campus, Trivandrum – 695 011. 0471-2444092
2. Govt. Dental College, (Calicut) Medical College Campus, Kozhikode – 8 0495-2356781
3. Govt. Dental College, (Kottayam) Gandhinagar, Kottayam – 686008 0481-2594046
4. Al-Azhar Dental College, Perumbillichira P.O., Thodupuzha, Idukki, Distt. Kerala – 685605 04862-224366
5. Annoor Dental College, Perumattom P.O., Muvattupuzha, Dist. Ernakulam 0485-2815217, 2815917
6. Azeezia College of Dental Sciences & Research,
Diamond Hills, Meeyyannoor, P.O., Kollam - 691 537 0474-3069353
7. Century International Institute of Dental Science & Research Center
Poinachi, P.O. Thekkil, (VIA), Chengala, Kasaragod – 671541 0467-2237600/200
8. Educare Institute of Dental Sciences, 15/272, Downhill,
Tirur Road, Malappuram – 676519 0483-2708353, 2705602, 2705603
9. Indira Gandhi Institute of Dental Sciences, Nellikuzhy P.O., Kothamangalam – 686691 0485-6451630, 6451631
10. Kannur Dental College, Anjarakandi, Mamba P.O. Kannur 0497-2855010, 2855000-1-2 Extn. 3000, 3002
11. KMCT Dental College, Calicut, Mampetta, Manassery P.O., Calicut 0495-2290690, 2290693
12. Malabar Dental College & Research Centre, Edappal, Malappuram 0494-2697020, 2697021, 2697022
13. Mar Baselios Dental College, Thankalam, Kothamangalam, Ernakulam – 686691 0485-2823985, 2823740
14. MES Dental College & Research Centre, Perinthalamanna, Malappuram, 04933-258400
15. Noorul Islam College of Dental Sciences, Aralumoodu, Trivandrum 0471-2223542, 2226513
16. Pariyaram Dental College, Academy of Medical Sciences, Pariyaram - 670503, Kannur 0497-2808127
17. PMS College of Dental Science & Research, Vatappara, Thiruvananthapuram – 695 028 0472-2587878
18. PSM College of Dental Sciences & Research, Palikkattil Building, Akkikavu, Trichur 0488-5289991
19. Royal Dental College, Iron Hills, Chalissery P.O., Palakkad, Kerala - 679 536 0466-2255131, 132, 133
20. Sri Sankara Dental College, Akathumuri, Varkala, Thiruvananthapuram 0470-3207085, 3206245, 2795016
21. St. Gregories Dental College, Chelad, Kothamangalam, Ernakulam 0485-2572529, 530, 531
22. Amrita Inst. of Medical Sciences & Research Centre,
Kunnumpuram, Edappalli North, Cochin – 24 0484-280 2020 / 2051
23. Pushpagiri College of Dental Sciences, Medicity, Thiruvalla 0469-2645210, 2645282



With best Compliments from

Dent need
Dealers of Dental Materials and Equipments

T.C. 1/2142 (3), IInd Floor, Kunnath Plaza,
Murinjapalam, Thiruvananthapuram - 11
Ph: (Off) 0471 3293998, 6455064. (Res) 0471-2326744
Mob: 98471 42981, 98462 21222
E-mail: dentneed2001@hotmail.com

Channel Partner of      